

1-1-1966

A comparative morphologic study of the cardiac innervation of domestic animals.

John S. McKibben
Iowa State University

Follow this and additional works at: <https://lib.dr.iastate.edu/rtd>



Part of the [Veterinary Anatomy Commons](#)

Recommended Citation

McKibben, John S., "A comparative morphologic study of the cardiac innervation of domestic animals." (1966). *Retrospective Theses and Dissertations*. 18502.

<https://lib.dr.iastate.edu/rtd/18502>

This Thesis is brought to you for free and open access by the Iowa State University Capstones, Theses and Dissertations at Iowa State University Digital Repository. It has been accepted for inclusion in Retrospective Theses and Dissertations by an authorized administrator of Iowa State University Digital Repository. For more information, please contact digirep@iastate.edu.

SF761
M21C
C.2

A COMPARATIVE MORPHOLOGIC STUDY OF THE
CARDIAC INNERVATION OF DOMESTIC ANIMALS

by

John Scott McKibben

A Thesis Submitted to the
Graduate Faculty in Partial Fulfillment of
The Requirements for the Degree of
MASTER OF SCIENCE

Major Subject: Veterinary Anatomy

Signatures have been redacted for privacy

Iowa State University
Of Science and Technology
Ames, Iowa

1966

1486464

1126-5

TABLE OF CONTENTS

	Page
· INTRODUCTION	1
REVIEW OF THE LITERATURE	7
MATERIALS AND METHODS	42
RESULTS	44
PART I. EQUINE	45
PART II. BOVINE	65
PART III. OVINE	80
PART IV. CAPRINE	95
PART V. PORCINE	110
PART VI. FELINE	126
PART VII. CANINE	141
DISCUSSION	156
SUMMARY AND CONCLUSIONS	185
BIBLIOGRAPHY	189
ACKNOWLEDGMENT	206
CUMULATIVE KEY TO THE FIGURES	207
APPENDIX A: TABLES	209
APPENDIX B: PHOTOGRAPHS OF SPECIMENS	218
APPENDIX C: ILLUSTRATIONS	246

INTRODUCTION

The purpose of this study was to morphologically document and compare the origins, courses, and distributions of the extrinsic cardiac nerves in domestic animals. This additionally entailed a re-evaluation of the previous heterogeneously applied nomenclature and the formulation of a more useful classification. This was based on the recommended nomenclature of the *Nomina anatomica* (1956 and 1961) and the suggestions of Schreiber, Frewein, and Walter (1963) to the International Commission for Veterinary Anatomical Nomenclature.

The continued elevation of interest in physiologic and pathologic cardiology has increased the demand for further anatomical knowledge of the heart. The morphologic knowledge of the cardiac innervation is a necessity for the understanding of the functions of the heart and other directly or indirectly related organs of the body. In addition to the human implications, it is hoped that this study will also benefit both animal research and clinical veterinary medicine.

The innervation of the human heart is well documented. Much experimental cardiology, however, has been carried out with other animals. Traditionally the dog has been used for many of these studies, but other species may make better subjects. To apply knowledge gained from these experimental animals to the human, basic anatomical differences should be

accounted for. This study; therefore, was concerned with augmenting the already well described accounts on the dog, with descriptions and comparisons of the cardiac innervation of the equine, bovine, ovine, caprine, porcine, and feline.

Though the total significance of the neural and hormonal effects upon the heart have not been recognized, most people have been aware of some of the consequences which result from interference with their function. Clinical evaluation of the cardiac conduction system is no longer restricted to humans. A better anatomical understanding of this area will benefit the clinician in interpreting his physiologic findings. This will facilitate both preventive medicine and treatment, particularly in gerontologic patients.

Considerable strides have been made towards meeting these needs by investigating and documenting the intrinsic cardiac innervation. Much less has been accomplished towards this end in the area of extrinsic cardiac nerves. In the veterinary anatomical textbooks, only Stromberg (1964) has reported on the extrinsic cardiac nerves in any detail. Other texts include inadequate descriptions since little work has been done in this area on other domestic species. The nomenclature has not been standardized between texts, resulting in considerable confusion for the readers.

To avoid further confusion this investigator has chosen to describe the ganglia of origin for the cardiac nerves as explained by Wrete (1959). Since he was one of three members

of the subcommittee responsible for the nomenclature of this area for the Nomina Anatomica (1956), it was felt that his authoritative interpretations would be quite helpful. The proposed nomenclature by Schreiber, Frewein and Walter (1963) for the Nomina Anatomica Veterinaria also included all the ganglia considered by Wrete (1959).

Specific cardiac nerves have been related to their ganglion or nerve of origin, as others have done in the human. However, differences in the number and origin of cardiac nerves has necessitated additional and more specific nomenclature than that used for humans. Because the origins and courses of the cardiac nerves were found to be similar within each species, subclassification of these nerves was based upon the positional segment of the ganglion or nerve of origin.

Prior to considering the results or literature review a short outline of the ganglia of origin for cardiac nerves will be discussed. Further details will be found later, however, it is hoped that the following introduction into this area will expedite further reading.

Thoracic Ganglia (Ganglia thoracica)

Thoracic ganglia were found as independent ganglia in each of the intercostal spaces from the second, third, or fourth space caudally along the sympathetic trunk. Individually they were numbered according to the rib just cranial

to each. Rami communicantes passed to respective thoracic spinal nerves at each space. In addition, the thoracic viscera, including the heart, vessels, esophagus, and respiratory tract, received sympathetic innervation from these ganglia.

Cervicothoracic Ganglion (Ganglion cervicothoracicum)

This ganglion, in all animals investigated, was composed of the caudal cervical ganglion and first one to four thoracic ganglia. It was located on the lateral surface of the longus colli muscle extending, depending on the species, from just cranial to the first rib to the fourth rib, caudally. Rami communicantes extended caudally to at least the fourth thoracic spinal nerve and cranially by the vertebral nerve as far as the second cervical spinal nerve. Cervicothoracic splanchnic nerves in the thorax passed to the heart, vessels, esophagus, respiratory tract, pericardium, lymph nodes, thymus, and to the diaphragm by a communication with the phrenic nerve.

Intermediate Ganglia (Ganglia intermedia)

This designation was reserved for inconsistent ganglia situation in the internodal rami, on communicating rami, or in the main trunks or roots of the spinal nerves. Occasionally they were large enough to emit splanchnic branches to the thoracic organs.

Vertebral Ganglion (Ganglion vertebrale)

Craniomedial to the vertebral artery the two limbs of the ansa subclavia joined this ganglion. Although, generally, separate rami communicantes were not present, they may be found occasionally to the sixth cervical spinal nerve. Others may reach the cervical spinal nerves through the phrenic nerve with which it may communicate. Besides vascular twigs in the immediate area, nerves may pass from this ganglion to the heart, great vessels, respiratory tract, pericardium, lymph nodes, and thymus.

Middle Cervical Ganglion (Ganglion cervicale medium)

An independent ganglion, meeting the requirements established by Wrete (1959) was not observed in the majority of species. When present it lay cranial to the vertebral ganglion on the sympathetic trunk at about the level of the sixth cervical vertebra. Vascular twigs in the immediate area and to the heart and great vessels were noted.

Cranial Cervical Ganglion (Ganglion cervicale craniale)

Located ventromedial to the tympanic bulla, this ganglion may send nerves caudally, but none were found extending to the heart in the domestic animals studied. Other nerves from this ganglion followed the arteries to the cranial region. Some may also pass to the first two or more cervical spinal nerves.

For anatomical reasons based on areas supplied and to facilitate description, the vagus nerves were divided into two segments. That segment cranial to the origin of the recurrent laryngeal nerve was considered to be the cranial portion, and the remaining segment, the caudal portion. Cardiac nerves arising from each segment retained this designation, cranial or caudal. As previously described, names for cardiac nerves arising from specific ganglia were based on their origin.

The cardiac plexus was often a destination for cardiac nerve branches. Although it commonly has been divided into several areas it has been found that these areas are artificial divisions. The plexus was composed of both sympathetic and parasympathetic fibers interwoven primarily in the area ventral to the bifurcation of the trachea, caudal and lateral to the arch of the aorta, and around the branches of the pulmonary artery at its bifurcation, though primarily cranial and dorsal. From this area intertwined nerves extended to both the heart and lung.

With this brief explanation it is hoped that the reader will more easily assimilate the material presented in this complex area.

REVIEW OF THE LITERATURE

Through a review of the literature, an appreciation of the intense interest in cardiology over the centuries is readily gained. The evolutionary progress toward the anatomical and physiological characterization of the cardiac nerves in man and animals has been rapid. Though pioneered in the human much earlier, considerable strides in characterizing these nerves in animals occurred after the middle of the twentieth century. These investigations have been centered around the morphological, pathological, and physiological studies on the dog.

To formulate as complete a study as possible this investigator felt it was necessary to review not only the literature directly related to the cardiac innervation of domestic animals, but to preclude this with the basic human investigations upon which many of the former were based. A lag between original research and textbook descriptions was readily recognized. The number of texts, the inconsistency of descriptions, and the complexity of the area have not permitted consideration of all these detailed differences in this review. Where possible additional comparisons will be incorporated in the discussion.

Hippocrates of Cos (340 B.C.) was perhaps the first to dissect and record anatomical information relative to the heart and Galen (131 - 200 A.D.) the first to write about

involuntary nerves. However, according to Luisada (1954) modern cardiology began around 1500 A.D. with the works of Andreas Vesalius who Kemper (1905) calls the "Father of Anatomy". In 1543 Vesalius wrote the "Seven Books on the Structure of the Human Body" in which he dealt with the innervation of the heart. Another author of this century Gabriello Fallopius, an Italian anatomist, recorded his "Observations Anatomicae" in 1561. He was credited by Walmsley (1929) with discovering all the cardiac nerves. Senac (1749) also credited him with first describing the cardiac plexus.

In the seventeenth century Willis (1664) first described the sympathetic trunks calling them the intercostal nerves. The loop now described as the ansa subclavia was described for the first time by a French physician, Reymond Vieussens (1685).

The eighteenth century found Winslow (1732) naming the trunks which Willis found earlier (1664), the sympathetic trunks. Two additional contributions included Neubauer's (1772) "Anatomic Description of Cardiac Nerves" and Scarpa's (1794) "Tables of the Cardiac Nerves".

Numerous investigations of the many facets of cardiac innervation ensued in the nineteenth century. Among these were: the microscopic description of cardiac ganglia for the first time by Remak (1838, 1839, 1844); the description

of modified cardiac muscle fibers credited with conductive significance by Purkinje (1845); the exhibiting of a depressor nerve by Cyon and Ludwig (1866); and the suggestion of sensory endings in the heart by Berkley (1894). Human morphologic and functional studies of cardiac innervation by Miot (1876) and Reynier (1880) were used as the basis for Paul's (1884) descriptions. During this period animal investigations of the cardiac innervation were carried out by Ludwig (1848), Bidder (1852) and Gaskell (1883) on cold blooded vertebrates. A description of the cardiac nerves of the dog appeared as early as 1871 by Schmiedeberg. Lim Boon Keng (1893) was concerned that a fairly complete account of the macroscopic anatomy of the cardiac nerves of the dog did not exist before his publication. Of common concern to the investigators of this century was the depressor nerve. This together with other heart nerves was studied in the cat by Bernhardt (1868), Boehm (1875) and Kazem-Beck (1888) and in the artiodactyla by Kreidmann (1878), Viti (1884), Kazem-Beck (1888) and Schumacher (1902).

Since the beginning of the twentieth century, a voluminous amount of literature has accumulated on the gross, light microscope, and electron microscope findings regarding the intrinsic cardiac innervation. Since complete references in this area were not within the scope of this thesis, perhaps those interested can refer to Wollard (1926), Tcheng

(1949), Hirsch (1963), Wensing (1964, 1965a, b) or Phillips (1965) for further detail in this phase. Argaud (1911a, b, c) histologically investigated the intracardiac innervation of the bovine, ovine, equine, porcine, and caprine: particularly the innervation of the thebesian valve. Boyd (1941) described the innervation of the ductus arteriosus in several mammals. Randall (1965) presented a well documented account of the functional nervous control of the heart.

In the twentieth century complete morphologic descriptions of the extrinsic cardiac nerves, except in man and the dog, are still lacking in the English literature and are sketchy in foreign sources. Perman (1924) reviewed the latter quite thoroughly.

The necessity for standardization of anatomical nomenclature was realized quite early by human anatomists. In 1895, the first *Nomina Anatomica* was formulated in Basel, Switzerland. Since that time this nomenclature has been reconsidered by the International Congress of Anatomists in Jena, Germany in 1935, in Paris, France in 1955 and in New York, New York in 1961. A comparison of the nomenclature relevant to cardiac innervation as listed by Kopsch (1957) as established at each of these meetings including additions and changes follows:

Basel (1895) B.N.A.	Jena (1935) J.N.A.	Paris (1955) P.N.A.
A. GANGLIA		
1. Ganglion cervicale inferius	Ganglion cervicale caudale	Ganglion cervicothoracicum (stellatum)
2. Ganglion cervicale medium	Ganglion cervicale medium	Ganglion cervicale medium
3. Ganglion cervicale superius	Ganglion cervicale craniale	Ganglion cervicale superius
4. - - -	var. Ganglion cervicothoracicum = Ggl. Stellare	Ganglion cervicothoracicum (stellatum)
5. - - -	- - -	Ganglion vertebrale (trunci sympathici)
6. Ganglion cardiacum (Wrisbergi)	Ganglion cardiacum	Ganglia cardiaca
7. Ganglia thoracalia	Ganglia thoracica	Ganglia thoracica
8. - - -	- - -	Ganglia intermedia (trunci sympathici)
B. NERVES		
1. N. cardiacus inferior	N. cardiacus caudalis	N. cardiacus cervicalis inferior
2. N. cardiacus medius	N. cardiacus medius	N. cardiacus cervicalis medius
3. N. cardiacus superior	N. cardiacus cranialis	N. cardiacus cervicalis superior
4. - - -	- - -	Nn. cardiacci thoracici

It should be noted that the 1961 and 1955 Nomina Anatomica nomenclature in this area was the same. Also, the World Association of Veterinary Anatomists has published the

first part of *Nomina Anatomica Veterinaria* (1963). Schreiber, Frewein and Walter (1963) representatives for the section on the autonomic nervous system have drawn up a list, similar to that for man, for approval by this Association. The designation of cranial and caudal in animals, rather than superior and inferior, was the only exception to the human nomenclature of 1955 and 1961. This change was warranted due to differences in the normal postural relationships between man and the domestic animals.

Not all investigators in the area of cardiac innervation have complied with this standardized nomenclature. Many who did, differed in their designation of a name for a particular structure. One needed only to survey descriptions of cardiac nerves and related ganglia in modern human anatomy textbooks and related periodical articles to appreciate this fact.

In man the main difficulty seemed to arise in reference to the cervical sympathetic ganglia. The ganglion immediately cranial to the subclavian artery was joined caudally with the cervicothoracic ganglion by the ansa subclavia. Just cranial to the ganglion immediately cranial to the subclavian artery, at about the level of the sixth cervical vertebra, was another independent, inconstant ganglion. Axford (1928) referred to these two ganglia as high and low middle cervical ganglia. Perman (1924), Hardesty (1933), Nonidez (1939), Luisada (1954), Netter (1962), and Truex and

Carpenter (1964) recognized only one ganglion in this area and designated this as the middle cervical ganglion. Nonidez (1936, 1937a,b) earlier referred to this as the inferior cervical ganglion. Jonnesco (1923), White and Smithwick (1952), Kuntz (1949, 1953), and Durward (1953) preferred to call the lower ganglion the intermediate ganglion and the more cranial one the middle cervical ganglion. Laubmann (1931), Mitchell (1953), Grant (1958), Wrete (1959), Gardner, Gray, and O'Rahilly (1963), and Davies and Davies (1964) used the name vertebral ganglion as the preferred designation for the lower ganglion and reserved the term middle cervical ganglion for the more cranial ganglion. Wrete (1959) suggested that this allowed the use of intermediate ganglion for ganglia which may occur along the sympathetic trunk in the internodal rami, on communicating rami, or in the main trunks or roots of the spinal nerves.

Those who recognized that two ganglia existed between the superior cervical ganglion and the cervicothoracic ganglion on each side, also realized that not infrequently the middle cervical ganglion may be fused with either the superior cervical or vertebral ganglion. Wrete (1959) called these the ganglion cervicale medio-superius and ganglion medio-vertebrale, respectively. According to Kuntz (1949, 1953) the middle cervical ganglion was often absent in man. Grant (1958) indicated that the vertebral and middle cervical ganglia were both present in about fifty

per cent of the specimens and that the former was more often present singly.

Literature concerning the human's cervicothoracic ganglion was much less complicated. According to Jamieson (1952) the caudal cervical and first thoracic ganglia were fused in eighty-two per cent of the cadavers he dissected. This fusion has resulted in a star shaped ganglion in man; hence, the less acceptable term stellate ganglion arose. Mannu (1914) designated the ganglion just cranial to the subclavian artery (vertebral ganglion) as the stellate ganglion in domestic animals. The term stellate ganglion is being, unfortunately, still perpetuated in many human and veterinary anatomy texts in reference to the cervicothoracic ganglion. Hardesty (1933) proposed the name ganglion cervicothoracale for the fused caudal cervical and first two thoracic ganglia. A modification of this name has gained favorable acceptance by the *Nomina anatomica* (1961).

The cardiac nerves in man have quite consistently been considered as the superior, middle, and inferior cardiac nerves from the cervical ganglia, and thoracic cardiac nerves from the thoracic ganglia. Mizeres (1963) however, thought these should be changed. He proposed the name cervical cardiac branches of the sympathetic trunk to replace the superior and middle cervical cardiac nerves. The term "cervicothoracic cardiac branches of the sympathetic

trunk" was preferred over "inferior cervical cardiac nerve". In addition, he divided the vagal cardiac branches into cervical, cervicothoracic, and thoracic cardiac branches. He noted the omission in the 1961 Nomina anatomica of reference to branches of the vagus which passed to the heart from within the thorax. Also, cardiac nerves arising from the sympathetic trunk were called nerves while those from the vagus were referred to as branches. He preferred the designation of cardiac branches instead of cardiac nerves in referring to all nerves leading to the heart.

It was of interest to note that the right middle and inferior sympathetic cardiac nerves according to Allan (1958) followed vessels to reach the heart. He noted that in the presence of an anomalous right subclavian artery these nerves followed the artery through its aberrant course before supplying the heart. The course of the vagal nerves was not affected.

With this background it required little imagination to visualize what ensued when Veterinary anatomists attempted to parallel the varied human nomenclature for the cardiac nerves and related ganglia of domestic animals. To facilitate the comprehension of the following accounts from previous authors, the more acceptable nomenclature, as outlined in the introduction, will follow each ganglion referred to in this text.

The horse traditionally served as the basic animal for

veterinary anatomical dissections during the late nineteenth and early twentieth centuries. However, little detailed information could be found regarding the cardiac innervation in this species. Montané and Bourdelle (1913, 1917), Bourdelle (1920), and Bourdelle and Bressou (1938 and 1953) omitted reference to the cardiac innervation. Schmaltz (1911 and 1927) failed to illustrate the course of specific heart nerves in his atlas. Koch (1965) omitted the description of the cardiac nerves in all species of domestic animals.

Chauveau (1905), in the horse, described cardiac nerves arising from the middle cervical (vertebral) ganglia, inferior cervical (cervicothoracic) ganglia, pneumogastric trunks, cervical sympathetic cords, and spinal medullary fibers. On the left side, two nerves arose from the middle cervical (vertebral) ganglion and disappeared on the vessels arising from the brachial artery. Another arose from this ganglion, and joined the spinal medullary fibers, rami from the sympathetic trunk, and filaments from the left pneumogastric. Together, these passed to the great vessels and the ventricles. On the right side two principal and four secondary nerves were described. The first principal nerve arose from the right middle cervical (vertebral) ganglion. It received branches from the inferior cervical (cervicothoracic) ganglion and sometimes from the second middle cervical (left vertebral?) ganglion and passed to the heart where it mixed with the

left cardiac nerves. The second principal right cardiac nerve arose from the pneumogastric and passed to the left ventricle and roof of the auricles. The four secondary nerves arose from the right pneumogastric trunk and passed to the large vessels and walls of the heart. No cardiac nerves were mentioned from the thoracic ganglia or recurrent laryngeal nerves. He referred to the cranial cervical ganglion also as the guttural ganglion.

McFadyean (1903, 1922) referred to the stellate, greyish, middle cervical (vertebral) ganglia, inferior cervical (cervicothoracic) ganglia, and vagal trunks as giving cardiac nerves in the horse. On the left he described two nerves arising from the middle cervical (vertebral) ganglion. One goes to the arteries and the mediastinum. The other, by one branch, passed to the left auricle and along the right coronary artery, and by a second branch along the left coronary artery. Cardiac nerves from the left inferior cervical (cervicothoracic) ganglion passed to the left auricle. No vagal or thoracic cardiac nerves were noted on this side. On the right side a large nerve from the middle cervical ganglion accompanied the right vagus, caudally, to the ventral face of the trachea. Here it left the vagus, passed to the left, caudal to the aorta, and continued along the right coronary artery. A nerve from the inferior cervical (cervicothoracic) ganglion joined the nerve just described. Right vagal nerves passed to the right auricle.

Communications between the cardiac nerves and the recurrent laryngeal nerves were also noted.

Mannu (1914) investigated the cardiac nerves from their origin to the cardiac plexus in the equine, bovine, ovine, caprine, canine, and feline. He described three cervical ganglia in all species. These were the superior cervical (cranial cervical), middle cervical (vertebral), and inferior cervical (cervicothoracic) ganglia. He noted the fusion of the latter ganglion with the first thoracic ganglion in the majority of his specimens in each species. The middle cervical (vertebral) ganglion was called the stellate ganglion. One divided or two separate cardiac nerves were reported from the left middle cervical (vertebral) ganglion passing to the great vessels and cardiac plexus. Two nerves arose from the homologous ganglion on the right and proceeded to the same areas. One nerve arose from each inferior cervical (cervicothoracic) ganglion and entered the cardiac plexus.

Connections between sympathetic nerves, the vagi, and recurrent laryngeal nerves were also noted.

Bradley (1922) noted the confluence of the caudal cervical and first thoracic ganglion in the horse. He omitted reference, however, to any ganglia between the cranial and caudal cervical ganglia in either the book on the thorax and abdomen (1922) or the book on the head and neck (1923). He did not describe the origin or course of the cardiac nerves, but indicated that branches

from the recurrent laryngeal nerves, sympathetic ganglia, and vagi all passed to the cardiac plexus.

Hopkins (1937) included a more accurate description of the cardiac innervation of the horse than is found in other textbooks. He noted that the cervical sympathetic ganglia at the base of the neck (vertebral ganglia) had been variously designated as inferior, posterior, middle, or caudal cervical ganglia. He chose the latter for his descriptions. On the left he noted that a blending of this ganglion with the first thoracic commonly occurred. Three cardiac nerves arose from the left side. One from the caudal cervical (vertebral) ganglion passed to the pericardial mediastinum and great vessels. Another from this ganglion joined by two vagal branches passed to the left atrium and the great vessels in the vicinity of the ligamentum arteriosum. A second branch of this nerve continued between the pulmonary artery and aorta to the right ventricle. Sometimes another branch passed to the left coronary groove. The remaining nerve also arose from the caudal cervical (vertebral) ganglion. It joined a right cardiac nerve to the right of the aorta, returned to the left side caudal to the aorta, and entered the left coronary groove. It ramified on both ventricles.

On the right side, two principal and one or more small cardiac nerves were observed. One principal nerve arose from the right caudal cervical (vertebral) ganglion and

joined the left nerve just described. The other principal cardiac nerve arose from the first thoracic ganglion and joined the vagus near the origin of the right recurrent laryngeal nerve. From this area one or more cardiac nerves were distributed to the atria. In one specimen he noted a nerve from the first thoracic (cervicothoracic) ganglion passing caudally, ventral to the longus collimuscle. This dropped ventrally into the plexus at the base of the heart. No cardiac nerves were noted arising caudal to the first thoracic ganglion.

Ellenberger and Baum (1943) reported the presence of the anterior (cranial) and posterior (caudal) cervical ganglia in the neck of the horse. Additional middle cervical (vertebral) ganglia were found in the cow, dog, and pig. In the horse these ganglia generally joined the posterior (caudal) cervical and first one to three thoracic ganglia to form the cervicothoracic ganglion. It was noted that according to its form this was called the ganglion stellatum. The cardiac nerves of the horse were not described.

Bruni and Zimmerl (1951) considered the middle cervical (vertebral) ganglion an anterior continuation of the caudal cervical ganglion when the latter was double. A cardiac branch arose from the cranial part of the caudal cervical ganglion or middle cervical (vertebral) ganglion when the latter was present. Another arose from the posterior portion of the caudal cervical ganglion. From the left side two or

three cardiac nerves originated from the vagus, but were fewer in number and thinner than on the right. No explanation of their courses or distributions, other than to the cardiac plexus, was noted.

Sisson and Grossman (1953) described the blending of the posterior cervical (caudal cervical) ganglion and first thoracic ganglion in the horse to form the ganglion stellatum. The middle cervical (vertebral) ganglion was noted in some cases. Three left and two right cardiac nerves were noted arising from the caudal cervical ganglia, first thoracic ganglia and vagal trunks. The descriptions of the distribution of these nerves followed that described earlier by Hopkins (1937).

Rooney (1956) recognized the blending of the caudal cervical and first thoracic ganglia in the horse, but reversed the order of the name applied and called them the thoraco-cervical ganglia. Nerves from these ganglia and from the vagi anastomosed with similar nerves on the opposite side and passed to the heart.

Usenik (1957) referred to the caudal cervical and first thoracic, whether fused or unfused, as the stellate ganglion in the horse. A ramus communicans to the second thoracic nerve was noted. The vertebral ganglion was called the intermediate ganglion. From this ganglion two or three cardiac nerves were reported passing to the heart. In two cases he found no cardiac nerves from this ganglion on the

right side. From the stellate ganglia one nerve on the right and one or two on the left passed to the heart.

Akaevskii (1962) included the cranial, middle (vertebral), and caudal cervical ganglia in his descriptions of the cervical sympathetic trunk. The latter are described as incorporated into the stellate or cervicothoracic ganglia. The *accelerantes cordis* nerve arose from the stellate (cervicothoracic) ganglia and passed to the heart. From the vagi, *depressor cordis* nerves passed to the heart. Further descriptions of these nerves were not included. Tagand and Barone (1964), in the horse, regarded the vertebral ganglion on both sides as the ganglion stellaire (ventral part). The caudal cervical ganglion was considered separate from the first thoracic and was called the ganglion stellaire (dorsal part). Cardiac rami were noted from the ventral parts of the stellaire ganglia, the vagi, the left first thoracic ganglion and right first and third thoracic ganglia. Coronary nerves from both sides were illustrated following the coronary arteries, however, only a very superficial description of their course and distribution was noted.

Most authors recognized the presence of three cervical ganglia in the horse. Generally a blending of the latter one or two ganglia was noted with the first thoracic ganglia. Those reporting cardiac nerves often noted their origin from the caudal two cervical ganglia and the vagi. On the left

side, from one to three nerves were observed, while on the right two or three were generally noted. Their courses and distributions were variously and quite superficially described. Further consideration to the differences will be noted in the discussion.

Investigations on the cardiac innervation of the artiodactyla, before the study of Wolhynski, F. A. (1928) in the bovine, were concerned primarily with the depressor nerve. Perman (1924) reviewed this literature in the calf, sheep, goat, and swine. He also dissected eleven calves, one sheep, and one goat. The superior cervical (cranial cervical), middle cervical (vertebral), stellate (cervicothoracic), and thoracic ganglia were noted as giving heart nerves in his investigation. In the bovine, from the left side, nerves from the stellate (cervicothoracic) ganglion formed a trunk which supplied the large arteries and the ventral walls of the right ventricle. A left vagal nerve passed to the aorta and ductus Botalli (ductus arteriosus). Left thoracic nerves between the third and sixth ganglia joined to pass onto the dorsal walls of both ventricles and the lateral part of the left ventricle. On the right side one nerve from the stellate (cervicothoracic) ganglion extended to the right auricle. Other nerves from this ganglion joined the right vagal and right recurrent branches forming a large trunk. This passed to the ventral part of the left ventricle and, in one case, also to this surface of the right ventricle.

Lastly, another nerve from this ganglion joined branches from the third or fourth thoracic ganglia and followed the vena azygos to the right ventricle. One nerve arose from the vagus at the level of the hilus of the lung and passed to the right auricle.

In the goat a nerve from the right stellate (cervicothoracic) ganglion and another from the right vagus passed to the anterior longitudinal furrow. No nerves were observed arising from the right third or fourth thoracic ganglia and passing to the heart. Other heart nerves were described as corresponding to those in the calf.

In the sheep Perman (1924) found the innervation much like that of the cow and goat. Exceptions included no vagal nerves to the heart other than one to the aorta and ductus Botalli (ductus arteriosum).

An important previous work that Perman omitted was by Mannu (1914). He noted the same number and location for cervical ganglia giving nerves to the heart of the artiodactyla as did Perman (1924). In the bovine a large nerve from the middle cervical (vertebral) ganglion joined a nerve from the inferior cervical (cervicothoracic) ganglion and passed to the cardiac plexus. Two cardiac nerves were described as originating from the posterior cervical (cervicothoracic) ganglion on each side. In the caprine the only cardiac nerve described originated from the inferior cervical (cervicothoracic) ganglion. In the ovine only two

cardiac nerves were observed. Each arose from the middle cervical (vertebral) ganglion.

Kazem-Beck (1888), though primarily concerned with the depressor nerve, included in his investigation a description of the other cardiac nerves. Apparently his description has been the only morphologic investigation recorded in the porcine in this area. He described the depressor nerve enclosed in the vagus nerve in the cervical region. He noted a large number of nerves to the anterior ventricular surfaces which arose from the inferior cervical (vertebral) ganglion, first thoracic ganglion, vagus, and right recurrent nerve. Behind the aorta, nerve bundles divided and extended onto the ventricular surfaces and auricles from the coronary grooves. Left vagal and sympathetic nerves primarily supplied the posterior surfaces of the ventricles and auricles. Further detail was not supplied.

Wolhynski, F. A. (1928) described nerves to six areas on the heart. These included the anterior left longitudinal plexus, anterior right longitudinal plexus, posterior left longitudinal plexus, posterior right longitudinal plexus, anterior atrial plexus, and sinus plexus of Halleri. From these areas he traced nerves which originated in the inferior cervical (vertebral) ganglia, stellate (cervicothoracic) ganglia and thoracic ganglia as far caudal as at least the sixth ganglion. No cardiac nerves were found originating from the inferior cervical (vertebral) ganglia. The largest

branch from the left sympathetics originated from the caudal pole of the left stellate (cervicothoracic) ganglion, passed caudally to the right of the aorta, joined with a nerve from the left vagus, returned to the left side caudal to the aorta, and descended in the left longitudinal sulcus. Another nerve from this ganglion passed on the left side of the brachiocephalic artery to the anterior portions of the atria. Three or four remaining nerves from the left stellate (cervicothoracic) ganglion continued ventrally on the anterior surface of the brachiocephalic artery and aorta and ramified on the right ventricle. A branch from the left vagus also joined these nerves. Thoracic cardiac nerves from the left side followed the vena hemiazygos to the left auricle and ventricle. From the right stellate (cervicothoracic) ganglion two cardiac nerves passed along the cranial surface of the aorta to the right ventricle. Fine nerves from the caudal part of this ganglion, together with right thoracic and right vagal nerves, followed the vena azygos to the right side of the atria and ventricles. An additional ganglion was found on the vena azygos which he referred to as Wrisberg's ganglion. Some of the right sympathetic nerves passing along the vena azygos passed through this ganglion. According to Hardesty (1933) the cardiac ganglion (ganglion of Wrisberg) lay in the cardiac plexus on the right side of the ligamentum arteriosum. Mizeres (1963) placed this inconstantly occurring ganglion between the arch of the aorta and pulmonary trunk.

Ionescu and Enachescu (1928) described thoracic cardiac nerves arising from both sides in the bovine, but only on the left side in the sheep. On the right side only one nerve was found. It originated from the second, third, or fourth ganglion and passed to the right atrium. Three or four thick cardiac nerve trunks were formed by numerous nerves originating from the second through sixth left thoracic ganglia. These supplied the posterior wall of the left atrium as they crossed it and then the wall of the left ventricle, and sometimes the right ventricle from the coronary groove and anterior longitudinal sulcus.

Ellenberger and Baum (1943) described the anterior (cranial) cervical ganglion, middle (vertebral) ganglion, and posterior (caudal) cervical ganglion in the cervical region of the artiodactyla. The posterior cervical fused with the first thoracic in the bovine and caprine, but not in the sheep. In the bovine a large middle cardiac nerve joined the posterior cardiac nerve and ended in the cardiac plexus. The cardiac nerves were not described in the ovine, caprine, or porcine.

Sisson and Grossman (1953) referred neither to the cardiac nerves nor their ganglia of origin in artiodactyla.

Waites (1957) traced cardiac nerves in the sheep with electrical stimulation. He showed that cardiac nerves arose as far caudally as the sixth thoracic ganglion. On each side, in addition to thoracic ganglia, he noted the stellate

(cervicothoracic) ganglion, middle cervical (vertebral) ganglion B, middle cervical (middle cervical) ganglion A, and superior cervical ganglion. Some impulses were traced from the right stellate (cervicothoracic) ganglion cranially to a point just caudal to the right middle cervical (middle cervical) ganglion (A) where they turned and passed to the heart. Cardio-accelerator fibers occurring in the right vagosympathetic trunk were reported as originating from the thoracic sympathetic outflow not from more cranial segments. Specific anatomical descriptions of the cardiac nerves were not within the scope of his investigation, however, the schematic illustrations he presented were anatomically similar to some of my findings.

McLeod (1958) listed the cervical ganglia of the bovine as anterior (cranial), middle (vertebral), and posterior (caudal). The latter could be fused with the first thoracic to form the stellate ganglion. The middle could be absent or fused with the stellate (cervicothoracic) ganglion. One cardiac nerves passed from each stellate ganglion to the base of the heart. Nerves passing to the heart were also noted from the third to sixth thoracic ganglia and the vagus nerves.

Habel (1964) omitted the description of the cardiac nerves in the domestic ruminants.

May (1964) in the sheep noted the presence of cardiac nerves from the first through third thoracic ganglia on the

right and through the fourth ganglion on the left. He described the first thoracic and caudal cervical ganglia as being five to seven centimeters apart. The latter was located cranial to the thorax. No cardiac branches were noted from the caudal cervical ganglion. One was observed on each side arising from the vagal trunks.

In the carnivores, several investigations have been undertaken on the cardiac innervation; however, few anatomical textbooks included detailed descriptions. Chauveau (1905), Harrison (1948), Bruni and Zimmerl (1951), Bourdelle and Bressou (1953), Breland (1953), Sisson and Grossman (1953), Akaevskii (1962) and Koch (1965) disregarded the cardiac innervation of the cat.

Of the preceding, only Sisson and Grossman (1953) mentioned cardiac nerves in the dog. Related ganglia included the posterior cervical (vertebral) ganglia, and first thoracic (cervicothoracic) ganglia. Two or three cardiac nerves proceeded from these ganglia on the left side to the cardiac plexus. One or two right cardiac nerves arose from the vagus and another from the first thoracic ganglion and passed to the cardiac plexus.

Ellenberger and Baum (1943) noted cardiac nerves in both the dog and cat. They arose from the middle cervical (vertebral) ganglia and the cervicothoracic ganglia. The latter, in these two animals, included the caudal cervical ganglion

and first two or three thoracic ganglia on each side.

Cardiac nerves were also described as arising from the vagi and at least as far caudal as the fourth thoracic ganglia.

A description of their numbers, courses, and destinations was not presented. An illustration from Schurawlew (1928) was included, however.

In the periodical literature, much of the investigations before Perman (1924), concerned the depressor nerve. He reviewed this literature.

Lim Boon Keng (1893) provided the first comprehensive morphological description of cardiac nerves in the dog. He described one cardiac nerve from each cervical ganglion. These ganglia included the superior (cranial) cervical, middle cervical (vertebral), and inferior cervical ganglia. He noted the fusion of the latter with the first one or two thoracic on each side to form the ganglion stellatum (cervicothoracic ganglion). Cardiac branches were also noted from the recurrent laryngeal nerves and the vagi. The auricles and ventricles of each side were partly supplied by cardiac nerves from the same side. The median half of the auricles and ventricles were supplied by opposite sides. No separate depressor nerve was noted in the dog.

Mannu (1914) reported the cardiac nerves of one dog and one cat. In the dog he found a thin middle cardiac nerve from the middle cervical (vertebral) ganglion which

passed to the cardiac plexus. No cardiac nerves were noted from the combined inferior (caudal) cervical and the first two thoracic ganglia. In the cat no right middle cervical (vertebral) ganglion was noted. An inferior cardiac nerve (though a typographical error makes it read otherwise) arose from the combined inferior (caudal) cervical and first thoracic ganglia.

Perman (1924) referred to the same ganglia as Lim Boon Keng (1893). In the dog he noted on the right a single branch derived from the ansa Vieusseni (ansa subclavia), vagus, middle cervical (vertebral) ganglion, and stellate (cervicothoracic) ganglion. These united nerves joined smaller branches from the left recurrent laryngeal nerve and left middle cervical (vertebral) nerve and passed to the right and left ventricles. From the left a branch from the vagus arose cranial to the middle cervical (vertebral) ganglion, united with a nerve from this ganglion, and passed between the aorta and pulmonary artery to the right ventricle. One or two large branches from the left middle cervical (vertebral) and left stellate (cervicothoracic) ganglia joined a branch of the left vagus and then a branch of the left recurrent laryngeal nerve and passed to the anterior longitudinal sulcus. The left atrium was supplied by the left stellate (cervicothoracic) ganglion and the left vagus. Two branches from the right vagus arose between the origin of

the right recurrent laryngeal nerve and the hilus of the lung and passed to the lateral wall of the right atrium.

In the cat, Perman (1924) reported the same ganglia as in the dog. On the left the depressor nerve joined a branch of the middle cervical (vertebral) ganglion and one or two vagal branches and passed between the aorta and pulmonary artery and joined a nerve from the right side. They passed to the wall of the right ventricle. On the right side the depressor nerve joined nerves from the middle cervical (vertebral) and stellate (cervicothoracic) ganglia and passed to the ventral walls of the ventricles as in the dog. The supply to the atria was as described for the dog.

Ionescu and Enachescu (1928) were concerned only with thoracic cardiac nerves. In the dog they described thoracic cardiac nerves which arose between the second and fifth thoracic ganglia on the right and from the third ganglion on the left. They passed to the right and left atria respectively.

Anufriew (1928) described the cardiac innervation extending to six areas of the cardiac plexus as had Wolhynski, F. A. (1928) in the calf. On the left, nerves passed from the stellate (cervicothoracic) ganglion, thoracic ganglia, and left vagus to the caudal portion of the left auricle and onto the left ventricle. The left depressor nerve sent branches to the aorta, pulmonary artery, and into the anterior longitudinal sulcus. A nerve from the right

stellate (cervicothoracic) ganglion together with a branch from the right recurrent laryngeal nerve coursed around the caudal border of the aorta and down the anterior longitudinal sulcus supplying both ventricles. Another branch proceeded between the aorta and pulmonary artery to the right ventricle. Other nerves from the right stellate (cervicothoracic) ganglion and right vagus passed to the anterior portions of the atria.

Schurawlew (1928), in the dog, used the same method and description as Anufriew (1928) and Wolhynski, F. A. (1928) for describing the nerves to areas of the cardiac plexus. On the left side, nerves from the second and third thoracic ganglia, stellate (cervicothoracic) ganglion, inferior cervical (vertebral) ganglion, and left vagus nerve passed over the posterior border of the left auricle supplying this and the left ventricle. Other nerves from the left inferior cervical (vertebral) ganglion with vagal branches passed on either side of the pulmonary artery to the ventricles. On the right side, nerves from the inferior cervical (vertebral) ganglion and vagus passed to the right ventricle. Others of these nerves together with a nerve from the stellate ganglion passed to the anterior portions of the atria.

Nonidez (1939), aware of the previous two articles, conducted a histologic study in dogs and cats, with differential staining, to ascertain the components of the cardiac

nerves and the areas they supplied.

He found that the superior cardiosympathetic nerve arose from the middle cervical (vertebral) ganglion, and passed to the aorta. It sometimes carried nerves from this ganglion to the cardiac plexus or to the anterior walls of the atria.

The largest nerve arising from the middle cervical (vertebral) ganglion in the dog was distributed to the ventricles. On the left it followed the left coronary artery. The right nerve passed to the origin of the coronary arteries and then to the anterior surface of the left ventricle and to the right ventricle. The middle cervical (vertebral) ganglion in the cat was too small to emit this large nerve. Instead it arose from the stellate (cervicothoracic) ganglion or ansa subclavia and passed to the same areas as in the dog.

The inferior cardiosympathetic nerve arose from the stellate (cervicothoracic) ganglion. It was inconstant in the dog on the left and absent on the right. When present it commonly joined the large accelerator nerve from the middle cervical (vertebral) ganglion. In the cat several nerves arose from the right stellate (cervicothoracic) ganglion, but only one from the left. Most passed to the ventricles. The presence of thoracic cardiosympathetic nerves, was based mostly on the work of previous authors. Left nerves were better developed than right ones.

One cardiovagal nerve was observed on each side in the dog. The left nerve arose at the level of the middle cervical (vertebral) ganglion, which it received fibers from, and passed to the aorta, subclavian artery, and pulmonary bifurcation. In the cat it arose from above the middle cervical (vertebral) ganglion. Its distribution was similar to that of the dog. It has often been referred to as the depressor nerve. On the right the cardiovagal nerve joined the large middle cervical (vertebral) cardiac nerve and passed with it to the heart. In the cat the nerve left the vagus at the level of the tracheal bifurcation and passed to the right atrium between the venae cavae. Other nerves to the heart were noted from the recurrent laryngeal nerves.

Sacomanno (1943) conducted an investigation of the nerves to the heart of the cat by both degeneration and grossly stained dissection. He was able to follow these nerves only to the cardiac plexus. His descriptions included one cardiac nerve which arose from the middle cervical (vertebral) ganglion. The stellate (cervicothoracic) ganglion was described as the fused inferior (caudal) cervical ganglion with the first one to three thoracic ganglia. He agreed with the work of Anufriew (1928) on the other cervical sympathetic cardiac nerves of the cat; however, he indicated that Anufriew's (1928) descriptions were incomplete. From the cranial eight thoracic ganglia Sacomanno found an average

of 20.2 nerves from the right thoracic cranial and 20.1 from the left. Five to seven on each side were illustrated as reaching the cardiac plexus.

Cardiac nerves arising from the recurrent laryngeal nerves in the cat were rarely mentioned. Verity, Hughes and Bevan (1965) indicated that the right recurrent cardiac nerve contributed the major efferent and afferent innervations to the bifurcation and extra pulmonary portion of the pulmonary artery.

Investigations on the extrinsic cardiac innervation of the dog, following Nonidez (1939), were continued by Greenberg (1956) and by Mizeres (1955a, b, 1957, 1958).

The most complete textbook description of the cardiac innervation of any domestic animal was summed up by Stromberg (1964) in the dog. Most of his descriptions were derived from Mizeres (1955a, b, 1957, 1958); however, he referred to Greenberg (1954, 1956), and Nonidez (1939) for supplementation. Before describing the nerves, a quick review of the confusion about these ganglia in the dog was necessary. Nonidez (1939) refuted earlier reference to the ganglion located just anterior to the vertebral artery, as the caudal cervical ganglion and stated it should be called the middle cervical ganglion. Stromberg (1964) and Foust and Getty (1960) indicated that this ganglion, which they called the caudal cervical ganglion, was homologous to the middle

cervical ganglion of man. Mizeres (1955a) and Greenberg (1956) agreed that it was synonymous with the human intermediate or vertebral ganglion rather than the middle cervical ganglion. Previously in this review this author noted the preference for the designation of vertebral ganglion to comply with standardized nomenclature. The ganglion considered homologous to the caudal cervical ganglion of man is considered by all the investigators of the dog just mentioned as included in a fusion with the first one to three thoracic ganglia.

Modified from Stromberg and drawing from the original investigations of Mizeres (1955a, b, 1957, 1958, 1963), Greenberg (1956), Nonidez (1939) and other previously listed workers on the cardiac innervation of the dog, the following summarization of the nomenclature, origins and distributions were derived. The first name will be the one this investigator has found to best compare with the results of this present investigation.

Left Side

1. Thoracic cardiac nerves

Origin - the second and third left thoracic ganglia.

Distribution - not described by most - aorta and cardiac plexus.

2. Cervicothoracic cardiac nerve (stellate cardiac nerve, caudal or inferior cardiosympathetic nerve, inferior cervical sympathetic cardiac nerve).

Origin - left cervicothoracic ganglion and/or ansa subclavia.

Distribution - the cardiac plexus and left dorsal ventricular wall.

3. Vertebral cardiac nerves

- a) Caudolateral vertebral cardiac nerve (ventrolateral cervical cardiac nerve, middle cardiosympathetic nerve, left accelerator nerve, left middle cervical sympathetic cardiac nerve).

Origin - the left vertebral ganglion.

Distribution - the cardiac plexus, along the coronary arteries, atrial walls, left dorsal ventricular wall.

- b) Caudomedial vertebral cardiac nerve (ventromedial cervical cardiac nerve, left cranial cardiosympathetic nerve, superior cardio-sympathetic nerve, superior cervical sympathetic cardiac nerve).

Origin - the left vertebral ganglion and joined by a branch from the left vagus arising anterior to this ganglion.

Distribution - the ventral aortic arch, pulmonary artery, cardiac plexus, dorsal atrial walls, and along the coronary arteries.

- c) Craniomedial vertebral cardiac nerve (Brachiocephalic nerve, Innominate nerve).

Origin - the left vertebral ganglion.

Distribution - the Brachiocephalic artery and aortic arch.

- d) Dorsal vertebral cardiac nerve (Dorsal cervical cardiac nerve).

Origin - the left vertebral ganglion.

Distribution - Aortic arch, descending aorta, cardiac plexus, dorsal atrial walls, along the coronary arteries.

4. Cranial vagal cardiac nerves

Origin - left vagus.

Distribution - Cardiac plexus, along the coronary arteries.

5. Caudal vagal cardiac nerves

Origin - left vagus.

Distribution - cardiac plexus, along the coronary arteries.

Right Side

1. Thoracic cardiac nerves

Origin - the second, third, and fourth right thoracic ganglia when reported.

Distribution - lateral surface of the right atrium.

2. Cervicothoracic cardiac nerves (stellate cardiac

nerve, caudal or inferior cardiosympathetic nerve, inferior cervical sympathetic cardiac nerve).

Origin - right cervicothoracic ganglion and/or ansa subclavia.

Distribution - cardiac plexus, dorsal and ventral walls of the right atrium, right ventricle, left longitudinal sulcus.

3. Vertebral cardiac nerve (right brachiocephalic nerve, Innominate nerve, superior cardiosympathetic nerve, superior cervical cardiac nerve).

Origin - right vertebral ganglion.

Distribution - Brachiocephalic artery, aorta, cardiac plexus, and anterior walls of the atria, left longitudinal sulcus, right ventricle.

4. Recurrent cardiac nerve (middle cardiosympathetic nerve, middle cervical cardiac nerve).

Origin - right recurrent laryngeal nerve. Other nerves joined it from the right vertebral ganglion, right vagus, and left recurrent laryngeal nerve.

Distribution - the cardiac plexus, along the coronary arteries to the ventricles, and the right dorsal atrial wall.

5. Cranial vagal cardiac nerves

Origin - the right vagus.

Distribution - the cardiac plexus, right dorsal atrial wall and along the coronary arteries.

6. Caudal vagal cardiac nerves

Origin - the right vagus.

Distribution - cardiac plexus, right dorsal atrial wall, along the coronary arteries.

It should be emphasized that the foregoing synopsis of the investigations of cardiac innervation of the dog, which were reported by previous authors, was not the complete innervation for this species. Though similar, it was not compatible for the descriptions in other species either. Therefore, the uncomplicated method of describing these nerves by their origin from each ganglion or nerve has been employed. These ganglia and their locations were listed in the introduction.

Although a great amount has been written about the cardiac innervation in the last three centuries it seemed remarkable that this area in domestic animals had not been more thoroughly documented anatomically. Of the domestic animals, only the canine was documented in detail. Other species must be well documented morphologically to be useful for the advancement of science. It is hoped that this study will contribute towards this end.

MATERIALS AND METHODS

Forty embalmed specimens were observed in this study (five equine, five bovine, five ovine, five caprine, five porcine, five canine and ten feline). Each specimen was embalmed with a solution consisting of sixty percent alcohol, four percent formaldehyde, six percent phenol, two and one-half percent corn syrup (50% water) and twenty seven and one-half percent water. Additionally, in some specimens injection of latex in the arteries and veins facilitated dissection of the nerves. Though the staining techniques employed by Perman (1924) and by Saccomanno (1943) in their dissections of heart nerves were tried, this investigator preferred unstained, well embalmed cadavers.

On each specimen the thorax and neck were separated from the remainder of the body. The head was also retained in at least one specimen in each species. The ribs were removed near their vertebral articulations with a Stryker autopsy saw, exposing the thoracic cavity. Bone cutting forceps, scissors, scalpels and retractors were helpful in further preparing the areas of observation. This included exposure of the course of the vertebral nerve, removal of excess fat, excision of the pericardium, and removal of the lungs. Further dissection on each side was accomplished by macroscopic techniques with various sizes of thumb forceps. When extremely fine nerves were encountered the aid of a

Dazor (2) floating arm fluorescent illuminated magnifier or a magna-sighter 3-D binocular eye loupe was employed.

The area studied was three dimensional, therefore, photographs were taken of the left and right lateral aspects of representative specimens of each species. A Burke and James "Grover View Camera, 4 x 5", fitted with a Schneider-Kreuznach "Symmar" 1:5.6/210 mm - 1:12/370 mm. lens in a Linhof shutter, was employed for this photography. The film used was Polaroid 4 x 5 Land Film Packets, positive/negative type SS P/N. Projection of these photographs together with observations from the live specimens provided the basis for the lateral, modified, water color illustrations. The third dimension was represented by schematic illustrations of the dorsum of the heart. The vagi and sympathetic ganglia, emitting the cardiac nerves, were reflected laterally in the dorsal illustrations.

Although differentiation by sex, age, and breed was not incorporated into the present study, the weights and/or whether adult was noted.

RESULTS

In reporting the results of this study, the ganglia of origin as well as the cardiac nerves of each species were considered. Tables listing the measurements of the related ganglia and the areas of supply by individual cardiac nerves are found in Appendix A. Figures of the actual specimens dissected together with those illustrated are found in Appendices B and C. Hopefully these figures and tables will be useful during the reading of the results.

PART I. EQUINE

GANGLIA (FIGURES 1, 2, 15, 16 AND TABLE 1)

Thoracic Ganglia

The thoracic ganglia generally were not as sharply demarcated as in the other species studied. Caudal to the cervicothoracic ganglion, the thoracic ganglia began at the third or fourth thoracic intercostal space. More than one ganglion was never found per intercostal space. The sympathetic trunk between the second and fifth intercostal spaces bilaterally lay on the dorsolateral aspect of the longus colli muscle two to two and one-half centimeters paramedian. Caudal to this muscle the trunk lay at the junction of the heads of the ribs and the bodies of the vertebrae, maintaining the same paramedian relationship.

Cervicothoracic Ganglion

In the horse this ganglion was composed of the caudal cervical and first two thoracic ganglia. These two components could often be differentiated on the left side although they blended to form the cervicothoracic ganglion. On the right side they appeared as one ganglion.

The left cervicothoracic ganglion extended from the cranial border of the first intercostal space to the caudal border of the second intercostal space. On the right side it was more compact and lay in the first intercostal space.

On both sides the long, flattened, cervicothoracic ganglion swept obliquely, dorsally over the lateral surface of the longus colli muscle from the ventral intersection of this muscle with the esophagus on the left, or the trachea on the right.

Rami communicantes extended from the cervicothoracic ganglion caudally to at least the third thoracic spinal nerve. Cranially, it was possible to demonstrate rami communicantes from the vertebral nerve to the seventh through second cervical spinal nerves, inclusively. A separate ramus communicans was present to the eighth cervical spinal nerve from the cervicothoracic ganglion. Although horses of different sizes were used, relative values showed that the size of the homologous ganglia varied only slightly (Table 1).

Ansa Subclavia

The two limbs of the ansa subclavia passed ventrally on either side of the subclavian artery (brachial artery), from the cervicothoracic ganglion to the vertebral ganglion. Typically, the single caudal limb passed caudal to the origin of the costocervical artery and then cranial, ventral to the subclavian artery, and joined the vertebral ganglion. In one case the caudal limb was divided on the left side. The cranial limb in the horse was very short and wide, thus the vertebral and cervicothoracic ganglia may appear as one large

ganglion. The caudal limb of the ansa subclavia often escapes casual observation due to its very fine width. It was much longer than the cranial limb (Table 1).

Intermediate Ganglia

Independent intermediate ganglia were not grossly observed in the equine.

Vertebral Ganglion

In the horse this ganglion was located at the cranio-ventral end of the ansa subclavia at the point where the caudal and cranial limbs join after passing from the cervicothoracic ganglion. On both sides it was located directly anterior and medial to the vertebral artery on the ventrolateral surface of the esophagus on the left, and trachea on the right. No independent rami communicantes were noted, however, the vertebral nerve appeared to receive contributions from both the vertebral and cervicothoracic ganglia. The size of the vertebral ganglion on either side was about the same (Table 1).

Middle Cervical Ganglion

No independent middle cervical ganglion was noted in the equine.

Cranial Cervical Ganglion

I was only able to retain one horse head for this investigation; this being the smallest horse referred to in Table 1. In this specimen, the cranial cervical ganglion was not intimately associated with the vagus nerve in the area of the diffuse, grossly unidentifiable, inferior ganglion of the vagus. The cranial cervical ganglion lay medial to the paramastoid process of the occipital bone along the internal carotid arteries. It measured one and one-half centimeters long by four millimeters in diameter.

Vagosympathetic Trunk

The vagus nerve and sympathetic trunk lay in a common connective tissue sheath in the cervical region. Although communicating rami were present, particularly in the caudal cervical region, the two trunks retained their separate identities. No independent third trunk was noted on either side of the horse. However, an one millimeter wide nerve accompanying the left vertebral cardiac nerve was separated from the left vagus nerve for several centimeters cranial to the left vertebral ganglion. Another similar branch arose from the sympathetic trunk in this area. On the right side an one to two millimeter nerve arose from the sympathetic trunk two to four centimeters cranial to the vertebral ganglion. It accompanied the right vagus nerve ventral to the subclavian (brachial) artery and passed to the heart.

CARDIAC NERVES (FIGURES 1, 2, 15, 16, 29 AND TABLE 8)

Thoracic Cardiac Nerves

Left side

Between the second and fifth intercostal spaces several fine thoracic cardiac nerves arose from the sympathetic chain. These joined to form a trunk about one millimeter in diameter which passed cranioventrally along the costocervical artery and joined the caudal limb of the ansa subclavia. From here they followed the cervicothoracic nerves to the heart. Some of these thoracic nerves terminated on the brachiocephalic artery.

At the sixth thoracic intercostal space two to four nerves arose from the sympathetic trunk and passed ventrally on the sixth intercostal artery. One trunk, about one millimeter in diameter, combined with a similar trunk from the right side. This combined trunk was then joined by the combined right and left dorsal cervicothoracic cardiac nerves between the esophagus and aorta just dorsal to the trachea at the level of the sixth thoracic rib. The trunk thus formed passed between the aorta and trachea, sent a few branches to the cardiac plexus, and continued ventrally over the left lateral face of the left branch of the pulmonary artery. It proceeded caudoventrally between the left auricle and left pulmonary veins to the coronary groove which it

followed cranially to the right longitudinal sulcus giving fibers to the left atrium and ventricle in its course. At the junction of this sulcus and the coronary groove the main trunk of nerves ramified. Some fibers, passed down the right longitudinal sulcus to the ventricles, some crossed the sulcus and supplied the caudal portion of the right atrium and ventricle, and others penetrated the interatrial and inter-ventricular septum.

Instead of passing between the left auricle and left pulmonary veins, an additional trunk may pass caudally on the dorsum of the left atrium to reach the coronary groove between the large caudal pulmonary veins and the caudal vena cava. In route this, and the previously described trunk, contributed to supplying the left atrium and the portion of the left ventricle lying to the right side.

Right side

Zero to four thoracic cardiac nerves, up to one millimeter in diameter, were seen on the right side originating from the second to fifth intercostal spaces. They either joined the ventral cervicothoracic cardiac nerve or passed directly caudoventrally along the right azygos vein to the cranial vena cava. Here they ramified on the cranial vena cava and gave off short twigs which joined the right caudal vagal cardiac nerves passing to the cardiac plexus and lateral right atrial wall.

From the fifth, sixth, and seventh intercostal spaces fine thoracic nerves joined to form the right thoracic cardiac nerve previously mentioned. This nerve, about two millimeters in width, passed ventrally, united with a homologous nerve from the left side and the right and left dorsal cervicothoracic cardiac nerves and passed to the heart as described under the left thoracic cardiac nerve. Areas receiving right thoracic cardiac nerves included the cardiac plexus, left atrium, caudal right atrium and ventricle, interatrial and interventricular septa, and the right portion of the left ventricle.

Cervicothoracic Cardiac Nerves

Left side

Usually three nerves arose from the cervicothoracic ganglion and passed to the heart.

Cranial cervicothoracic cardiac nerve The cranial limb of the ansa subclavia was much larger than the caudal limb in the horse; thereby, carrying most of the cardiac nerves. Some passed to the vertebral ganglion before traversing to the heart but other ventral cranial cervicothoracic cardiac nerves passed from the ventral aspect of the cranial limb, with the left vertebral cardiac nerves, caudally over the left lateral face of the brachiocephalic artery and the aorta to the heart. Their distribution was in common

with the left vertebral cardiac nerve along the course of the coronary arteries and between the vena cava. Further descriptions are included under the left vertebral cardiac nerve.

Caudal cervicothoracic cardiac nerves

Dorsal caudal cervicothoracic cardiac nerve This nerve, measuring about one millimeter in diameter, arose from the dorsomedial aspect of the cervicothoracic ganglion. It passed caudally on the left lateral side of the esophagus and trachea and between the aorta and esophagus and combined with the right dorsal cervicothoracic cardiac nerve and the right and left thoracic cardiac nerves at the level of the sixth rib. It then supplied the cardiac plexus, left atrium, caudal right ventricle, interventricular and interatrial septa, and right portion of the left ventricle in common with these nerves as described under the thoracic cardiac nerves.

Ventral caudal cervicothoracic cardiac nerve

This nerve, about one millimeter wide in the horse, followed the caudal limb of the ansa subclavia ventrally to the caudal face of the subclavian (brachial) artery. From this site it passed caudally, medial to the costocervical artery. It continued caudally on the dorsum of the brachiocephalic artery and obliquely crossed the left lateral surface of the aortic arch entering the area bounded by the descending aorta dorsally, the pulmonary artery ventrally, the ligamentum arteriosus cranially and the apical bronchus caudally. Here

several branches arose. One branch continued caudally between the left pulmonary veins and the left auricle to ramify along the course of the left circumflex coronary artery in common with the thoracic cardiac nerves and dorsal cervical thoracic cardiac nerves.

Other branches from the ventral cervicothoracic cardiac nerve passed to the aorta, pulmonary artery, left pulmonary veins and into the cardiac plexus. From the cardiac plexus a branch of this nerve was followed to the right side anterior to the right branch of the pulmonary artery and onto the right lateral atrial wall between the vena cava. One main continuation passed ventrally over the coronary groove and down the right longitudinal sulcus where it ramified. Another branch joined the right ventral cervicothoracic cardiac nerve and passed caudally dorsal to the right pulmonary artery onto the dorsum of the left atrial wall and also sent a twig anterior into the area between the venae cavae. A large branch, leaving the left caudal ventral cervicothoracic cardiac nerve before it reached the cardiac plexus, passed to the right side caudal to the aorta and combined with the right cranial ventral cervicothoracic cardiac nerve. A main trunk from this passed ventral to the left branch of the pulmonary artery and ramified along the left longitudinal sulcus.

In all cases the main trunk of this nerve passed between

the left pulmonary veins and the left auricle to the right side of the left atrium and ventricle and into the right longitudinal sulcus.

In one case the caudal cervicothoracic cardiac nerve was included, after about two centimeters, with the left cranial ventral cervicothoracic cardiac nerve and the left vertebral cardiac nerve.

Right side

Cranial cervicothoracic cardiac nerves Fewer cranial cervicothoracic nerves were demonstrated by-passing the right vertebral ganglion in their courses to the heart than on the left. The right cranial cervicothoracic cardiac nerves followed the cranial limb of the ansa subclavia ventrally around the subclavian artery, and passed caudally ventral to the vagus. As it passed the vertebral ganglion it joined the vertebral cardiac nerve and caudal to the subclavian artery was joined by branches from the right recurrent cardiac nerve, and a left cranial cardiac nerve. The combined trunk passed on the right dorsolateral face of the brachiocephalic artery over the lateral surface of the aorta and entered the cardiac plexus. Here it primarily passed to the left side caudal to the aorta, and entered the left longitudinal sulcus. Other branches of this nerve supplied the dorsum of the left atrium. One of them continued between the left auricle and left pulmonary veins to the coronary groove where it gave

branches to the right side of the left ventricle, ventral part of the left atrium, caudal right ventricle and interatrial septum. Twigs also passed between the vena cava onto the lateral right auricular wall.

In two cases the cranial cervicothoracic cardiac nerves and ventral cardiac nerves were inseparable from the vagus. Presumably they arose from the right vagus, one to four centimeters caudal to the subclavian artery, and passed in common with the caudal vagal cardiac nerves to the same areas just described.

Caudal cervicothoracic cardiac nerves

Dorsal caudal cervicothoracic cardiac nerve The

dorsal caudal cervicothoracic cardiac nerve, about one millimeter in diameter, arose from the caudodorsal part of the cervicothoracic ganglion. It passed caudally on the right side between the trachea and longus colli muscle and joined the left dorsal cervicothoracic cardiac nerve and the right and left thoracic cardiac nerves at the level of about the sixth thoracic vertebra. From there it passed to the cardiac plexus, left auricle and atrium, caudal and right portion of the left ventricle, right ventricle and the interatrial and interventricular septa as described under the thoracic cardiac nerves.

Ventral caudal cervicothoracic cardiac nerves

This nerve followed the caudal limb of the ansa subclavia

ventrally about half way to the subclavian artery. Here it left the ansa subclavia and passed obliquely caudal and ventral over the right side of the trachea. It continued between the cranial vena cava and aorta and ramified in the cardiac plexus. Its main branches passed through the right side of the plexus to the right lateral wall of the right atrium between the venae cavae. Some fibers crossed the atrio-ventricular junction and continued ventrally in the right longitudinal sulcus where they ramified onto the ventricular walls.

Intermediate Cardiac Nerves

No intermediate cardiac nerves were noted on either side.

Vertebral Cardiac Nerves

Left side

Together with the left cranial ventral cervicothoracic cardiac nerve this combined trunk made up the largest nerve (five millimeters wide) passing to the heart on the left side. It combined with the nerves directly from the cervicothoracic ganglion just caudal to the vertebral ganglion and the trunk thus formed and passed caudally, in close apposition to the vagus nerve with which it exchanged small twigs. Near the origin of the brachiocephalic artery, the trunk divided into several branches. The main branch passed directly ventral between the aorta and pulmonary artery cranial to the

ligamentum arteriosum. It sent twigs to the aorta, pulmonary artery, and between the right auricle and pulmonary artery to the right ventricle. Its main continuation followed from near the origin of the right coronary artery along this vessel's trunk in the coronary groove. From this area it ramified onto the right ventricle, and ventrum of the left auricle.

Another branch from the division of the left vertebral cardiac nerve continued caudally to the left and laterally to the ligamentum arteriosum. It then passed either medial or lateral to the pulmonary artery to join the cardiac plexus. Its main continuation from the plexus passed between the left auricle and pulmonary artery to the left longitudinal sulcus and adjacent right and left ventricles and inter-ventricular septum. Other branches continued caudally in the coronary groove supplying the left side of the left ventricle and the left auricle.

Before joining the cardiac plexus a twig left the branch just described caudal to the ligamentum arteriosum and passed to either side of the left branch of the pulmonary artery. The lateral twig continued caudally between the left auricle and left pulmonary veins to the coronary groove from which it ramified into the right side of the left ventricle. The medial twig supplied the dorsum of the caudal and left atrium, sent fibers between the left atrium and left pulmonary veins to the right part of the left ventricle,

and also dispatched fibers to the right atrium between the vena cava.

Other important branches from the division of the left vertebral cardiac nerve passed to the aorta, pulmonary artery, pulmonary veins, and the cardiac plexus.

Right side

In two cases the vertebral cardiac nerves and cranial cervicothoracic cardiac nerves intimately joined the right vagus nerve. As mentioned when discussing the right cranial cervicothoracic cardiac nerve, they apparently, in this case, left the right vagus two to four centimeters caudal to the ansa subclavia and passed to the same areas as when they proceed as independent nerves. In three cases a trunk formed by independent vertebral cardiac nerves passed caudally close to the right vagus, ventrally to the subclavian artery and then over the lateral surface of the aorta to the cardiac plexus. One branch passed through the plexus caudal to the aorta and proceeded ventrally into the left longitudinal sulcus, ramifying along its course onto the right and left ventricles and into the interventricular septum. It also supplied the areas described under the right cranial cervicothoracic cardiac nerve with which it was fused. These included the left atrium, right portion of the left ventricle, caudal portion of the right ventricle, ventral part of the left atrium, the interatrial and interventricular septa and the lateral surface of the right atrium.

Middle Cervical Cardiac Nerve

No middle cervical cardiac nerves were noted on either side.

Cranial Cardiac Nerves

Left side

No independent cranial cardiac nerves were formed in the area of the cranial cervical ganglion or inferior ganglion of the vagus nerve. However, a twig arising from the sympathetic trunk cranial to the vertebral ganglion passed to the left vertebral cardiac nerve and the right cranial cervicothoracic cardiac nerve. A branch also arose from the left vagus and is discussed under the section on the cranial vagal nerves.

Right side

No independent cranial cardiac nerves were formed in the area of the cranial cervical ganglion or inferior ganglion of the vagus nerve. However, an one to two millimeter wide nerve arose from the sympathetic trunk two to four centimeters cranial to the vertebral ganglion and passed to the heart with the right vertebral cardiac nerve and cranial cervicothoracic cardiac nerve.

Cranial Vagal Cardiac Nerves

Left side

An one millimeter wide nerve arose from the left vagus

nerve, two to ten centimeters cranial to the vertebral ganglion. It passed caudally along the sympathetic trunk, ventral to the vertebral ganglion, and accompanied the left vertebral cardiac nerves and cranial cervicothoracic cardiac nerve to the heart. It was separable from these nerves in one case and passed into the area around the ligamentum arteriosum ramifying to the aorta and pulmonary artery. In the other cases it was inseparable and presumably innervated the same areas as described for the left cranial cervicothoracic and vertebral cardiac nerves.

Between the vertebral ganglion and the heart fine communications occurred between the left vagus and the left vertebral and cranial cervicothoracic cardiac nerves. In one case a cranial vagal cardiac nerve from just caudal to the ansa subclavia joined the dorsal cervicothoracic cardiac nerve.

Right side

No right cranial vagal cardiac nerves were demonstrated.

Caudal Vagal Cardiac Nerves

Left side

Usually two main caudal vagal cardiac nerves arose from the vagus between the left recurrent laryngeal nerve and the division of the vagus into dorsal and ventral esophageal nerves. The most cranial nerve passed antero-ventrally to the right of the aorta, into the cardiac plexus over the right

branch of the pulmonary artery, and then mainly returned to the left side dorsal to the left branch of the pulmonary artery. It continued caudoventrally over the caudal border of the left auricle to the caudal and right portions of the coronary groove from which it accompanied the left circumflex coronary artery to the right longitudinal sulcus ramifying along this course.

The more caudal nerve passed anteroventrally between the aorta and pulmonary artery to the pulmonary plexus. One branch joined the trunk formed by the right and left fifth, sixth and seventh thoracic cardiac nerves and the right and left dorsal cervicothoracic cardiac nerves. Another branch passed onto the dorsum of the left atrium and coursed ventrally along the right lateral part of the interatrial septum. It ramified between the caudal pulmonary vein and the caudal vena cava and along the left circumflex coronary artery on the right side of the heart.

Right side

Three right caudal vagal cardiac nerves arose from two to five centimeters distal to the origin of the right recurrent laryngeal nerve. After approximately two to four centimeters two of them united and passed caudally between the anterior vena cava and the aorta where branches passed into the cardiac plexus. The main continuation passed ventrolaterally between the cranial and caudal vena cava to ramify on the right atrial

wall and along the right longitudinal sulcus. The third short nerve joined the right caudal ventral cervicothoracic cardiac nerve and accompanied it to the right atrium and right longitudinal sulcus as described for the latter nerve.

Recurrent Cardiac Nerves

Left side

After passing to the right side of the aorta the left recurrent laryngeal nerve gave several small twigs to the cardiac plexus. A communication between the left recurrent laryngeal nerve and the right caudal cervicothoracic cardiac nerve also was noted about half-way between the caudal limb of the right ansa subclavia and the heart.

Right side

Three main recurrent cardiac nerves, approximately five millimeters each, left the right recurrent laryngeal nerve and passed with each of the main right sympathetic trunks from this area. This included the right caudal ventral cervicothoracic cardiac nerves, cranial cervicothoracic cardiac nerve and the vertebral cardiac nerve. The areas innervated included the cardiac plexus, great vessels, lateral wall of the right atrium, left and cranial portions of the ventricles, and the areas adjacent to the coronary groove and longitudinal sulcus on the right.

PART II. BOVINE

GANGLIA (FIGURES 3, 4, 17, 18 AND TABLE 2)

Thoracic Ganglia

One distinct thoracic ganglion was located on each side in each intercostal space caudal to and including the third intercostal space. The third through seventh thoracic ganglia were larger than those ganglia further caudal, particularly on the left side. They reached the size of ten millimeters craniocaudal by four millimeters dorsoventral by two millimeters wide in the calf. The thoracic sympathetic trunks maintained an one and one-half centimeter paramedian position. Cranially they lay on the dorsolateral surface of the longus colli muscle. Caudally they passed lateral to the intercostal arteries lying near the junction of the heads of the ribs and the thoracic vertebrae.

An additional cardiac ganglion of the left intervascular triangle perhaps can best be described under this area. It was located caudal to the arch of the aorta at the junction of the vena hemiazygos and the left branch of the pulmonary artery. It measured about two millimeters by four millimeters by three millimeters. It received both dorsal cervicothoracic cardiac nerves and left thoracic cardiac nerves.

Cervicothoracic Ganglion

On both sides this ganglion lay at the level of the first intercostal space. It extended over the ventrolateral face of the longus colli muscle onto the dorsolateral surface of the esophagus on the left, and trachea on the right. It was composed of the caudal cervical and first two thoracic ganglia. Rami communicantes extended cranially via the vertebral nerve as far as the second cervical spinal nerve and caudally to at least the third thoracic spinal nerve.

Ansa Subclavia

The ansa subclavia of the bovine passed on either side of the subclavian artery, connecting the cervicothoracic and vertebral ganglia. Both limbs were single and of about equal diameter, but the caudal limb was longer than the cranial one. In three cases the vertebral ganglion closely approximated the cervicothoracic ganglion on the left side. In these specimens the caudal limb of the ansa subclavia passed also on the cranial side of the subclavian artery to reach the vertebral ganglion. As in the horse, the limbs of the ansa subclavia were very thin and could escape casual observation, particularly in the adult bovine.

Intermediate Ganglia

No intermediate ganglia were observed grossly in the bovine.

Vertebral Ganglion

In the bovine this ganglion was generally located anterior and medial to the costocervico-vertebral artery where the two limbs of the ansa subclavia joined after passing cranial and ventral from the cervicothoracic ganglion. In three cases, however, on the left side, due to the intimate association of this ganglion with the cervicothoracic ganglion, the vertebral ganglion lay caudal and medial to the cervico-vertebral artery. No rami communicantes were noted to the spinal nerves.

Middle Cervical Ganglion

No independent middle cervical ganglion was noted in the bovine.

Cranial Cervical Ganglion

This ganglion in the bovine lay medial to the paramastoid process of the occipital bone at the ventral medial border of the tympanic bulla. It was not fused with the inferior ganglion of the vagus nerve.

In the calf the cranial cervical ganglion measured fifteen millimeters rostrocaudally by eight millimeters dorsoventrally by four millimeters mediolateral.

Vagosympathetic Trunk

The vagus nerves and sympathetic trunk passed in a common connective tissue sheath between the vertebral ganglion and cranial cervical ganglion. The sympathetic trunk, one to two millimeters in width, could be separated from the vagus nerve, about four to eight millimeters in width. Communicating rami between the two nerve trunks were noted. No independent third trunk accompanied the vagosympathetic trunk on either side.

CARDIAC NERVES (FIGURES 3, 4, 17, 18, 30, AND TABLE 8)

Thoracic Cardiac Nerves

Left side

At least ten thoracic cardiac nerves, one millimeter or less in width, were seen originating from the sympathetic trunk between the cervicothoracic ganglion and the sixth intercostal space. These nerves passed ventrally and soon joined larger thoracic cardiac nerves which originated mainly from the third, fourth, and fifth thoracic ganglia. The largest of the thoracic cardiac nerves, about two to three millimeters in width, arose from the fourth thoracic ganglion.

From the more cranial ganglion the thoracic cardiac nerves continued ventrally and obliquely caudally across the longus collimuscle and lateral face of the aorta. The more

caudal nerves followed the intercostal arteries to the aorta and continued ventrally on it. These nerve trunks and the left dorsal cervicothoracic cardiac nerve then continued ventrally on the vena hemiazygos to the cardiac ganglion of the left intervascular triangle located caudal to the arch of the aorta at the junction of the hemiazygos vein and the left branch of the pulmonary artery. Twigs sometimes extended into the cardiac plexus. Efferent nerves from this ganglion, usually one or two, passed between the left auricle and pulmonary veins with the vena hemiazygos to the coronary groove. In this course twigs passed to the left auricle. From the coronary groove intermingling nerves ramified along the course of the circumflex branch of the left coronary artery. This included the ventral portion of the left atrium, the right side of the left ventricle, the interatrial and interventricular septa, and the right caudal part of the right ventricle from the right longitudinal sulcus.

Right side

Two or three thoracic cardiac nerves arose from the third intercostal space and passed ventrally for two or three centimeters to unite with the right caudal dorsal cervicothoracic nerve. The trunk thus formed continued ventrally on the vena azygos to the dorsum of the cranial vena cava. Twigs were given to this vessel as the main nerve trunk

passed caudally on it to the area of the right atrium between the vena cava. Here the trunk ramified on the lateral wall of the right atrium. Twigs sometimes extended across the coronary groove to the right longitudinal sulcus. Other branches left the nerve trunk dorsal to the cranial vena cava and entered the cardiac plexus or ramified on the right pulmonary veins.

Passing directly ventral from the fifth intercostal space was a two millimeter wide nerve formed from twigs originating from the sympathetic trunk between the fourth and sixth thoracic ganglia. It passed ventrally, medial to the thoracic duct, between the esophagus and aorta and passed to the left side, just caudal to the aorta, into the cardiac plexus. Its main continuation through the plexus comprised a large part of the trunk which continued into the coronary groove and down the left longitudinal sulcus, radiating onto the caudal and ventral portion of the left auricle, the left side of the left ventricle and the left caudal portion of the right ventricle. In one case a right, sixth, thoracic cardiac nerve coursed to the left between the longus colli muscle and aorta and joined the left thoracic cardiac nerves. It accompanied these nerves ventrally along the vena hemiazygos to the coronary groove. These nerves ramified along the circumflex branch of the left coronary artery as described under the left thoracic cardiac nerves.

Cervicothoracic Cardiac Nerves

Left side

Typically three areas were supplied by dorsal or ventral cervicothoracic cardiac nerves arising from the left cervicothoracic ganglion.

Cranial cervicothoracic cardiac nerves None were observed grossly.

Caudal cervicothoracic cardiac nerves

Dorsal cervicothoracic cardiac nerves A left dorsal caudal cervicothoracic cardiac nerve arose from the caudodorsal part of the ganglion and passed obliquely caudoventrally over the left lateral surface of the aorta to enter the cardiac ganglion of the left intervascular triangle located at the junction of the vena hemiazygos and the left branch of the pulmonary artery. Before entering this ganglion branches sometimes passed to the aorta or between this vessel and the pulmonary artery, caudal to the ligamentum arteriosum, and entered the cardiac plexus. Branches leaving this ganglion continued caudally, between the vena hemiazygos and left auricle to the coronary groove. From here twigs radiated along the course of the left circumflex coronary artery cranially onto the left atrium and ventricle, right ventricle, and interatrial septum.

Ventral cervicothoracic cardiac nerves Two to four ventral cervicothoracic cardiac nerves arose in common

with the caudal limb of the ansa subclavia. They originated from the ganglion at its ventral apex and passed caudoventral on the dorsal and ventral surfaces of the brachiocephalic artery.

The more dorsal of the left ventral cervicothoracic cardiac nerves passed to the right of the aorta, after following dorsally on the brachiocephalic trunk to its origin. Then it again coursed to the left side, caudal to the aorta, and entered the cardiac plexus. Its main continuation joined with the right fourth, fifth and sixth thoracic cardiac nerves to form the large trunk which passed down the left longitudinal sulcus. The area of distribution for this nerve included, primarily: the cardiac plexus; the left and caudal portion of the left ventricle, and ventrum of the left auricle, along the circumflex branch of the left coronary artery; and the right and left ventricular wall from along the descending branch of the left coronary artery.

A single left ventral cervicothoracic cardiac nerve, or two such nerves which joined near the origin of the brachiocephalic artery after passing caudally on either side of this vessel, passed between the right auricle and the pulmonary artery. They sometimes joined the right coronary artery and followed it, supplying the right ventricle and ventrum of the right atrium. Others radiated directly cranial onto the right ventricle or supplied the pulmonary artery. Some

fibers, instead of passing ventrally and along the course just described, continued caudally to the right of the aorta, supplying this surface and contributing twigs to the cardiac plexus. A right ventral cervicothoracic cardiac nerve of variable size joined this left nerve on the ventral surface of the brachiocephalic artery passing with it as just described. Left vagal cardiac nerves also joined this nerve more cranially.

Another constant ventral cervicothoracic cardiac nerve passed directly caudal on the dorsum of the brachiocephalic artery and ramified on the aorta from near the origin of the brachiocephalic artery caudally for six to eight centimeters. Some of these fibers communicated with the cardiac plexus caudal to the aorta.

Right side

Cranial cervicothoracic cardiac nerves None were observed in the bovine.

Caudal cervicothoracic cardiac nerves On the right side a single caudal dorsal cervicothoracic cardiac nerve was present together with one to three caudal ventral cervicothoracic nerves.

The dorsal nerve passed caudoventrally to join the right third thoracic cardiac nerves medial to the azygos vein, just dorsal to the trachea. It continued ventrally with this nerve to supply mainly the area between the vena cava, as previously described under the right thoracic cardiac nerves.

One to three caudal ventral cervicothoracic cardiac nerves left the caudoventral border of the cervicothoracic ganglion just caudal to the caudal limb of the ansa subclavia. One or two nerves passed caudoventrally along the dorsum of the cranial vena cava, then between this vessel and the aorta to ramify in the cardiac plexus. Their main limbs could be traced along the right extremity of the plexus and between the cranial and caudal vena cava to the right atrial wall. Fine twigs sometimes also accompanied the right caudal vagal and right recurrent cardiac nerves from the plexus between the caudal vena cava and left atrium to the coronary groove on the right side.

One additional caudal ventral cervicothoracic cardiac nerve coursed ventrally over the right lateral face of the trachea and onto the ventral aspect of the brachiocephalic artery where it joined a left ventral cervicothoracic cardiac nerve. This trunk passed between the right auricle and pulmonary artery where it then ramified. Branches accompanied the right coronary artery supplying mainly the right ventricle and auricle as previously described under the left ventral cervicothoracic cardiac nerves.

Intermediate Cardiac Nerves

No intermediate ganglia were noted on either side, therefore, no intermediate cardiac nerves were observed.

Vertebral Cardiac Nerves

Left side

No cardiac nerves could be found from the left vertebral ganglion. Apparently most nerves from this ganglion continued cranially in the sympathetic trunk. Fine twigs to the subclavian artery from this ganglion were noted.

Right side

Several twigs arose from the ventral extremity of this ganglion. Their length averaged only about one to two centimeters before they joined other trunks or ramified on surrounding vessels. Some twigs combined with the right vagus nerve and potentially could pass to the heart. I was unable to specifically trace them there, however. Another twig joined the right recurrent laryngeal nerve, along which fibers sometimes passed to the heart. Numerous twigs passed to the right carotid artery.

Middle Cervical Cardiac Nerves

No separate middle cervical cardiac nerves were noted since no separate ganglion was demonstrated.

Cranial Cardiac Nerves

No cranial cardiac nerves were demonstrated from either side.

Cranial Vagal Cardiac Nerves

Left side

Generally these nerves arose at two specific locations along the vagus nerve and accompanied the ventral cervicothoracic cardiac nerves to the heart. The first group, of one to three small nerves, arose from the vagus nerve within two centimeters caudal to the subclavian artery. They immediately joined the ventral cervicothoracic cardiac nerve which passed between the right auricle and the pulmonary artery to ramify along the right coronary artery onto the right auricle and ventricle.

The second area of origin for the cranial vagal cardiac nerves was between the first area and the ligamentum arteriosum. Usually a single nerve, about one to three millimeters in diameter, left the vagus here and passed with a ventral cervicothoracic cardiac nerve to the area of the ligamentum arteriosum. Here it ramified on the aorta and pulmonary artery. One branch was followed caudally between these vessels and joined the large nerve trunk passing to the left longitudinal sulcus. Other twigs joined the cardiac plexus.

Right side

Just as the vagus began to form the right recurrent laryngeal nerve, a small branch arose from the vagus nerve. It coursed caudally on the right lateral surface of the brachiocephalic artery and to the right of the aorta to the

cardiac plexus. This investigator was unable to establish any further area of distribution.

Caudal Vagal Cardiac Nerves

Left side

Generally two or three nerves originated from the left vagus nerve caudal to the origin of the left recurrent laryngeal nerve. These nerves passed ventrally over the lateral face of the left branch of the pulmonary artery and onto the dorsum of the left atrium, into the cardiac plexus; or they combined with the left thoracic cardiac nerves and entered the coronary groove between the left auricle and hemiazygos vein, thereby ramifying along the circumflex branch of the left coronary artery. Areas innervated in this course included the dorsum of the left auricle, ventrum of the left atrium, caudal and right portions of the left ventricle, interatrial and inter-ventricular septa, and right caudal portion of the right ventricle.

Right side

Usually one to three right caudal vagal cardiac nerves were present. These arose from the right vagus nerve, between two and five centimeters cranial to the right apical bronchus. They coursed caudoventrally, medial to the azygos vein and cranial vena cava to the dorsum of the right atrium. Here they ramified. Branches entered the cardiac plexus, the coronary groove from between the caudal vena cava and left

atrium, and the lateral right atrial wall between the cranial and caudal vena cava.

Recurrent Cardiac Nerves

Left side

Several fine branches originated from the left recurrent cardiac nerve on the caudal and right surfaces of the aorta. These passed ventrally and were lost in the cardiac plexus and on the dorsum of the left atrium.

Right side

A small right recurrent cardiac nerve passed caudally between the aorta and cranial vena cava from near the origin of the right recurrent laryngeal nerve. It joined a right caudal vagal cardiac nerve, or continued independently to the cardiac plexus between the cavae onto the lateral right atrial wall, or caudally between the caudal vena cava and the left atrium into the coronary groove.

PART III. OVINE

GANGLIA (FIGURES 5, 6, 19, 20 AND TABLE 3)

Thoracic Ganglia

Independent ganglia of inconstant size were present in each intercostal space from the second or third intercostal space caudally. Commonly, the most cranial of these independent ganglia on the right side began at the third intercostal space. On the left it more commonly began at the second space. These ganglia ranged from about one millimeter to over ten millimeters craniocaudally, five millimeters dorsoventrally, and two millimeters mediolateral. The third thoracic ganglion on the left was generally the largest. Caudal to the cervicothoracic ganglion the sympathetic trunk extended obliquely dorsally over the lateral face of the longus colli muscle. It was located at the junction of the ribs and thoracic vertebra caudal to this muscle and maintained approximately a ten millimeter paramedian position throughout the thoracic area. An additional ganglion sometimes lay on the left side in the area bounded by the descending aorta, vena hemiazygos and the pulmonary artery.

Cervicothoracic Ganglion

The left ganglion lay directly ventral to the head of the first rib while on the right it lay slightly more caudal, extending between the heads of the first and second ribs. On

both sides it lay on the lateral face of the longus colli muscle. Its ventralmost portion sometimes reached the dorsum of the esophagus on the left, and on the right the dorsum of the trachea.

The left ganglion usually included the caudal cervical and first thoracic ganglia. On the right it also included the second thoracic ganglion.

Rami communicantes were followed as far cranial as the second cervical spinal nerve. Caudally they extended to at least the second thoracic spinal nerve on the left and to the third on the right.

Ansa Subclavia

In the ovine this was formed by single limbs on either side of the subclavian artery connecting the cervicothoracic and vertebral ganglia. The caudal limb passed caudal and ventral to the subclavian artery and then cranial to join the vertebral ganglion. From the cervicothoracic ganglion the cranial limb passes cranioventral, medial to the vertebral artery, to join the vertebral ganglion. The cranial and caudal limbs were of about equal width, however, the caudal limb was much longer. The right limbs were longer than the left ones (Table 8).

Intermediate Ganglia

Independent intermediate ganglia were not grossly observed in the ovine.

Vertebral Ganglion

This ganglion, in the ovine, lay one to two centimeters cranial to the costocervico-vertebral artery at the cranial extremity of the limbs of the ansa subclavia. This was, further, on the lateral face of the esophagus on the left, or trachea on the right at the level of the seventh cervical vertebra. There appeared to be two ganglia at this location which were either fused, incompletely separate, or separated for a short distance. The more cranial component was assumed to be the middle cervical ganglion.

Middle Cervical Ganglion

Apparently, in most cases, this ganglion was fused with the vertebral ganglion, when present. In one case an independent ganglion, just cranial to the vertebral ganglion, was present. It measured four millimeters by two millimeters by one millimeter.

Cranial Cervical Ganglion

This ganglion lay craniomedial to the paramastoid process just ventral to the tympanic bulla. It was not intimately

fused with the inferior ganglion of the vagus nerve, which was slightly ventral to it. It measured fifteen millimeters in length, five millimeters in breadth and three millimeters in width.

Vagosympathetic Trunk

The vagus nerve and sympathetic trunks, between the inferior ganglion of the vagus nerve and cranial cervical ganglion and the vertebral ganglion, were enclosed in a common connective tissue sheath. The two trunks could be separated throughout their length, although they had communicating twigs between them. The sympathetic trunk measured approximately two millimeters in width and the vagus nerve, about four millimeters. An independent third nerve, measuring approximately one-fourth of a millimeter in width, accompanied the vagosympathetic trunk from the cranial laryngeal nerve for about four or five centimeters and then was lost in the vagus nerve.

CARDIAC NERVES (FIGURES 5, 6, 19, 20, 31 AND TABLE 8)

Thoracic Cardiac Nerves

Left side

The large, two millimeter wide, third thoracic cardiac nerve was joined by lesser nerves from the fourth, fifth and sixth thoracic ganglia along the vena hemiazygos. They

entered or by-passed the cardiac ganglion of the left vascular triangle and continued along the vena hemiazygos between the left pulmonary veins and the left auricle to the coronary groove. Branches passed to the left auricle and onto the caudal left ventricle but the main continuation followed the circumflex branch of the left coronary artery to the right longitudinal sulcus. Along this course it sent branches to the ventrum of the left atrium, right portion of the left ventricle, interatrial and interventricular septa, and the caudal part of the right ventricle. Just caudal to the ligamentum arteriosum, a left cervicothoracic cardiac nerve joined the thoracic cardiac nerves. When the second thoracic ganglion was independent, a fine nerve coursed caudally from it to join the other thoracic cardiac nerves just caudal to the ligamentum arteriosum along the vena hemiazygos. Twigs from the thoracic cardiac nerves, in the area of the cardiac ganglion of the left intervascular triangle, passed to the cardiac plexus.

Right side

Right thoracic cardiac nerves were demonstrated from the second through the sixth thoracic ganglia. These nerves, usually one per ganglion, measuring approximately one-fourth of a millimeter in width, connected on the dorsum of the esophagus to form a trunk which combined with a small cervicothoracic cardiac nerve, craniodorsal to the right

apical bronchus. This trunk continued caudoventrally to the apical bronchus and ramified into the cardiac plexus. Twigs could be followed between the venae cavae to the lateral wall of the right atrium, and cranially through the cardiac plexus ramifying along the right coronary artery.

Cervicothoracic Cardiac Nerves

Left side

Cranial cervicothoracic cardiac nerves None were observed grossly in the ovine.

Caudal cervicothoracic cardiac nerves One or two cervicothoracic cardiac nerves arose from the caudal border of the cervicothoracic ganglion, and/or the caudal limbs of the ansa subclavia, and passed to the heart. When two nerves were present the more ventral one followed the brachiocephalic artery to the anterior left lateral surface of the aorta. Here it broke up into several small branches. Some continued cranially between the right auricle and the pulmonary artery, passing to the right ventricle and the ventral portion of the right auricle from along the course of the right coronary artery. Others supplied the aorta and pulmonary artery.

When only one nerve was present the distribution of the nerves just discussed was assumed by this single nerve. A branch left the parent nerve, which had coursed caudally along the brachiocephalic artery, near the junction of this

artery with the aorta. The further course was as described before. Other branches of the single cervicothoracic or of the more dorsal nerve, when two were present, had two main destinations. The lesser contribution entered the area in which the brachiocephalic artery originated from the aorta and ramified. The larger continuing branch, after passing lateral to the ligamentum arteriosum, joined the thoracic cardiac nerves or the cardiac ganglion of the left intervascular triangle on the vena hemiazygos. Twigs passed to the cardiac plexus. The major portion of the left cervicothoracic cardiac nerve continued with the left thoracic cardiac nerves between the left auricle and the pulmonary veins, and cranially with the circumflex branch of the left coronary artery. Areas of distribution were the left auricle, ventrum of the left atrium, left ventricle on the caudal and right sides, interatrial and interventricular septa, and caudal part of the right ventricle.

Right side

One large nerve, two millimeters in width, and three to five smaller nerves, less than one millimeter in width, arose from this ganglion. The large, right, caudal cervicothoracic cardiac nerve assumed a variable role in the incorporation of the smaller nerves. In addition to the supply to the brachiocephalic artery and anterior vena cava by small nerves arising from the cranial and caudal limbs of the ansa subclavia, respectively, other small nerves joined the right

recurrent cardiac nerve and the thoracic cardiac nerves.

Cranial cervicothoracic cardiac nerves None were observed grossly in the ovine.

Caudal cervicothoracic cardiac nerves One or two, small, right, dorsal cervicothoracic cardiac nerves sometimes also left the caudal border of the cervicothoracic ganglion. They passed caudally to join the right thoracic cardiac nerves just cranial to the apical bronchus. Their distribution has been discussed previously as being to the cardiac plexus with branches continuing to the right atrium between the vena cava and along the right coronary artery to the right auricle and ventricle.

A right caudal ventral cervicothoracic cardiac nerve arose from the ventral pole of the right cervicothoracic ganglion, or from the caudal limb of the ansa subclavia, and passed ventrally, joining the right recurrent cardiac nerve within three centimeters caudal to its origin. Its distribution was along the course of the right coronary artery onto the right auricle, atrium and ventricle.

The large ventral cervicothoracic cardiac nerve arose from the most ventral portion (apex) of the cervicothoracic ganglion, in close apposition to the caudal limb of the ansa subclavia. It coursed obliquely caudoventrally over the right lateral surface of the trachea and between the cranial vena cava and aorta to enter the cardiac plexus. In this course it assumed or augmented the innervation of some of the

smaller right cervicothoracic cardiac nerves just described. One of its main branches could be followed through the anterior part of the cardiac plexus, between the aorta and right auricle and along the right coronary artery. Another passed between the venae cavae and ramified on the right atrium. A third main branch continued caudally between the right branch of the pulmonary artery and the right pulmonary veins and ventrally, just caudal to the caudal vena cava to the coronary groove. Twigs passed both medially and laterally to the coronary sinus, ramifying in the area. A final large branch passed through the plexus caudal to the aorta and followed the cranial margin of the left auricle to the coronary groove at the dorsum of the left longitudinal sulcus. In addition to the left auricle, twigs from this branch supplied the right and left ventricles and interventricular septum from the left longitudinal sulcus, and the left side of the left ventricle and ventrum of the left auricle from the coronary groove.

Intermediate Cardiac Nerves

No intermediate cardiac nerves were noted on either side.

Vertebral Cardiac Nerves

Left side

One or two small nerves originated from the left vertebral ganglion and passed to the brachiocephalic artery.

Direct independent nerves from the vertebral ganglion to the heart were not noted. However, it was conceivable that fibers traversing the cranial limb of the ansa subclavia could synapse in this ganglion, pass caudally in the caudal limb of the ansa subclavia to the ventral cervicothoracic cardiac nerve, and pass with this nerve to the heart.

Right side

As on the left, no independent vertebral cardiac nerves were observed. As speculated for the left side, perhaps fibers may accompany the right cervicothoracic cardiac nerves to the heart.

Middle Cervical Cardiac Nerves

No independent, left, middle, cervical cardiac nerves were demonstrated on either side. Because the middle cervical ganglion and vertebral ganglion were closely associated, or fused when the latter was present, perhaps nerves synapsing in the middle cervical ganglion passed with the cervicothoracic cardiac nerves to the heart, as postulated for the vertebral cardiac nerve.

Cranial Cardiac Nerves

Although nerves were emitted from the cranial laryngeal nerve on both sides, they were soon lost in the vagus nerves; hence, I was unable to trace them to the heart.

No nerves were demonstrated as arising from the cranial cervical ganglion passing to the heart.

Cranial Vagal Cardiac Nerves

Left side

One or two cranial vagal cardiac nerves arose from the left vagus nerve, just cranial to the origin of the brachiocephalic artery. One nerve sometimes passed to the dorsum of the brachiocephalic artery. The other constant nerve ramified onto the pulmonary artery and aorta in the area of the ligamentum arteriosum. Fibers sometimes reached the cardiac plexus ventrally from this area.

Right side

A nerve left the right vagus nerve, ventral to the subclavian artery, and passed caudally on the brachiocephalic artery to its origin. Here the nerve ramified on the aorta and brachiocephalic artery.

Caudal Vagal Cardiac Nerves

Left side

Several small left vagal cardiac nerves originated from the vagus nerve within three centimeters caudal to the origin of the left recurrent laryngeal nerve. Two or three joined the cervicothoracic and thoracic cardiac nerves on the vena hemiazygos and, with these nerves, continued ventrally to the heart, as described in the latter. As previously described,

the areas innervated include the left auricle and atrium, caudal and right portions of the left ventricle, interatrial and interventricular septa and the caudal right ventricle.

An additional three or four nerves entered the cardiac plexus between the branching pulmonary artery and the origin of the primary bronchi. Its main continuation through the plexus extended ventrally between the branches of the pulmonary artery and continued between the caudal vena cava and the left atrium to the coronary groove. Here it ramified along the circumflex branch of the left coronary artery into the interatrial and interventricular septa and onto the right and left ventricles.

Right side

Two to four right caudal vagal cardiac nerves arose from the right vagus nerve between the origin of the recurrent laryngeal nerve and the apical bronchus. They passed caudoventrally between the trachea and cranial vena cava, communicating freely with the right thoracic and cervico-thoracic cardiac nerves. In most cases the nerves joined into a single trunk before splitting into major branches. Their branches could be followed through the cardiac plexus to the following areas: one branch continued through the right side of the plexus, sent a twig between the vena cavae, and ramified on the right lateral wall of the right atrium; a continuing twig passed caudally between the right branch of the pulmonary artery and the right pulmonary veins and passed

ventrally between the caudal vena cava and left atrium to reach the areas of the coronary sinus where it ramified into the interatrial and interventricular septa and along the right longitudinal sulcus; another main branch continued towards the left side between the cranial vena cava and aorta to ramify along the course of the right coronary artery.

The remaining large branch continued through the plexus to the left side caudal to the aorta. It continued along the anterior aspect of the left auricle and into the coronary groove and left longitudinal sulcus. Areas supplied by this branch included the caudal and ventral parts of the left auricle, the left side of the left ventricle and the left caudal portion of the right ventricle.

Recurrent Cardiac Nerves

Left side

Two or three small nerves arose from the left recurrent laryngeal nerve after it reached the right side of the aorta. These entered the cardiac plexus and were distributed primarily to the areas along the circumflex branch of the left coronary artery on the caudal and right portions of the heart, as described under the right caudal vagal cardiac nerves.

Right side

One or two nerves, less than half a millimeter in width, left the right recurrent laryngeal nerve as it coursed cranially around the medial side of the right subclavian

artery. It combined with a small caudal ventral cervico-thoracic nerve and passed caudally between the trachea and cranial vena cava to the cardiac plexus. Its main continuation passed between the aorta and right auricle and ramified along the right coronary artery onto the right auricle, atrium and ventricle.

PART IV. CAPRINE

GANGLIA (FIGURES 7, 8, 21, 22 AND TABLE 4)

Thoracic Ganglia

Caudal to the cervicothoracic ganglion, independent ganglia began at the second intercostal space. They lay approximately one centimeter from the midline on either side, one occupying each intercostal space. The ganglion at the left, fifth intercostal space was larger than the other thoracic ganglia and gave a large branch to the heart.

Cervicothoracic Ganglion

This ganglion, on both sides, was located on the ventrolateral surface of the longus collimuscle, ventral to the head of the first rib. It was composed of the caudal cervical and first thoracic ganglia. Rami communicantes were followed from this ganglion as far cranial as the second cervical spinal nerve via the vertebral nerve. Caudally they communicated at least to the second thoracic spinal nerve. The right ganglion was slightly longer than the left (Table 4).

Ansa Subclavia

The ansa subclavia passed around the subclavian artery from the cervicothoracic ganglion to the vertebral ganglion by means of single cranial and caudal limbs of approximately equal size. The caudal limb passed from medial to lateral

caudal to the origin of the vertebral artery, then cranial, ventral to the subclavian artery and joined the vertebral ganglion just cranial to the vertebral artery on the ventrolateral surface of the trachea on the right, or esophagus on the left. The cranial limb passed ventrally from the cervicothoracic ganglion medial to the vertebral artery and joined the vertebral ganglion also. The caudal limbs were again much longer than the cranial ones, but they were of approximately equal diameter (Table 4). About half of the caudal limb was in close contact with the vagus nerve.

Intermediate Ganglia

Independent intermediate ganglia were not grossly observed in the caprine.

Vertebral Ganglion

This ganglion was located at the cranial extremity of the limbs of the ansa subclavia just cranial to the costo-cervico-vertebral artery and ventrolateral to the esophagus on the left, and trachea on the right. Generally it was quite small. In one case it was indistinguishable from the middle cervical ganglion. In another it was located in close apposition to the cervicothoracic ganglion.

Middle Cervical Ganglion

A distinct, oblong ganglion, cranial to the vertebral ganglion, was found in the caprine, zero to three centimeters cranial to the vertebral ganglion on the sympathetic trunk (Figures 7 and 8). In all cases it was longer than the vertebral ganglion. Direct rami communicantes could not be traced to the spinal nerves.

Cranial Cervical Ganglion

I was able to retain one goat head. In this specimen the cranial cervical ganglion measured eight millimeters long by three centimeters in diameter. It lay ventral to the tympanic bulla, anterior to the inferior ganglion of the vagus nerve, not intimately fused to the latter.

Vagosympathetic Trunk

Although separable, the vagus and sympathetic trunks were found in a common connective tissue sheath from the nodose and cranial cervical ganglia to near the vertebral ganglion. Communicating rami were present between these trunks throughout the cervical region. No third trunk was noted accompanying these; however, in one case on the right and another on the left, a nerve left the vagus cranial to the vertebral ganglion and passed to the heart.

CARDIAC NERVES (FIGURES 7, 8, 21, 22, 32 AND TABLE 8)

Thoracic Cardiac Nerves

Left side

A large thoracic cardiac nerve, about one millimeter in width, was formed by nerves from the sympathetic trunk mainly between the fourth and sixth intercostal spaces. Twigs from the second and third thoracic ganglia sometimes also passed with these nerves. The left thoracic cardiac nerves passed ventrally along the anterior border of the hemiazygos vein, divided, and continued between this vessel and the left auricle, and between the hemiazygos vein and left pulmonary vein, to enter the coronary groove. In the groove it passed cranially along the left circumflex coronary artery to the right longitudinal sulcus, ramifying along its course onto the left atrium and ventricle into the interatrial and interventricular septa, and onto the caudal portion of the right ventricle. Small thoracic nerves passed ventrally along the intercostal arteries to supply the aorta.

Right side

Although small nerves arose from the right sympathetic trunk from the second thoracic ganglion caudally, I could not demonstrate any passing to the heart. Instead, they supplied the esophagus or aorta. Some passed along the azygos vein.

Cervicothoracic Cardiac Nerves

Left side

Cranial cervicothoracic cardiac nerves None were observed grossly in the caprine.

Caudal cervicothoracic cardiac nerves Two caudal ventral cervicothoracic cardiac nerves generally left the left cervicothoracic ganglion and passed to the heart. Both originated from the caudal limb of the ansa subclavia. One arose from the proximal third of this limb and passed ventrally, cranial to the former. Cranial to the subclavian artery it joined the middle cervical cardiac nerve and passed with this nerve to the heart. The more caudal nerve left the caudal limb of the ansa subclavia near its junction with the vagus nerve. It joined the middle cervical cardiac nerve approximately one to two centimeters caudally, and passed to the heart. The main areas of distribution of this trunk included the aorta, pulmonary artery, and cardiac plexus, and along the coronary arteries. Further, details will be given with the middle cervical cardiac nerve, since it generally contributed the larger part of the combined trunk.

Right side

Two right cervicothoracic cardiac nerves were sometimes present.

Cranial cervicothoracic cardiac nerves A single

cranial cervicothoracic cardiac nerve arose from the proximal third of the cranial limb of the ansa subclavia. It passed caudoventrally, medial to the caudal limb of the ansa subclavia, and on either side of the vagus nerve. Medial to the caudal limb of the ansa subclavia it joined both the vertebral cardiac nerve and the middle cervical cardiac nerve. These trunks combined, and joined the large trunk formed by the caudal vagal cardiac nerves and the right recurrent cardiac nerve, and all passed as one trunk along the brachiocephalic artery and between the cranial vena cava and aorta to the cardiac plexus. In one case the nerve passed independently to the heart but supplied the same areas as described for the combined trunks. A main branch of this combined trunk continued through the right side of the plexus and passed between the cranial and caudal venae cavae to ramify on the lateral wall of the right atrium. Another branch continued caudally, dorsal to the right pulmonary veins, then ventrally around these to pass again cranially into the area between the venae cavae or between the caudal vena cava and the left atrium into the coronary groove. Several communications between the left recurrent laryngeal nerve and this trunk were noted. Another main branch continued through the cardiac plexus, caudal to the aorta, to the left side where it ramified along the left longitudinal sulcus, and also cranially along the course of the right coronary artery.

Caudal cervicothoracic cardiac nerve The second nerve from the right cervicothoracic ganglion also joined the combined trunk just described. After leaving the proximal third of the caudal limb of the ansa subclavia this nerve passed caudoventrally and joined the main, combined, right heart nerve. In one case this nerve passed independently to the heart, but supplied the same areas as described for the combined trunk.

Intermediate Cardiac Nerves

No intermediate cardiac nerves were noted on either side.

Vertebral Cardiac Nerves

Left side

Small twigs from the vertebral ganglion followed the caudal limb of the ansa subclavia ventrally to the subclavian artery, and joined the caudal left cervicothoracic nerve and middle cervical cardiac nerve. This trunk supplied the aorta, pulmonary artery, and cardiac plexus. Main continuations through the cardiac plexus continued along the right coronary artery as well as along the branches of the left coronary artery on both sides of the heart, as described with the left middle cervical cardiac nerves.

Right side

No individual vertebral cardiac nerves were noted in four

specimens, however, in one, a vertebral cardiac nerve passed directly caudal from the vertebral ganglion to join the cranial cervicothoracic cardiac nerve. These then joined the large right cardiac nerve trunk, passing to the lateral wall of the right atrium, the left longitudinal sulcus and along the right coronary artery.

Middle Cervical Cardiac Nerves

Left side

One or two nerves arose from the ventral surface of the left middle cervical ganglion and passed caudally, ventral to the subclavian artery. It was joined by both left caudal cervicothoracic cardiac nerves and the combined trunk passed caudally along the brachiocephalic trunk, over the left lateral face of the aorta, sent branches to it and the pulmonary artery, and entered the cardiac plexus. Main branches through the plexus could be followed between the left atrium and the hemiazygos vein to the coronary groove. They then passed cranially toward the right longitudinal sulcus, ramifying on the left ventricular wall, ventrum of the left atrium, interatrial and interventricular septa, and the caudal portion of the right ventricle. Other branches followed through the plexus, passed along the left longitudinal sulcus, supplying the left auricle and right and left ventricles, or followed the right coronary artery to supply the right ventricle and auricle.

Right side

Two nerves arose from the ventral surface of the middle cervical ganglion and passed caudally, uniting after approximately one or two centimeters. The trunk formed, passed dorsal to the subclavian artery, medial to the ansa subclavia, and joined the right recurrent cardiac nerve. These two nerves, together with the caudal vagal, vertebral, and cervicothoracic cardiac nerves, formed a large common trunk which passed to the cardiac plexus. One main continuation of this common trunk passed to the right atrial wall between the venae cavae or between the caudal vena cava and the left atrium. Another coursed to the left, caudal to the aorta, and continued along the right coronary artery or down the left longitudinal sulcus. A third nerve sometimes arose from the cranial ventral border of the middle cervical ganglion and joined the right cranial vagal cardiac nerve. This combined trunk supplied the same areas just described.

Cranial Cardiac Nerves

Left side

In two cases a separate cranial vagal cardiac nerve could be traced as far cranial as the level of the sixth cervical vertebra. No cardiac nerves arose from the sympathetic trunk cranial to the middle cervical ganglion.

Right side

The only separate cardiac nerves cranial to the origin of the right recurrent laryngeal nerve were single cranial vagal cardiac nerves seen in two specimens. No cardiac nerves arose from the sympathetic trunk cranial to the middle cervical ganglion.

Cranial Vagal Cardiac Nerve

Left side

In two cases a left cranial vagal cardiac nerve could be traced cranially to about the level of the sixth cervical vertebra. In both cases the nerve passed caudally from this area accompanying the left vagus nerve. Just caudal to the left subclavian artery, in one specimen, the cranial vagal cardiac nerve joined the left common trunk of the sympathetic heart nerves and accompanied them to the aorta, pulmonary artery, cardiac plexus, and other areas previously described. In the other specimen the cranial vagal cardiac nerve left the vagus nerve half-way between the subclavian artery and the heart, passing separately to the aorta, pulmonary artery and cardiac plexus.

Two additional left cranial vagal cardiac nerves arose consistently between the subclavian artery and the left recurrent laryngeal nerve. They usually passed directly to the dorsolateral surface of the aorta and to the cardiac plexus. However, they sometimes sent fibers to the large

combined left cardiac nerve, thus extending along the circumflex branch of the left coronary artery to the dorsum of the left auricle, ventrum of the left atrium, caudal and right portions of the right ventricle, interatrial and inter-ventricular septa, and the right caudal portion of the right ventricle; along the circumflex branch of the left coronary artery on the left side to the ventrum of the left auricle and to the right and left ventricles on the left side; and along the right coronary artery to the ventrum of the right auricle and to the right ventricle.

Right side

In two specimens right cranial vagal cardiac nerves were found. One arose from the vagus, approximately one centimeter cranial to the middle cervical ganglion; the other just before the origin of the recurrent laryngeal nerve. The more cranially originating single nerve was joined by the middle cervical cardiac nerves. This trunk passed caudally, ventral to the subclavian artery, passed along the brachiocephalic artery, between the cranial vena cava and aorta, and entered the cardiac plexus. From the plexus its branches passed between the cranial and caudal venae cavae to the right atrial wall, to the left longitudinal sulcus, and along the right coronary artery. In the other case of a cranial vagal cardiac nerve, this nerve had the same course and destination as the previously described nerve, but did not

receive sympathetic fibers before reaching the heart. In the remaining three specimens no cranial vagal cardiac nerves were found.

Caudal Vagal Cardiac Nerves

Left side

Several nerves originated from the left vagus between the origin of the left recurrent laryngeal nerve and the division of the vagus nerve into a dorsal and ventral esophageal trunk. The majority of these passed to the trachea or esophagus.

One left caudal vagal cardiac nerve joined a left recurrent cardiac nerve passing caudoventrally. This trunk passed both between the hemiazygos vein and left atrium; or between the left atrium and caudal vena cava to the coronary groove. There it passed cranially, ramifying along the course of the left circumflex coronary artery in the area of the coronary sinus.

Other fine left caudal vagal cardiac nerves sometimes reached the cardiac plexus, but I could trace them no further.

Right side

In addition to fine right caudal vagal cardiac nerves, which at the caudal limit of right subclavian artery joined the large combined cardiac nerve on the right side, two additional right caudal vagal cardiac nerves were noted. These two arose from the right vagus, two to four centimeters

caudal to the right subclavian artery. They passed caudo-ventrally, sent twigs to the large combined right cardiac nerve, and continued between the cranial vena cava and aorta to the cardiac plexus. Branches could be traced ventrally on either side of the caudal vena cava to the right atrium and coronary groove. Other branches passed through the cardiac plexus to the left side, ramifying along the left longitudinal sulcus or the right coronary artery.

Recurrent Cardiac Nerves

Left side

A left recurrent cardiac nerve joined a left caudal vagal cardiac nerve and passed to the coronary groove ramifying along its course into the right side of the left ventricle and atrium, into the interatrial and interventricular septa and onto the right caudal portion of the right ventricle, as already described. Other fine left recurrent cardiac nerves communicated with the large combined right cardiac nerve trunk and with the cardiac plexus.

Right side

Right recurrent cardiac nerves, leaving the right recurrent laryngeal nerve near its origin, combined and joined with the other sympathetic cardiac nerves to form a common cardiac nerve trunk. This passed caudally along the brachiocephalic artery, between the cranial vena cava and

aorta, and entered the cardiac plexus. Branches could be traced through the plexus to the left side caudal to the aorta. They ramified along the left longitudinal sulcus onto the right and left ventricles, or passed cranially between the aorta and pulmonary artery, continued along the right coronary artery, and ramified onto the right ventricle and ventrum of the right auricle.

PART V. PORCINE

GANGLIA (FIGURES 10, 11, 23, 24 AND TABLE 5)

Thoracic Ganglia

Independent thoracic ganglia extended from the first or second thoracic intercostal space caudally. One ganglion was located in each space and each measured approximately three millimeters by two millimeters by two millimeters. Caudal to the longus collimuscle, the thoracic sympathetic trunk maintained a close relationship to the junction of the head of the ribs with the thoracic vertebrae. More cranially, along the longus collimuscle, it ascended from an almost dorsal position to a ventral position at the cervicothoracic ganglion. Throughout its length the thoracic sympathetic trunk maintained approximately a 15 millimeter paramedian position. In the area bounded by the descending aorta, pulmonary artery and vena hemiazygos there was found another ganglion which may be considered a thoracic ganglion. It received nerves from the cervicothoracic ganglion as well as the thoracic sympathetic trunk more caudally.

Cervicothoracic Ganglion

In the porcine this ganglion extended from just cranial to the first rib to the first intercostal space on the ventrolateral surface of the longus collimuscle. On the left it was partially divided by the vertebral artery which

traverses its middle. This artery did not divide the ganglion into the caudal cervical and thoracic divisions, however.

In two cases on the left side and in three on the right, a distinctly separate ganglion was located in the first intercostal space. Grossly, this investigator was unable to determine if this resulted in a complete separation of the caudal cervical ganglion from the thoracic ganglia. In the remainder of the specimens the caudal cervical ganglion and first thoracic ganglion united to form the cervicothoracic ganglion.

Additionally, on the left side, both limbs of the ansa subclavia were associated with this ganglion, lending support to the inclusion of the vertebral ganglion in the cervicothoracic ganglion.

Rami communicantes extend caudally from the cervicothoracic ganglion to at least the first thoracic spinal nerve. Cranially, via the vertebral nerve, they extended as far as the second cervical spinal nerve.

Ansa Subclavia

On the right side the caudal limb of the ansa subclavia from the cervicothoracic ganglion passed ventral and medial to the costocervical artery, continued caudally then laterally around the subclavian artery, and ascended anterior

to the vertebral artery to join the vertebral ganglion. The cranial limb on the right side was considerably shorter and thicker than the caudal limb. It extended medially to the vertebral artery from the cervicothoracic ganglion, and ventrally and cranially to reach the vertebral ganglion.

On the left side, in four of the five specimens, the vertebral ganglion was joined with the cervicothoracic ganglion and the ansa subclavia and, therefore, appeared to complete a circle with itself. In the fifth specimen no ansa subclavia was identifiable. The portion of the caudal limb cranial to the subclavian artery was approximately the same width as the portion caudal to the artery. Both limbs were very thin and could easily escape casual observation. In one case, the caudal part of the caudal limb of the ansa subclavia was double.

Intermediate Ganglia

A ganglion was located on both sides as the ansa subclavia approximated the caudoventral aspect of the subclavian artery. Their size varied only slightly between sides and between specimens (Figures 10, 11, 23, 24).

Vertebral Ganglion

This ganglion in the porcine was incorporated into the cervicothoracic ganglion on the left side. On the right side, however, it remained independent, lying just cranial

to the vertebral artery on the lateral face of the trachea, approximately five millimeters dorsal to the right vagus nerve. It was quite large (Table 5).

Middle Cervical Ganglion

In two specimens, this small ganglion was located on the sympathetic chain cranial to the cervicothoracic ganglion. It was not connected to the ansa subclavia.

Cranial Cervical Ganglion

In the pig this ganglion lay slightly more ventral than in the other species. It was located medial to the paramastoid process of the occipital bone, ventral to the tympanic bulla, about one centimeter ventral to the inferior ganglion of the vagus. In a specimen of about forty pounds, it measured about ten millimeters by four millimeters by three millimeters.

Vagosympathetic Trunk

The vagus nerve and sympathetic trunk were held in a loose association in a common connective tissue sheath, from the cranial cervical ganglion and inferior ganglion of the vagus to the area of the seventh cervical vertebra. No independent third trunk arose from either trunk in the cranial two thirds of the cervical course, however, in the caudal third, on the left side, one or two nerves arose from

the vagus nerve and accompanied the vagosympathetic trunk towards the heart.

CARDIAC NERVES (FIGURES 10, 11, 23, 24, 33 AND TABLE 8)

Thoracic Cardiac Nerves

Left side

Two or three thoracic cardiac nerves, less than one half millimeter in width, arose from the first and second thoracic ganglia and passed to the intermediate ganglion. Branches from this ganglion were then detached to the cardiac ganglion of the intervascular triangle, located between the vena hemiazygos, aorta, and pulmonary artery. Here they joined the thoracic cardiac nerves from the fourth, fifth and sixth and occasionally the seventh thoracic intercostal spaces, and passed to the heart. From their origin, the fifth, sixth and seventh thoracic cardiac nerves passed ventrally on the intercostal veins to the vena hemiazygos, and continued ventrally on this vessel to join this ganglion. The fourth thoracic cardiac nerves passed ventrally and also joined this cardiac ganglion. A few twigs from these nerves sometimes by-passed the ganglion. Some fibers entered the cardiac plexus, however, most continued along the vena hemiazygos, between the pulmonary veins and the left auricle, and joined the left circumflex coronary artery in the coronary groove. Twigs continued cranially radiating onto the ventrum of the left

atrium and over the left ventricle, into the interventricular and interatrial septa, and the caudal portion of the right ventricle. Other twigs supplied the caudodorsal portion of the left auricle as the main trunk passed this area.

Right side

Thoracic cardiac nerves from the first and second thoracic intercostal spaces coursed ventrocranially and entered the right intermediate ganglion. Together with the right vertebral and cervicothoracic cardiac nerves, these nerves left this ganglion and passed to the heart, as described with the latter nerves. Branches followed through the cardiac plexus and along each coronary artery from near their origins. They supplied the cranial and ventral portions of the atria, the right ventricle in common with the right coronary artery, the right and left ventricles from the left longitudinal sulcus, and the left side of the left ventricle from the coronary groove.

Nerves from the right sympathetic chain caudal to the second thoracic intercostal space could be traced to the aorta, but the author was unable to demonstrate branches to the heart.

Cervicothoracic Cardiac Nerves

Left side

Cranial cervicothoracic cardiac nerves From one to four cranial cervicothoracic cardiac nerves generally arose

from the ventral surface of the cranial portion of the cervicothoracic ganglion. Three passed caudally, ventral to the subclavian artery, where one nerve joined the left intermediate ganglion. Some fibers, or a separate nerve, sometimes bypassed this ganglion and two or three centimeters caudal to the intermediate ganglion rejoined the trunk which passed through it. Together, these nerves coursed caudally, lateral to the aorta, and mainly joined the cardiac ganglion of the intravascular triangle located between the aorta, pulmonary artery and vena hemiazygos. A few fibers bypassed the ganglion and joined its postganglionic fibers or thoracic cardiac nerves which also bypassed the ganglion. Together these nerves entered the coronary groove, caudally, with the vena hemiazygos. They continued to the right side and cranially with the circumflex branch of the left coronary artery. Twigs were given off to the caudal dorsal part of the left auricle, the ventral portion of the left atrium, the right side of the left ventricle, the interatrial and interventricular septa, and along the right longitudinal sulcus to both ventricles.

Another nerve from this area of the cervicothoracic ganglion did not go either to the intermediate ganglion or to the cardiac ganglion of the left intravascular triangle. It joined the cranial left vagal cardiac nerve and passed ventral to the subclavian artery, across the left lateral

face of the aorta, and around its caudal border, and entered the cardiac plexus. Branches of this nerve supplied the left side of the aorta, particularly near the ligamentum arteriosum.

Caudal cervicothoracic cardiac nerves One caudal cervicothoracic cardiac nerve left the middle of the caudal border of the left cervicothoracic ganglion. It passed caudally on the medial side of the left subclavian artery. It continued caudally on the right side of the aorta and entered the cardiac plexus. It sometimes joined the left recurrent laryngeal nerve cranial to the aorta and possibly reached the cardiac plexus by passing along this nerve caudally.

Right side

Cranial cervicothoracic cardiac nerves None were observed grossly in the porcine.

Caudal cervicothoracic cardiac nerves One or two nerves arose from the caudoventral pole of the right cervicothoracic ganglion and passed directly to the right intermediate ganglion. As is described for the right intermediate cardiac nerves, these nerves, together with the right vertebral cardiac nerves and the cervicothoracic cardiac nerves, then continued, usually, as two trunks. One passed between the right auricle and pulmonary artery, by coursing around either side of the cranial vena cava, and continued to the cranial portion of the coronary groove following the right

coronary artery. The other passed through the cardiac plexus, coursed caudal to the aorta to the left side, and ramified along the left longitudinal sulcus. The main supply of the right cervicothoracic cardiac nerves included the cranial and ventral portions of the right auricle, the right ventricle, the cranial and ventral portions of the left auricle, and the left side of the left ventricle. (Further notations will be found in the section on intermediate cardiac nerves.)

A few twigs from the right cervicothoracic cardiac nerves sometimes passed to the right vagus nerve, just caudal to the subclavian artery. These twigs accompanied the right caudal vagal and right recurrent cardiac nerves to the lateral wall of the right atrium, along the right coronary artery, and into the left longitudinal sulcus.

Intermediate Cardiac Nerves

Left side

As described under the section on the left cervicothoracic cardiac nerves, left intermediate cardiac nerve fibers accompanied the former to the cardiac ganglion of the left intervascular triangle located between the aorta, pulmonary artery and vena hemiazygos. Here they joined thoracic cardiac nerves and all passed to the heart together along the vena hemiazygos. The areas supplied included: the dorso-caudal part of the left auricle, ventrum of the left atrium, right interatrial and interventricular septa, right side of

the left ventricle, and the caudal portion of the right ventricle.

Right side

Two nerve trunks generally arose from the right intermediate ganglion and passed to the heart. These trunks were formed by the right intermediate cardiac nerves and right vertebral and cervicothoracic cardiac nerves. Together they coursed caudally on the dorsum of the cranial vena cava, or one trunk dipped ventral to the cranial vena cava into the area just anterior to the aorta. In either case, one nerve entered this area and followed the craniomedial border of the right auricle to the anterior aspect of the coronary groove. Nerve fibers followed the right coronary artery and its branches to the right ventricle. As the nerve trunk was following the border of the right atrium it also gave branches to the medial and anterior portions of this chamber.

The other trunk, passing on the dorsum of the cranial vena cava, continued between this vessel and the aorta into the cardiac plexus. Its main continuation was followed to the left side along the cranial edge of the left auricle and into the left longitudinal sulcus. In route, it sent twigs to the cranial and ventral portions of the left auricle, the part of the left ventricle on the left side, and the left caudal portion of the right ventricle.

Branches from either, or both, of these trunks also

radiated out into the lateral surface of the right atrium from between the two venae cavae.

Vertebral Cardiac Nerves

Left side

Because the left vertebral ganglion was intimately fused with the cervicothoracic ganglion, no independent nerves were discussed here. It was assumed that nerves from this ganglion passed with the left cervicothoracic nerves to the heart.

Right side

Nerves from the right vertebral ganglion passed to the left phrenic nerve, carotid artery, brachiocephalic trunk, cranial vena cava and right vagus nerve, in addition to the main trunk from the caudoventral portion of the right vertebral ganglion which joined the right intermediate ganglion. As described under the right intermediate cardiac nerves, combined trunks, composed of right vertebral, intermediate, and cervicothoracic cardiac nerves, passed from the intermediate ganglion along the right coronary artery to the right atrium and ventricle; between the venae cavae to the lateral right atrial wall; and on the left side along the left longitudinal sulcus to the left and right ventricles and left coronary groove to the left atrium and ventricle. In one specimen, one independent right vertebral nerve was noted. This coursed caudally from the right vertebral ganglion,

ventral to the subclavian artery, along the dorsum of the cranial vena cava, and entered the cardiac plexus giving branches mainly to the area between the venae cavae.

Middle Cervical Cardiac Nerves

Left side

In two of the five cases, a middle cervical ganglion was present. One of these had no caudal connections, except to the cervicothoracic ganglion. The other had two small cardiac nerves which arose from its ventral border and passed caudally, ventral to the subclavian artery. The nerves passed on either side of the aorta and ramified on the cardiac plexus.

Right side

No independent middle cervical cardiac nerves were demonstrated on this side.

Cranial Cardiac Nerves

No cranial cardiac nerves were demonstrated on either side.

Cranial Vagal Cardiac Nerves

Left side

Two cranial vagal cardiac nerves arose from the left vagus about two or three centimeters cranial to the left subclavian artery. Each nerve passed ventral to the subclavian

artery, over the left lateral surface of the aorta, ventrally between the aorta and pulmonary artery just cranial to the ligamentum arteriosum, and into the cardiac plexus.

One, left cranioventral cervicothoracic cardiac nerve joined one cranial vagal trunk along its course.

Right side

In one case a cranial vagal nerve arose from the right vagus nerve approximately two centimeters cranial to the origin of the right recurrent laryngeal nerve. It coursed caudally between the aorta and cranial vena cava to enter the cardiac plexus.

Caudal Vagal Cardiac Nerves

Left side

Generally, three to six nerves, approximately one millimeter in width, arose from the left vagus nerve, within four centimeters caudal to the origin of the left recurrent laryngeal nerve. These nerves either passed into a plexus on the dorsum of the trachea, or passed directly along the vena hemiazygos to the heart. Main branches from this plexus passed to the lungs; however, two or three branches arose from the cranial aspect of the plexus and passed, with sympathetic fibers from the cervicothoracic and thoracic ganglia, along the vena hemiazygos to the caudal and right portions of the coronary groove. Twigs passed to the caudal left auricle, right side of the left ventricle, ventral left

atrium, interatrial and interventricular septa, and along the right longitudinal sulcus, ramifying onto both ventricles.

Right side

A right caudal vagal cardiac nerve arose within two centimeters caudal to the origin of the right recurrent laryngeal nerve. It received the right recurrent cardiac nerve and twigs from the right cervicothoracic cardiac nerves, and passed caudally on the dorsum of the cranial vena cava. It gave twigs to the area between the cranial and caudal venae cavae to the right atrium and continued into the cardiac plexus. Contributions were made along the right coronary artery to the right auricle and ventricle, to the left side along the left longitudinal sulcus ramifying onto both right and left ventricles, and caudally on the left in the coronary groove sending twigs to the cranial ventral parts of the left auricle and also the left side of the left ventricle.

Another one or two right caudal vagal cardiac nerves, approximately half a millimeter in width, left the right vagus nerve just caudal to the right primary bronchus, approximately at the level of the sixth thoracic vertebra. They passed ventrally between the bronchi into the area between the caudal vena cava and the left atrium. Some continued ventrally to the coronary groove, where they ramified; others passed onto the caudal vena cava. Those which passed cranially over the caudal vena cava entered the area of the right atrium between the cavae and ramified.

In two cases, another small nerve arose from the right vagus between the two points of origin for the vagal cardiac nerves just described. In these cases, the nerve passed to the right pulmonary veins and into the cardiac plexus.

Recurrent Cardiac Nerves

Left side

A left recurrent cardiac nerve passed ventrally and laterally to join the left caudal vagal cardiac nerves descending on the vena hemiazygos to the coronary groove. Its distribution, along the course of the left circumflex coronary artery, was the same as that for the left caudal vagal cardiac nerves. After turning onto the right face of the aorta, two or three small twigs passed ventrally from the left recurrent laryngeal nerve and entered the cardiac plexus.

Right side

The right recurrent cardiac nerve left the right recurrent laryngeal nerve within five millimeters after the latter's origin. It joined fibers from the caudal vagal and right caudal cervicothoracic cardiac nerves, and together they passed caudally on the dorsum of the cranial vena cava to the cardiac plexus. Its distribution was the same as described under the right caudal vagal cardiac nerves onto the lateral wall of the right atrium, along the left longitudinal sulcus, and along the right coronary artery.

PART VI. FELINE

GANGLIA (FIGURES 11, 12, 25, 26 AND TABLE 6)

Thoracic Ganglia

Independent thoracic sympathetic chain ganglia began cranially at the third or fourth intercostal space, approximately three-quarters to one centimeter from the midline, and maintained this relationship caudally. One ganglion, approximately two millimeters craniocaudal by one millimeter dorsoventral by one millimeter mediolateral, was found at each of these interspaces.

Cervicothoracic Ganglion

This ganglion was located on the lateral face of the longus colli muscle at the level of the first intercostal space on the right, and extended between the first and second intercostal spaces on the left (Figures 11 and 12). It was composed of the caudal cervical and first two or three thoracic ganglia with rami communicantes extending caudally to at least the third thoracic spinal nerve. Cranially, I was able to demonstrate rami communicantes only to the sixth, seventh, and eighth cervical spinal nerves. Bilaterally, this ganglion averaged approximately seven millimeters craniocaudally by four to five millimeters dorsoventrally by two millimeters mediolaterally (Table 6).

Ansa Subclavia

The two limbs of the ansa subclavia pass ventrally, on either side of the subclavian artery from the cervicothoracic ganglion to the vertebral ganglion. The caudal limb was typically double. Both caudal parts passed caudal to the origin of the internal thoracic artery before passing cranially to the vertebral ganglion. Both limbs of the ansa subclavia on the left side were shorter than their corresponding homologs on the right. The posterior limbs also were proportionately longer than the anterior limbs on both sides (Table 6). The left caudal limbs lay in close apposition to the vagus nerve for approximately one centimeter of its one and one-half centimeters average total length. The right caudal limb lay in the same relationship for one and one-half centimeters of its two and one-quarter centimeters average total length. The diameter of the caudal limbs (about one millimeter) was greater than that of the cranial limb (about five-tenths of a millimeter).

Intermediate Ganglia

In three instances on the left side, a grossly visible intermediate ganglion was noted at the point where the caudal-most caudal limb of the ansa subclavia approximated the vagus nerve. In two of these instances it measured approximately one-half of a millimeter in diameter. In the third, it

measured four millimeters craniocaudal by three millimeters dorsoventrally by two millimeters mediolaterally. No ganglion was noted grossly at this location in the other seven specimens. No grossly visible counterpart was noted on the right side.

Vertebral Ganglion

This ganglion in the cat was located at the cranioventral end of the limbs of the ansa subclavia (Figures 11 and 12). On the left side it lay directly anteriomedial to the vertebral artery just dorsal to the vagus nerve. On the right side it maintained this relationship, except that it was slightly more cranial. It measured approximately three to four millimeters craniocaudally, one and one-half millimeters dorsoventrally, and one millimeter mediolaterally (Table 6). Rami communicantes were usually not demonstrated, but when present passed to the sixth cervical spinal nerve.

Middle Cervical Ganglion

No independent middle cervical ganglion was noted in the cat.

Cranial Cervical Ganglion

Lying ventromedial to the tympanic bulla this ganglion was in close apposition to the nodose ganglion. It measured approximately eight millimeters rostrocaudally, three millimeters dorsoventrally, and two millimeters mediolaterally.

Rami communicantes passed to the first and second cervical spinal nerves.

Vagosympathetic Trunk

Although separate, the vagus nerve and sympathetic trunk on each side were enclosed in a common connective tissue sheath from the nodose and cranial cervical ganglion nearly to the vertebral ganglion. Communicating twigs were present along their course. A third separate trunk arose from the left cranial cervical ganglion, together with twigs from the left anterior laryngeal and vagus nerves, and passed caudally to the heart. It lay in close apposition to, although distinctly separate from, the sympathetic trunk until it reached the ansa subclavia and then it accompanied the vagus nerve to the heart. No discretely separate nerve was noted on the right, although one nerve, of similar size (one-fourth millimeter), originated from the right vagus nerve cranial to the vertebral ganglion and passed to the heart.

CARDIAC NERVES (FIGURES 11, 12, 25, 26 AND TABLE 8)

Thoracic Cardiac Nerves

Left side

Fine nerves from the third thoracic ganglion, caudally, passed from the sympathetic chain, ventrally, along the intercostal arteries to the aorta. The left thoracic cardiac

nerves, from the third to fifth thoracic ganglia, were noted as joining the dorsal cervicothoracic cardiac nerve, thereby ultimately entering the cardiac plexus.

Right side

Although numerous fine nerves passed ventrally from the thoracic sympathetic trunk, particularly along the azygos vein, I could ascertain only three or four nerves which could reach the heart. These originated from the third and fourth thoracic ganglia, joined the right vagus nerve, and presumably passed to the right atrium with the caudal vagal cardiac nerves.

Cervicothoracic Cardiac Nerves

Left side

Typically two or three cervicothoracic cardiac nerves originated from the left cervicothoracic ganglion.

Cranial cervicothoracic cardiac nerves None were observed grossly.

Caudal cervicothoracic cardiac nerves A dorsal cervicothoracic cardiac nerve, measuring approximately twenty-five hundredths of a millimeter in diameter, arose from the caudodorsal border of the cervicothoracic ganglion. It passed caudally along the dorsolateral border of the left subclavian artery. Slightly anterior to the origin of this vessel from the aorta, this nerve joined the left ventral cervicothoracic cardiac nerve. The left ventral

cervicothoracic cardiac nerves, usually one or two in number, arose from the left cervicothoracic ganglion in common with the caudal limb of the ansa subclavia. These nerves followed this limb for a short distance then passed caudally as one trunk, approximately seventy-five hundredths of a millimeter in diameter, following the left vagus nerve towards the heart.

This trunk joined the left dorsal cervicothoracic cardiac nerve near the origin of the left subclavian artery. The combined trunk passed over the left lateral face of the aorta and ramified near the caudolateral border of the aortic arch. In this small area between the left primary bronchus, pulmonary artery, and aorta the cervicothoracic cardiac nerves were also joined by the left cranial vagal cardiac nerves.

The principal branches from this ramification passed caudally, lateral to the pulmonary artery, and coursed caudoventrally between the left auricle and left pulmonary veins. After entering the coronary groove they ramified along the course of the left circumflex coronary artery and its branches onto the right side of the left ventricle, ventrum of the left atrium, interventricular and interatrial septa, and caudal portion of the right ventricle.

The remainder of the branches from the area bounded by the primary bronchus, pulmonary artery, and aorta, passed to the aorta, pulmonary artery, left pulmonary veins, and into the cardiac plexus. Some fibers continued cranially through

the cardiac plexus between the aorta and pulmonary artery to join with the trunk formed by the right caudal vagal, right cervicothoracic, right vertebral, and right recurrent cardiac nerves. These nerves followed the right and left coronary arteries from their origin to their ramification over the right ventricle, the left cranial portion of the left ventricle and the cranial and ventral portion of the right and left auricle.

Right side

In eight of the ten cats, all the right cervicothoracic cardiac nerves passed with the caudal limb of the ansa subclavia as far as their junction with the vagus nerve, just caudal to the subclavian artery. From this point, right caudal vagal cardiac nerves, right vertebral cardiac nerves, and right recurrent cardiac nerves joined one cervicothoracic cardiac nerve and passed caudally on the ventral surface of the trachea. This trunk passed between the anterior vena cava and aorta into the cardiac plexus. The main continuation was followed to the left side of the heart to the aorta. It proceeded cranially around either side of the pulmonary artery, and then along the right and left coronary arteries into the right coronary groove, or the left coronary groove, and longitudinal sulcus, respectively. From these locations twigs passed primarily onto the right ventricular wall, but also onto the cranial and left portions of the left ventricle, and

the ventral and cranial portions of the auricles.

In two cats, two additional nerves left the right cervicothoracic ganglion and passed caudoventrally, dorsal to the vagus. Just anterior to the right apical bronchus these nerves joined with the right caudal vagal cardiac nerves and passed to the areas of the heart just described.

The remainder of the right cervicothoracic cardiac nerves, from the junction of the caudal limbs of the ansa subclavia and the vagus nerve, passed caudally with the vagus. At a point immediately anterior to the origin of the right apical bronchus, these and the caudal vagal cardiac nerves passed ventrally to the heart. They proceeded between the right branch of the pulmonary artery and the cranial venae cavae and ramified on the dorsolateral face of the right atrium. Their course onto the atrium was either between the cranial and caudal vena cava, or caudally around the caudal vena cava, from dorsal to ventral, and then ramifying anteriorly onto the right atrial wall. Twigs also passed to the cardiac plexus, right pulmonary artery, right pulmonary veins, and cranial and caudal vena cava, and some extended into the coronary groove in the area of the coronary sinus.

Intermediate Cardiac Nerves

Left side

When the intermediate ganglion was present on the left side, an intermediate cardiac nerve passed caudally from this

ganglion along the left vagus nerve, with the left ventral cervicothoracic cardiac nerves. Near the origin of the brachiocephalic artery it was joined by the dorsal cervicothoracic cardiac nerve. The intermediate cardiac nerve passed to the coronary groove along the left circumflex coronary artery together with the left cranial vagal cardiac nerves, the left dorsal and ventral cervicothoracic cardiac nerves, and the left vertebral cardiac nerves. They supplied the right and caudal parts of the left ventricle, ventrum of the left atrium, interventricular and interatrial septa, and caudal portion of the right ventricle. Other branches passed to the aorta, pulmonary artery, left pulmonary veins or cardiac plexus.

Right side

No right intermediate cardiac nerves were identified.

Vertebral Cardiac Nerves

Left side

Two to four nerves, approximately two millimeters each, arose from the left vertebral ganglion along its ventral border. After passing approximately five millimeters caudally they joined and continued as one trunk in close apposition to the left vagus nerve. This trunk joined the common trunk of the left cervicothoracic cardiac nerves and sent fibers to the right and caudal walls of the left ventricle, ventrum of the left atrium, interventricular and interatrial septa,

caudal portion of the right ventricle, aorta, pulmonary artery, left pulmonary veins, and cardiac plexus. Twigs sometimes also indirectly reached the left longitudinal sulcus and along the right coronary artery.

Nerves from the left vertebral ganglion also sometimes joined the cranial cardiac nerve, as it passed the vertebral ganglion, and proceed between the brachiocephalic artery and left subclavian artery to supply the aorta.

Right side

Three or four nerves, each about two millimeters wide, left the right vertebral ganglion and joined the right vagus nerve. They joined both of the cervicothoracic cardiac nerves to the heart. Thus, their area of supply included the dorso-lateral face of the right atrium, the pulmonary artery, right pulmonary veins, cardiac plexus, the anterior halves of the right and left ventricles, and the cranial and ventral portions of both auricles.

Middle Cardiac Nerves

No middle cervical cardiac nerves were identified.

Cranial Cardiac Nerves

Left side

An independent, five-tenths of a millimeter, nerve, formed from contributions of the cranial cervical ganglion, vagus nerve and cranial laryngeal nerves, passed caudally

towards the heart in close apposition to the sympathetic trunk. At the level of the ansa subclavia it continued with the left vagus nerve along the left subclavian artery and passed between this and the brachiocephalic trunk to ramify on the aorta.

Right side

I could not demonstrate a separate nerve on the right side to correspond to that described on the left. The only branch cranial to the right subclavian artery was a cranial vagal cardiac nerve which originated about one centimeter cranial to this artery.

Cranial Vagal Cardiac Nerves

Left side

In addition to the vagal fibers passing in the cranial cardiac nerve, cranial vagal cardiac nerves arose from the intimately intertwined association with the sympathetic nerves at the junction of the aorta, pulmonary artery, and left bronchus. These nerves followed the sympathetic nerves, previously mentioned, into the cardiac plexus, to the aorta and pulmonary artery, to the caudal and right aspects of the left ventricle, ventrum of the left atrium, interventricular and interatrial septa, and caudal portion of the right ventricle. Twigs sometimes indirectly reached the left longitudinal sulcus and along the course of the right coronary artery, also.

Right side

One nerve left the right vagus nerve cranial to the origin of the right recurrent laryngeal nerve and passed ventrally with the right recurrent cardiac nerves, right vertebral cardiac nerves, right cervicothoracic cardiac nerves, and right caudal vagal cardiac nerves. These nerves passed between the aorta and cranial vena cava and ramified along the coronary arteries onto the right ventricle, left cranial part of the left ventricle, and the cranial and ventral portions of the auricles.

Caudal Vagal Cardiac Nerves

Left side

Two or three nerves arose from the left vagus nerve, about five millimeters caudal to the origin of the left recurrent laryngeal nerve, and passed cranio-ventrally to accompany sympathetic and cranial vagal nerves between the left pulmonary veins and the left auricle into the coronary groove. From this groove the nerves ramified onto the right and caudal left ventricular wall, ventrum of the left atrium, interventricular septum, interatrial septum, and caudal portion of the right ventricle. Fine twigs sometimes also accompanied sympathetic fibers to the cardiac plexus, to the left longitudinal sulcus, and along the right coronary artery.

Right side

From the intimate association of the vagus with the sympathetic nerves as the caudal limb of the ansa subclavia approximates the vagus, caudal vagal cardiac nerves combined with the recurrent cardiac nerves and the sympathetic cardiac nerves and passed caudoventrally, ventral to the trachea. Their distribution, as previously described, included the right ventricle, the left and cranial parts of the left ventricle, and the cranial and ventral portions of the auricles. Two or three other caudal vagal cardiac nerves arose, just anterior to the right apical bronchus, and accompanied the cervicothoracic cardiac nerves ventrally to the dorsolateral portion of the right atrium, sent twigs to the cardiac plexus, right pulmonary arteries, right pulmonary veins and cranial and caudal vena cava, and sometimes extended into the coronary groove in the area of the coronary sinus.

Recurrent Cardiac Nerves

Left side

I was unable to trace left recurrent cardiac nerves to the heart; however, small twigs ramified on the caudal border to the aorta.

Right side

One or two fine right recurrent nerves joined the caudoventrally passing trunk of the sympathetic and vagal nerves,

which originated near the caudal limb of the ansa subclavia. This trunk, as previously described, passed between the cranial vena cava and the aorta, from right to left around the caudal aspect of the aorta, and followed the coronary arteries into the coronary grooves and left longitudinal sulcus. The area thus supplied included the right ventricle, the left cranial part of the left ventricle, and the cranial and ventral portions of the auricles.

PART VII. CANINE

GANGLIA (FIGURES 13, 14, 27, 28 AND TABLE 7)

Thoracic Ganglia

Independent thoracic ganglia were present in each intercostal space caudal to and including the third or fourth intercostal space. They were quite uniform in size and measured about three millimeters craniocaudal by two millimeters dorsoventral by one millimeter mediolateral. Cranially the thoracic sympathetic chain lay on the dorsolateral border of the longus colli muscle. Caudally it lay along the junctions of the ribs with the vertebrae and then on the ventrolateral surface of the quadratus lumborum muscle.

Cervicothoracic Ganglion

The caudal cervical and first two or three thoracic ganglia fused to form the cervicothoracic ganglion in the dog. This generally lay on the lateral surface of the longus colli muscle, extending from the cranial border of the first intercostal space to the caudal border of the second intercostal space. In the thoracic region rami communicantes were present between this ganglion and at least the first four thoracic spinal nerves. Cranially I was able to demonstrate rami, extending via the vertebral nerve, as far cranial as the second cervical spinal nerve. The cervicothoracic ganglia were approximately the same size on either side (Table 7).

Ansa Subclavia

Single cranial and caudal limbs extended from the cervicothoracic ganglion around the subclavian artery to the vertebral ganglion. On the left side the limbs were of approximately equal length. The right limbs were longer than the left, due to the more cranial position of the vertebral ganglion and a tendency for the cervicothoracic ganglion, on this side, to be slightly more caudal than the left one. The caudal limb on the right was also proportionately longer than the cranial one (Table 7). As in other species, the caudal limbs passed from medial to lateral, caudal to the subclavian artery, and continued cranially to join the vertebral ganglion. The cranial limb passed cranioventrally from the cervicothoracic ganglion, medial to the vertebral artery, and joined the vertebral ganglion.

Intermediate Ganglia

Independent intermediate ganglia were not grossly observed in the canine.

Vertebral Ganglion

In the dog this ganglion was located just cranial to the origin of the vertebral artery at the cranial extremity of the limbs of the ansa subclavia. It lay on the dorsolateral surface of the carotid artery and was intimately fused to

the vagus nerve, particularly on the right side. It was slightly larger on the left side (Table 7).

Middle Cervical Ganglion

No independent middle cervical ganglia were noted grossly in the canine.

Cranial Cervical Ganglion

This ganglion lay directly caudoventral to the tympanic bulla in a close relationship to the inferior ganglion of the vagus nerve. The latter ganglion lay lateral to the cranial cervical ganglion and extended slightly more ventral. The cranial cervical ganglion measured approximately thirteen centimeters in length and four centimeters in diameter.

Vagosympathetic Trunk

The vagus nerve and sympathetic trunk were enclosed in a common connective tissue sheath, from the inferior ganglion of the vagus and cranial cervical ganglion to the vertebral ganglion. They were closely fused and were not easily separated, due to intermingling fibers. No third independent trunk from the cranial area accompanied the vagosympathetic trunk to the thorax.

The width of the vagosympathetic trunk varied between three and five millimeters.

CARDIAC NERVES (FIGURES 13, 14, 27, 28, 35 AND TABLE 8)

Thoracic Cardiac Nerves

Left side

In the majority of cases, morphologically, no thoracic nerves were traced directly to the heart from the left thoracic ganglia; however, nerves were followed to the aorta from these ganglia in all cases. In two specimens nerves from the third to seventh thoracic ganglia passed caudally to the seventh intercostal space where they joined a branch from the eighth thoracic ganglion. The combined trunk continued with the bronchoesophageal artery cranioventral between the aorta and esophagus. Fine twigs sometimes continued over the left primary bronchus and entered the cardiac plexus. In one specimen a cervicothoracic cardiac nerve joined the thoracic cardiac nerves. In this case the third thoracic cardiac nerve and the cervicothoracic cardiac nerve joined on the fourth intercostal artery, continued ventrally on this vessel, and then passed over the left lateral surface of the aorta. It continued medially to the bronchoesophageal artery where it joined the other thoracic cardiac nerves and passed with them to the cardiac plexus.

Right side

I was able to grossly demonstrate right thoracic cardiac nerves in only one of the dogs. In this case nerves arose

from the third, fourth and fifth right thoracic ganglia and followed the vena azygos ventrally. In addition to branches to the right bronchi and pulmonary vessels, one trunk continued along the dorsum of the cranial vena cava to the right atrial wall. Here it ramified between the cavae onto the right atrium.

In the additional specimens right thoracic nerves were followed grossly to the great vessels but not to the heart itself.

Cervicothoracic Cardiac Nerves

Left side

Cranial cervicothoracic cardiac nerves One nerve
arose from the cranial limb of the ansa subclavia and joined the left craniomedial vertebral cardiac nerve, passing with it to the heart along the coronary arteries as described for the latter nerve.

Caudal cervicothoracic cardiac nerves Two to six
caudal cervicothoracic cardiac nerves arose, from the caudal portion of the cervicothoracic ganglion and the caudal limb of the ansa subclavia, and passed to the heart and great vessels. One, previously described, sometimes joined the thoracic cardiac nerves which entered the cardiac plexus. The others followed caudally on the brachiocephalic artery and over the left lateral face of the aorta, supplying these vessels, the esophagus, and small twigs to the cardiac plexus.

Right side

Cranial cervicothoracic cardiac nerves None were observed in the canine.

Caudal cervicothoracic cardiac nerves Right caudal cervicothoracic cardiac nerves followed the caudal limb of the ansa subclavia to its ventral limit where they branched and joined the right vertebral, vagal and recurrent cardiac nerves, as well as passing directly to the cranial vena cava and extending to the cardiac plexus. Those branches which joined the other right cardiac nerves extended through the cardiac plexus and along both coronary arteries. This is more completely explained under the section on the right vertebral cardiac nerves.

Only in one specimen was a cervicothoracic cardiac nerve seen as passing directly from the right cervicothoracic ganglion to the heart. In this case, a large, one millimeter nerve left the caudoventral border of the ganglion and coursed caudoventrally between the cranial vena cava and the aorta to the cardiac plexus. Twigs were also followed directly to the dorsolateral surface of the cranial vena cava, the adjacent right atrium, and the pulmonary vessels on the right.

Intermediate Cardiac Nerves

No intermediate cardiac nerves were observed in the canine.

Vertebral Cardiac Nerves

Left side

Generally, four main cardiac nerves originated from the left vertebral ganglion. These, by location, were found to be constant in these specimens as the caudolateral, caudomedial, craniomedial and dorsal vertebral cardiac nerves.

Left caudolateral vertebral cardiac nerve From the left vertebral ganglion this nerve followed the left vagus caudally and exchanged branches with it. After coursing across the left lateral surface of the aorta and pulmonary trunk its main branch continued between the left auricle and left pulmonary veins to the coronary groove. Twigs sometimes extended to the cardiac plexus. Another branch followed dorsally onto the left branch of the pulmonary artery. One or two small twigs left this branch and passed to the cardiac plexus. Others ramified on the aorta and pulmonary artery. The main branch of the caudolateral vertebral cardiac nerve, in its course to the coronary groove, gave nerve fibers to the caudodorsal part of the left auricle. After reaching the coronary groove this nerve followed the circumflex branch of the left coronary artery. Along this course it gave twigs to the ventrum of the left atrium, the right side of the left ventricle, the interatrial and interventricular septa and the caudal portion of the right ventricle from the right longitudinal sulcus.

Caudomedial vertebral cardiac nerve This nerve coursed caudally over the left lateral face of the aorta to the area of the ligamentum arteriosum. Here it ramified into the aorta and pulmonary artery around this structure. One branch was followed caudally, ventral to the ligamentum arteriosum, between the aorta and pulmonary artery and into the cardiac plexus, where it ramified. A twig was followed to the origin of the right and left coronary arteries and then along their course with the more important, combined, right cardiac nerves.

Craniomedial vertebral cardiac nerve This nerve passed caudally, ventral to the esophagus and trachea, continued between the left subclavian artery and brachiocephalic trunk to the right side, after combining with the left dorsal vertebral cardiac nerve, and ramified in the cardiac plexus. The largest branch was followed through the cardiac plexus and back to the left side caudal to the aorta. It continued between the aorta and pulmonary trunk, just caudal to the ligamentum arteriosum, and ventrally into the coronary groove and left longitudinal sulcus, where it ramified onto the left and cranial sides of the right and left ventricles. Before reaching the plexus, two branches, which passed elsewhere, arose from this nerve. One arose near the origin of the brachiocephalic artery and continued caudally, lateral to this vessel and the aorta, to join

the caudolateral vertebral cardiac nerve which it accompanied along the course of the circumflex branch of the left coronary artery. A second branch, originating just cranial to the origin of the brachiocephalic artery and left subclavian artery, ramified in the area between the origin of these vessels from the aorta.

Dorsal vertebral cardiac nerves One or two dorsal vertebral cardiac nerves assumed the same pathway to the heart as the craniomedial vertebral cardiac nerve and terminated also in the cardiac plexus. Often they combined with the latter nerve before reaching the plexus. A branch from this nerve sometimes joined the caudomedial vertebral cardiac nerve.

Right side

In addition to short communications between the right vertebral ganglion and the right vagus and right recurrent laryngeal nerves, one or two independent vertebral cardiac nerves arose from the caudal pole of this ganglion. One passed ventrally between the subclavian artery and right common carotid artery, sending twigs to both, and continued caudally between the cranial vena cava and aorta. Here it sent twigs to the cardiac plexus, but its main trunk joined the more dorsally running right vertebral cardiac nerve. The more dorsal nerve followed the right vagus from the vertebral ganglion to a point just caudal to the right subclavian artery. Just caudal to the right subclavian artery

it was also joined by the right recurrent, right cervicothoracic and caudal vagal cardiac nerves. In one case, the right dorsal vertebral cardiac nerve did not follow the vagus, but passed to the area just caudal to the right subclavian artery by passing medial to this vessel. It then resumed the course, as in the other specimens. The nerves entered the cardiac plexus from between the cranial vena cava and aorta where they were joined by the other right vertebral cardiac nerve. The main trunk of the combined right cardiac nerves continued through the cardiac plexus and around the caudal border of the aorta to the left side, where it joined the origins and passed along the courses of the coronary arteries. It, therefore, contributed to the innervation of the right ventral portion of the right atrium, from along the right coronary artery, and to the left portion of the right and left ventricles and ventrum of the left auricle, from along the descending and circumflex branches of the left coronary artery. A branch of the right, more dorsal vertebral cardiac nerve was also sent to the right atrium between the vena cava before this nerve reached the cardiac plexus. It radiated on the right atrium towards the terminal sulcus.

When only one right vertebral cardiac nerve was present, it assumed the same area of supply as when two were present.

Middle Cervical Cardiac Nerves

No independent middle cervical cardiac nerves were noted in the dog.

Cranial Cardiac Nerves

No nerve trunk, separate from the vagosympathetic trunk, was noted as passing from the cranial region to the heart.

Cranial Vagal Cardiac Nerves

Left side

Small twigs from the vagus nerve, just cranial to or in the direct vicinity of the vertebral ganglion, joined the left vertebral cardiac nerves. The largest branch, from cranial to the ganglion, passed with the caudomedial vertebral nerve, which also received two or three small nerves from the left vagus nerve between the left vertebral ganglion and the origin of the left recurrent laryngeal nerve. One nerve, from this more distal area, commonly communicated with the caudolateral vertebral cardiac nerve also. This cranial vagal cardiac nerve passed with the left vertebral and left cervicothoracic cardiac nerves to their destinations. This included the caudal aspect of the left auricle, the right side of the left ventricle and ventrum of the left atrium, interatrial and interventricular septa, and right caudal part of the right ventricle with the left caudolateral vertebral cardiac nerve. With the left dorsal vertebral, left caudomedial and cervicothoracic cardiac nerves it passed to the cardiac plexus, with main branches to the left side of the right and left ventricles, right side of the right ventricles, and ventrum of the right auricle from along the course of

the coronary arteries.

Right side

Near the origin of the right vertebral cardiac nerves small right cranial vagal cardiac nerves joined the former and accompanied them to their destinations along the coronary arteries or between the venae cavae onto the right atrium. Further description of this course can be found under the right vertebral cardiac nerves.

Caudal Vagal Cardiac Nerves

Left side

Zero to two left caudal vagal cardiac nerves were observed in the dog. When present these nerves passed directly cranioventral between the pulmonary artery and left primary bronchus to the cardiac plexus where they ramified.

Right side

Two to five caudal vagal cardiac nerves arose from the right vagus within three centimeters caudal to the subclavian artery. One caudal vagal cardiac nerve immediately combined with the more dorsal right vertebral cardiac nerve and right recurrent cardiac nerve and passed to the heart, as discussed under the right vertebral cardiac nerve. Its main supply extends along the course of the coronary arteries and onto the right atrium between the cavae. Other caudal vagal cardiac nerves sometimes joined the more ventral right vertebral cardiac nerve or passed directly between the cranial

vena cava and aorta to the cardiac plexus, where they ramified.

Recurrent Cardiac Nerves

Left side

Several left recurrent cardiac nerves originated from the left recurrent laryngeal nerve after it reached the caudal right aspect of the aorta. The left recurrent laryngeal nerve entered into the cardiac plexus in this area and, in most cases, its identity became lost in the plexus. More cranially, the left recurrent laryngeal nerve again reformed into a single trunk. After reforming, twigs could be found between it and the trunk formed by the right vertebral, vagal, and recurrent cardiac nerves. One left recurrent cardiac nerve could be traced caudoventrally from its origin from the left recurrent laryngeal nerve just before the latter entered the cardiac plexus, and then continued between the left branch of the pulmonary artery and the left pulmonary veins and then between the latter vessels and the left auricle to the coronary groove. Here it accompanied the other autonomic nerves along the circumflex branch of the left coronary artery. Areas supplied included the ventrum of the left atrium, right side of the left ventricle, interatrial and interventricular septa, and right caudal portion of the right ventricle.

Right side

From the caudomedial border of the right subclavian artery one or two short, right recurrent cardiac nerve arose from the right recurrent laryngeal nerves. They coursed directly caudoventrally and united, after a short course with the more dorsal right vertebral cardiac nerve, or right caudal vagal cardiac nerves. They accompanied these nerves to the cardiac plexus; along the course of the right coronary artery to the ventrum of the right auricle, and right ventricle; along the descending and circumflex branches of the left coronary artery to the right and left ventricle on the left side, and to the ventrum of the left auricle; and between the venae cavae onto the right atrium.

DISCUSSION

The ganglia and nerves considered in this study often differed greatly in their particulars between species. Conversely many similarities were also noted. Although some variations were noted within species, patterns could be ascertained for each species. In the discussion the order of the results will be maintained.

It is hoped that the reader will now be accustomed to the nomenclature used by the present author. In the discussion, ganglia and nerves referred to by previous authors by different names than those proposed by the present author will be transposed to the present terminology.

Ganglia

Thoracic ganglia

In all species the thoracic sympathetic chain lay near the junction of the ribs with the thoracic vertebrae. Caudal to the cervicothoracic ganglion, one independent ganglion was located bilaterally in each intercostal space. Generally, these ganglia were less distinct in older animals, particularly in the equine and bovine. In the ruminants there was less uniformity in the size of these ganglia, due to the comparatively greater role played by the more cranial thoracic ganglia in the thoracic visceral innervation in these species.

In the bovine, ovine, and porcine a distinct macroscopic

ganglion lay on the left side, caudal to the ligamentum arteriosum in the vascular triangle bounded by the descending aorta, pulmonary artery and vena hemiazygos. In domestic animals, previous researchers have not described this ganglion which this investigator chose to call the cardiac ganglion of the left intervascular triangle (Figures 3, 9, 17, 19 and 23). According to the descriptions of Hardesty (1933) and Mizeres (1963) in man, the ganglion which the present investigator found in the artiodactyla may correspond to Wrisberg's ganglion or the cardiac ganglion.

According to Kopsch (1957) the designation, ganglion cardiacum, (Wrisberg's ganglion) referred to in the Basel (1895) and Jena (1935) *Nomina Anatomica*s, was changed to cardiac ganglia in the 1955 *Paris Nomina Anatomica*. The new term assumes that all the ganglia of the heart, including those numerous microscopic ganglia surrounding the great vessels, be called cardiac ganglia. Gardner, Gray, and O'Rahilly (1963) further regarded any ganglia along the cervicothoracic sympathetic nerves as cardiac ganglia. This latter designation of cardiac ganglia seems too inclusive to the present author. Perhaps, inconstant ganglia along the cervical and thoracic sympathetic nerves to the thoracic viscera could best be called accessory intraneural ganglia of the specific nerve in which they are found.

Wolhynski, F. A. (1928) described an accessory intraneural

ganglion in the bovine on the right side located along the vena azygos dorsal to the heart, which he called the cardiac ganglion or Wrisberg's ganglion. According to the descriptions of Wrisberg's ganglion given by Hardesty (1933) and Mizeres (1963) this cannot be the cardiac ganglion of Wrisberg. In my investigation I occasionally found very small ganglia along the course of the cardiac nerves, which arose not only from the thoracic ganglia but from the cervicothoracic and cervical ganglia also. The small thoracic accessory intraneural ganglion along a thoracic cardiac nerve, which was referred to by Wolhynski, F. A. (1928) as Wrisberg's ganglion is shown on Figure 4.

Cervicothoracic ganglion

In all species the caudal cervical ganglion and first one to three thoracic ganglia were commonly fused on each side of the body to form the cervicothoracic ganglia. In the equine this was less complete on the left side than in all other species, except the porcine.

Independent, first thoracic ganglia may be present in the porcine. In the porcine, and sometimes in the bovine, the left vertebral ganglion blends with the cervicothoracic ganglion. This has not been reported by previous authors for these species, except by McLeod (1958) in the bovine.

Ellenberger and Baum (1943), Bruni and Zimmerl (1951) and Sisson and Grossman (1953), noted that the vertebral ganglion sometimes was incorporated into the cervicothoracic

ganglion in the horse. On the left side this investigator found a close relationship between the vertebral ganglion and cervicothoracic ganglion; however, in all cases these ganglia could be individually differentiated in the horse. On the right side of the horse, a greater distance was noted between these ganglia.

Rami communicantes extended caudally from the cervicothoracic ganglion to at least the first thoracic spinal nerve in the porcine, the second in the caprine, the third in the equine, bovine, ovine and feline, and the fourth in the canine. Cranially, rami were followed to the second cervical spinal nerves in all species, except the cat.

Christensen, Polley, and Lewis (1952), however, histologically followed the vertebral nerve cranially to the third cervical spinal nerve in the cat. Silverman (1963), grossly and histologically, was able to demonstrate rami from the vertebral nerve cranially only as far as the sixth cervical spinal nerve in the dog and cat.

Ansa subclavia

In all cases the ansa subclavia was considered as extending around the subclavian artery, joining the cervicothoracic and vertebral ganglia. When these ganglia blended in the porcine and bovine on the left side, the ansa subclavia was still present. It extended around the subclavian artery and returned to the fused ganglia. On the left side Sisson

and Grossman (1953) did not illustrate an ansa subclavia or brachialis in the horse. In the present author's dissections however, it was found in all specimens. Because, comparatively, it was very thin on the left side in relation to other structures in this area it could be easily overlooked in the equine, porcine, and bovine. Generally, the caudal limb was longer and thinner than the cranial limb in all species. The difference in length was less pronounced on the left side in all species, and on both sides in smaller specimens. Apparently the caudal limb becomes more elongated in conjunction with the stresses of growth. In the horse the ratio was high when comparing the lengths and widths of the caudal limb of the ansa subclavia to the cranial one. The cranial limb, apparently, generally assumed a greater role in carrying sympathetic impulses from the cervicothoracic ganglion to the head, neck, and thorax than did the caudal limb in this species.

Intermediate ganglia

According to the definition given in the introduction, these ganglia were grossly found with some regularity only in the porcine and feline (Figures 10, 11, 12, 23, 24, and 25). In the feline they were limited to the left side. In both species they were located at the caudal ventral border of the subclavian artery along the caudal limb of the ansa subclavia. In neither species had this ganglion been described by previous authors.

Vertebral ganglia

Typically, in all species, the vertebral ganglion lay just cranial to the origin of the vertebral artery or combined costocervico-vertebral trunk at the cranial convergence of the limbs of the ansa subclavia. When the cranial limb of the ansa subclavia was not present the caudal limb still proceeded to the vertebral ganglion which was fused with the cervicothoracic ganglion. As previously mentioned, the left vertebral ganglion was fused with the cervicothoracic ganglion in the porcine, and sometimes in the bovine.

The vertebral ganglia were quite significant in providing cardiac innervation in the equine, canine, and feline. Less importance was noted in the porcine, and little significance was noted in the ruminants.

Middle cervical ganglia

Independent, grossly visible, middle cervical ganglia were noted consistently only in the goat. In two cases in the porcine and three in the sheep a middle cervical ganglion was noted. In physiologic studies, Waites (1957) illustrated a ganglion corresponding to the middle cervical ganglion, on both sides in the sheep. Other investigators have not noted, in domestic animals, the presence of a ganglion corresponding to the middle cervical ganglion of man described by Wrete (1959). More embryologic studies, similar to those

reported by Laubmann (1931) and Wrete (1959) in man, are necessary in domestic animals to complete our knowledge of this ganglion in domestic animals.

Cranial cervical ganglion

In all species this discrete ganglion was found ventromedial to the tympanic bulla. Only in the canine and feline was this ganglion in close apposition to the inferior ganglion of the vagus. No cardiac nerves were demonstrated from this ganglion. However, in the cat a twig from the left ganglion joined twigs from the cranial laryngeal nerve and from the vagus to form a trunk, independent of the vago-sympathetic trunk, which passed to the great vessels dorsal to the heart. This nerve was designated as the depressor nerve by early investigators of the cardiac innervation and has been the subject of numerous investigations in all domestic animals. It is generally agreed that it is primarily a sensory nerve. Physiologists indicate that the sympathetic nerves from the cranial cervical ganglion which join the depressor nerve do not reach the heart.

Vagosympathetic trunk

This trunk was composed of the sympathetic trunk to the head and the vagus to the thoracic and abdominal cavities. A third independent depressor nerve accompanied the vago-sympathetic trunk on the left side in the cat. In the dog the vagus nerve and sympathetic trunk were fused in the

cervical region. In the ruminants, equine and feline they lay in close apposition, but could be separated. These nerve trunks, in the porcine, were loosely held in a common connective tissue sheath.

Cardiac Nerves

Thoracic cardiac nerves

Thoracic cardiac nerves assumed a greater role in the cardiac innervation in the ruminant than in other species of domestic animals investigated, particularly on the left side.

This researcher was in agreement with Perman (1924) and McLeod (1958) in the calf, and Ionescu and Enachescu (1928) in the calf and sheep, in reporting left thoracic cardiac nerves which arose between the cervicothoracic ganglion and sixth thoracic ganglion on the left side in the bovine, ovine, and caprine. Wolhynski, F. A. (1928) illustrated left thoracic cardiac nerves which arose caudal to the seventh thoracic ganglion in the calf. Perman (1924) was not specific about the left thoracic cardiac nerves of the goat and illustrated left thoracic cardiac nerves only from the third thoracic ganglion in the sheep. May (1964) indicated the origin of these nerves as being between the first and fourth thoracic ganglia on the left in the sheep. Waites (1957), in the sheep, physiologically, found no cardio-accelerator fibers caudal to the fifth thoracic spinal root on the left side.

Other investigators have not included the left thoracic cardiac nerves in their descriptions of the cardiac innervation in the equine, bovine, ovine, caprine, and porcine. An exception is the reference to a left cardiac nerve from the first thoracic ganglion by Tagand and Barone (1964) in the horse. This nerve, however, is considered by this author and most others as arising from the cervicothoracic ganglion. It has been found by this author that the left thoracic cardiac nerves arose between the left cervicothoracic ganglion and the sixth thoracic ganglion in the equine and porcine. In the porcine they occasionally arose from the seventh thoracic ganglion also.

Left thoracic cardiac nerves in the equine, bovine, ovine, caprine, and porcine passed primarily between the left auricle and left pulmonary veins to the coronary groove. They continued in the coronary groove to the right side and cranially into the right longitudinal sulcus. Along this course they supplied the dorsum of the left auricle, ventrum of the left atrium, caudal and right walls of the left ventricle, interatrial and interventricular septa, and caudal portion of the right ventricle. Perman (1924) and Ionescu and Enachescu (1928) mentioned only branches to the ventricles and left atrium in the calf and sheep. The findings of this researcher, on the areas supplied by the left thoracic cardiac nerves in the bovine, agreed with Wolhynski, F. A. (1928) and Wolhynski, T. (1928). In their

course towards the heart most left thoracic cardiac nerves passed through the cardiac ganglion of the left intervascular triangle in the bovine, ovine and porcine. Previous authors have not noted the entrance of thoracic cardiac nerves into this ganglion.

In one case, the present author was able to demonstrate left thoracic cardiac nerves arising from the third to eighth thoracic ganglia in the canine. In the cat these nerves were present between the third and fifth left thoracic ganglia. Saccomanno (1943) indicated that thoracic cardiac nerves on the left in the cat may arise at least as far caudal as the fifth or sixth thoracic ganglion. Anufriew (1928) illustrated them as arising as far caudal as the third thoracic ganglion. The latter also illustrated a nerve from the second thoracic ganglion. Mizeres (1958) found primarily cardiac augmentor fibers from the left thoracic ganglion but did not give the caudal limits of their origin. Stromberg (1964) considered the thoracic cardiac nerves on both sides as inconstant and did not refer to the level of their origins. Perman (1924) and previous investigators did not recognize thoracic cardiac nerves in the dog or cat.

In agreement with Schurawlew, (1928), Anufriew (1928), Saccomanno (1943), and Mizeres (1955a), the present investigator was able to follow the left thoracic cardiac nerves to the aorta and cardiac plexus in the canine and feline. These

nerves may join the left cervicothoracic cardiac nerves passing to the cardiac plexus. This investigator was unable to follow nerves directly to the left atrium and ventricle in the cat, or directly to the left atrium in the canine, as did Ionescu and Enachescu (1928). It is possible however that impulses from these nerves may reach these areas after passing through the cardiac plexus.

Right thoracic cardiac nerves were found originating between the cervicothoracic ganglion and the seventh thoracic ganglion in the horse. They arose as far caudal as the sixth thoracic ganglion in the bovine and ovine, the fifth thoracic ganglion in the canine, the fourth thoracic ganglion in the feline, and second thoracic ganglion in the porcine. Like Perman (1924), grossly, the present author found no thoracic cardiac nerves from the right side in the goat. As in all the other species, however, thoracic nerves of the goat passed to the aorta. Perman (1924) found right thoracic cardiac nerves that arose from the third and fourth thoracic ganglia in the calf. These passed to the right atrium and across the coronary groove to the right ventricle. No right thoracic cardiac nerves were illustrated in the sheep. Ionescu and Enachescu (1928) also included a nerve from the second thoracic ganglion in the supply of the right atrium in the sheep and calf. Wolhynski, F. A. (1928) illustrated right thoracic cardiac nerves from the third thoracic ganglion which passed on either side of the caudal vena cava. They

supplied the right and left atria and continued across the coronary groove to the right and left ventricles. Twigs from the right thoracic cardiac nerves, in my findings, may accompany caudal vagal cardiac nerves across the coronary groove in the bovine. The present gross dissections agreed with Waites (1957) in regards to the caudal limits of the right thoracic cardiac nerves in the sheep. He determined that cardio-accelerator fibers entered cardiac nerves from the first to sixth thoracic spinal roots. Reference to right thoracic cardiac nerves in the horse included Tagand and Barone (1964) mentioning them from the first and third ganglia and Hopkins (1927) from the first in the horse. In the canine, Schurawlew (1928) does not illustrate right thoracic cardiac nerve. Mizeres (1958) elicited cardiac acceleration from thoracic cardiac nerves as far caudally as the fourth right thoracic ganglion. Grossly, my results agreed with Ionescu and Enachescu (1928) who demonstrated the origin of these nerves caudally as far as the fifth thoracic ganglion. Right thoracic cardiac nerves were followed between the vena cava to the lateral wall of the right atrium in the horse, bovine, ovine, porcine, canine and possibly the cat. In addition, the right thoracic cardiac nerves in the horse joined the left thoracic cardiac nerves and the right and left dorsal cervicothoracic cardiac nerves and passed to the heart. The main ramifications of these nerves were along the circumflex branch of the left coronary artery, as

described for the left thoracic cardiac nerves. In the ovine and porcine right thoracic cardiac nerves accompanied the right coronary artery to the right atrium and ventricle. Additionally, in the porcine and also in the bovine, these nerves passed to the left and descended in the left longitudinal sulcus. Areas supplied included the left auricle and right and left ventricles. The right thoracic cardiac nerves in the cat joined the vagus nerves and presumably accompanied the caudal vagal cardiac nerves to the right atrium.

Cervicothoracic cardiac nerves

In all species except the canine, the left cervicothoracic cardiac nerves were followed between the left pulmonary veins and the left auricle to the coronary groove. These nerves continued to the right side and cranially into the right longitudinal sulcus. In this course branches were distributed to the dorsum of the left auricle, ventrum of the left atrium, caudal and right sides of the left ventricle, the interatrial and interventricular septa, and the right caudal portion of the right ventricle. Many branches were present near the cranial end of the coronary sinus. Presumably, besides their influence on the coronary sinuses, these nerves and the thoracic cardiac nerves contributed the major sympathetic innervation to the atrioventricular node. The latter nerves assumed the major supply to these areas in the ruminants. The former predominated in the supply of this

area in the porcine. The left cervicothoracic and left vertebral cardiac nerves shared the major supply to these areas in the feline and equine. In the canine the caudolateral vertebral cardiac nerve provided sympathetic innervation to this area.

Bisenkov (1965) noted that a depression of the human during catheterization of the coronary sinus may occur. Afferent pathways initiating this response were carried by the left vagus nerve. Perhaps afferent fibers follow the sympathetic nerves to the thoracic spinal cord from this area also.

Two left cervicothoracic cardiac nerves in the caprine, one or two in the ovine, and two to five on the porcine, three in the equine, three to five in the bovine, two to six in the canine and two to three in the feline, were observed. In the latter four species, besides the areas of the heart just described as receiving contributions from these nerves, branches passed along the descending and circumflex branch of the left coronary artery supplying the left side of the ventricles, left auricle and interventricular septum. Other left cervicothoracic cardiac nerves accompanied the right coronary arteries to the right ventricle and auricle in the equine, bovine, ovine, caprine, canine, and feline.

Previous investigators who indicated cardiac nerves from the left cervicothoracic ganglion in the horse included

McFadyean (1903, 1922), Mannu (1914), Bruni and Zimmerl (1951), Sisson and Grossman (1953), Rooney (1956), Usenik (1957), and Akaevskii (1962). Only McFadyean (1903, 1922) and Mannu (1914) included the destination for this nerve, however. The former found that it passed to the left auricle. The latter reported that it passed to the cardiac plexus. No descriptions of the left cervicothoracic cardiac nerves were found in the porcine. In the ruminants, Perman (1924) indicated that the nerves from the left cervicothoracic ganglion in the calf passed only to the large arteries and ventral wall of the right ventricle. In the sheep, he followed them down the left longitudinal sulcus. The course of the left cervicothoracic cardiac nerves in the goat was described as the same as that of the calf and sheep. In this investigator's present research direct left cervicothoracic cardiac nerves were not followed to the left longitudinal sulcus in the ovine. Instead, right cervicothoracic cardiac nerves passed to the left side, caudal to the aorta, in both the sheep and goat, and contributed a major sympathetic portion of the left longitudinal sulcus. In the bovine, ovine, caprine and feline, Perman (1924) indicated only one left cervicothoracic cardiac nerve for each species. McLeod (1958) referred to only one in the bovine, which he described as passing to the base of the heart. Wolhynski, F. A. (1928) presented a much more complete description of the left cervicothoracic cardiac nerves of the bovine than

previous investigators. This investigator's findings agreed with his descriptions of the areas innervated by these nerves.

Two left cervicothoracic cardiac nerves were noted by Perman (1924) in the canine. In the feline, Perman (1924) indicated that the innervation of the heart was, for the most part, similar to that of the dog. The left cervicothoracic cardiac nerves passed to the atria, dorsal walls of both ventricles and the lateral wall of the left ventricle. Saccomanno (1943) illustrated nerves from the left cervicothoracic ganglion to the cardiac plexus in the cat. Anufriew (1928), in the cat, followed them to the areas described in the present investigation as common to all species studied, except the canine. Schurawlew (1928) and Mizeres (1955a) illustrated left cervicothoracic cardiac nerves to the areas found common to all species in this study. In addition, Mizeres (1955a) indicated that they pass to the cardiac plexus. Other authors presented a less complete description of these nerves. Therefore, their findings will not be discussed.

The present investigation found that three areas were commonly supplied by the right cervicothoracic cardiac nerves. One area included the right ventricle and ventral portion of the right atrium from along the course of the right coronary artery. A second area was supplied by the right cervicothoracic cardiac nerves which coursed to the left side caudal to the aorta and descended into the left longitudinal sulcus.

Branches extend onto both ventricles from this sulcus as well as to the left side of the left ventricle and ventrum of the left auricle from branches extending caudally along the circumflex branch of the left coronary artery. The third area supplied by the right cervicothoracic cardiac nerves was the right lateral wall of the right atrium. Most of these nerves swept over the right atrial wall towards the sinoatrial node, sometimes others extended across the coronary groove to the right longitudinal sulcus.

In the equine, nerves were not found to the first area described. The left vertebral and left cranial cervicothoracic cardiac nerves assumed the innervation of this area in the equine. An additional right cervicothoracic cardiac nerve in this species was followed, however, with the left cervicothoracic and right and left thoracic cardiac nerves, along the course of the circumflex branch of the left coronary artery on the caudal right side of the heart into the right longitudinal sulcus. In the bovine, caprine and ovine a portion of this latter area described in the equine was reached by a right cervicothoracic cardiac nerve entering the coronary groove between the caudal vena cava and the left atrium.

In the bovine no nerves were followed directly to the second area. This area in the bovine was primarily supplied by right thoracic and left caudal cervicothoracic cardiac nerves.

In the equine, Chauveau (1905), McFadyean (1903, 1922), Mannu (1914), Hopkins (1937), Bruni and Zimmerl (1951), Sisson and Grossman (1953), Rooney (1956), Usenik (1957), and Akaevskii (1962) all indicated, directly or indirectly, that cardiac nerves may arise from the right cervicothoracic ganglion. McFadyean (1903, 1922) indicated a single branch accompanied the right coronary artery to the right ventricle. The present author was unable to demonstrate such a branch in this investigation, but, instead, found that the left cervicothoracic and vertebral nerves assumed the sympathetic innervation along this artery. Mannu (1914), Hopkins (1937) and Bruni and Zimmerl (1951) indicated that the right cervicothoracic cardiac nerves passed to the cardiac plexus. The latter also mentioned their supplying the atria. Other original investigations and textbooks did not include the destination of these nerves in the horse even when their presence was recognized.

A description of right cervicothoracic cardiac nerves was not noted in the porcine in previous literature.

Right cervicothoracic cardiac nerves in the bovine and ovine were illustrated, along the left longitudinal sulcus to the ventricles; to the right atrium; and onto the ventral right ventricular wall by Perman (1924), only the former was found in the goat. As mentioned previously a direct nerve to the left longitudinal sulcus was not found in the bovine by the present investigator. Instead, a left cervicothoracic cardiac

nerve, in agreement with Wolhynski, F. A. (1928), and right thoracic cardiac nerves contributed the main sympathetic innervation to this area. In the ovine and caprine the present author was in agreement with the three areas described by Perman (1924) as supplied by the right cervicothoracic cardiac nerves in the ovine. In the caprine, Perman (1924) indicated only one area supplied by these nerves. In addition to these three areas, the present investigator found that in the caprine the right cervicothoracic cardiac nerves passed between the caudal vena cava and left atrium to ramify along the circumflex branch of the left coronary artery. The present findings on the right cervicothoracic cardiac nerves of the bovine were in accord with those of Wolhynski, F. A. (1928).

Descriptions by other textbooks or investigators of the cardiac innervation in the ruminant by the right cervicothoracic cardiac nerves were lacking.

In the cat and dog, Perman (1924) found right cervicothoracic cardiac nerves joining vagal and recurrent cardiac nerves. Branches from this combined trunk passed to the ventral portion of the right ventricle and along the left longitudinal sulcus, ramifying on the ventricles. Schurawlew (1928) and Nonidez (1939) found no nerves directly from the right cervicothoracic ganglion in the dog, but noted them from the posterior limb of the ansa subclavia. Schurawlew

(1928) followed these nerves to the right atrium and auricle and between the caudal vena cava and left atrium to the coronary groove in the dog. Schurawlew (1928) attributed the right vertebral cardiac nerves with supplying the areas described by Perman (1924) as partially supplied by the right cervicothoracic cardiac nerves. Mizeres (1955a, 1958) indicated that the right cervicothoracic nerves arose from the right cervical thoracic ganglion and/or ansa subclavia and passed to the cardiac plexus and right atrial wall. In the present study the right cervicothoracic cardiac nerves mainly joined the right vertebral, vagal and recurrent cardiac nerves, which passed through the cardiac plexus to the areas described both by Perman (1924) and Mizeres (1955a). Anufriew (1928), in the cat, agreed with Perman (1924) in his areas of distribution for the right cervicothoracic cardiac nerves, but noted, also, branches to the right auricle and atrium. The present findings were in agreement with Anufriew (1928).

Intermediate cardiac nerves (Refer to Figures 9, 10, 11)

These nerves were found only in the porcine and feline and only on the left side in the latter. No record of their previous description was found.

In both species the left intermediate cardiac nerves passed between the left pulmonary veins and left auricle to the coronary groove. They continued cranially to the right side of the left ventricle and descended into the right

longitudinal sulcus. In this course they contributed, with other left thoracic, cervicothoracic, vertebral, and vagal cardiac nerves, to the dorsum of the left auricle, ventrum of the left atrium, caudal and right sides of the left ventricle, interatrial and interventricular septa, and caudal portion of the right ventricle. In the porcine the left intermediate cardiac nerves passed through the cardiac ganglion of the left intervascular triangle on their way to the heart.

Right intermediate cardiac nerves were found in the porcine only. Together with the right vertebral and cervicothoracic cardiac nerves they contributed sympathetic fibers to the right atrium and ventricle from along the right coronary artery, and to both ventricles and the left auricle as one branch coursed to the left longitudinal sulcus.

Vertebral cardiac nerves

Considerable variation in the importance of the left vertebral cardiac nerves was noted. In the porcine, and sometimes in the bovine, the left vertebral ganglion was incorporated into the cervicothoracic ganglion, hence, the cardiac innervation to which it contributed would probably be included in the cranial cervicothoracic cardiac nerves. In the ruminants, the vertebral cardiac nerves assumed relatively little significance in cardiac innervation. Of the ruminants studied, only in the caprine were grossly visible twigs noted which passed to the heart from the vertebral ganglia. In the equine, canine, and feline vertebral

cardiac nerves assumed a large proportion of the sympathetic cardiac innervation from the left side. In all three of these species the left vertebral cardiac nerves passed with branches of the other left cardiac nerves between the left auricle and left pulmonary veins to the caudal part of the coronary groove. They continued cranially on the right side and descended in the right longitudinal sulcus. Along this course branches passed to the dorsum of the left auricle, ventrum of the left atrium, caudal and right sides of the left ventricle, interatrial and interventricular septa, and right caudal wall of the right ventricle. Probably the largest branch of the left vertebral nerve in the horse descended between the aorta and pulmonary artery and continued along the course of the right coronary artery providing, in this species, the major supply to the right ventricle and ventrum of the right auricle. In the caprine, canine, and feline the right and left vertebral cardiac nerves were followed along the right coronary artery, as well as to the left side where they followed the descending and circumflex branches of the left coronary arteries to this side of the heart in common with the left vertebral cardiac nerves. The right vertebral cardiac nerves were followed to these areas in the porcine. In the equine the right vertebral cardiac nerves passed only to the second area. In addition, right vertebral cardiac nerves were followed between

the cavae to the lateral right atrial wall in all species, except the bovine and ovine. In the canine and feline they also reached the coronary groove on the right side, from between the caudal vena cava and the left atrium. In the horse the left vertebral nerve, passing along the right coronary artery, was recognized by McFadyean (1903, 1922), Hopkins (1937), and Sisson and Grossman (1953). A right vertebral cardiac nerve was noted as passing to the left coronary groove by Hopkins (1937) and Sisson and Grossman (1953), in the horse. Kazem-Beck (1888), in the porcine, noted a large number of cardiac nerves from the vertebral ganglion which extended nonspecifically onto the auricles and ventricles from the coronary grooves. In agreement with Perman (1924), in the bovine and ovine, and with Wolhynski, F. A. (1928) in the bovine, the present author found no cardiac nerves from the vertebral ganglia in these species. Recognition of vertebral cardiac nerves in the cat have been recorded by Mannu (1914) and Saccomanno (1943), however, they represent their termination only as the cardiac plexus. Ellenberger and Baum (1943) noted their presence but not their distributions. Anufriew (1928) did not recognize these nerves. Perman (1924) followed vertebral cardiac nerves from each side to the cranial portion of the right ventricle. In the present investigator's findings these nerves in the cat passed to each of the major areas of distribution (Table 8).

The results of this investigation on the left vertebral cardiac nerves were, in number, compatible with those summarized by Stromberg (1964). However, in the present investigation these nerves were carried through the cardiac plexus to their major areas of distribution (Figure 8). The areas of distribution on both sides were in agreement with Schurawlew (1928).

Middle cervical cardiac nerves

Only in the caprine were middle cervical cardiac nerves recognized consistently. Each of the major areas of distribution (Table 8) were supplied by these nerves. No previous references to these nerves were noted by other investigators.

Cranial cervical cardiac nerves

In the horse, nerves were seen arising from the sympathetic trunk cranial to the vertebral ganglion. No grossly visible middle cervical ganglion from which these might have arisen was distinguished. Physiological studies will be necessary to characterize the origin of these nerves. Although a separate nerve accompanied the left vagosympathetic trunk caudally from the head in the feline, this nerve could be followed only to the aorta near the origin of the left subclavian and brachiocephalic arteries. Therefore, it was not considered to be a cardiac nerve.

Vagal cardiac nerves

Nonidez (1939) described parasympathetic postganglionic axons as passing primarily to structures above the coronary

groove. Sympathetic nerves primarily passed to the ventricles. Tchong (1951), however, noted that both the atria and ventricles were doubly innervated by excitatory and inhibitory fibers, although parasympathetic fibers were fewer in the ventricles. The present author's gross observations on the distribution of cardiac nerves would suggest an abundant supply to both areas by both types of nerves.

The left caudal vagal cardiac nerves primarily passed with the sympathetic nerves along the circumflex branch of the left coronary artery supplying the caudal and right surfaces of the heart. The left cranial vagal cardiac nerves passed along the right and left coronary arteries from near their origins onto the cranial, right and left sides of the heart. Right caudal vagal cardiac nerves primarily ramified along the right coronary artery onto the cranial and right sides of the heart, and along the descending and circumflex branches of the left coronary artery onto the left side of the heart. Right cranial vagal cardiac nerves, when present, also assumed the courses of the right caudal vagal cardiac nerves. Left cranial vagal cardiac nerves were noted by most authors in each species. Hopkins (1937), in the horse, followed these nerves to the left atrium and along the left and right coronary arteries from near their origin. On the right side he followed vagal cardiac nerves to the atria. Other descriptions in this species were less complete and often these nerves were followed only to the cardiac plexus.

Vagal cardiac nerves, in the porcine, were indicated by Kazem-Beck (1888) as extending onto the ventricular surfaces and auricles from the coronary grooves. No specific descriptions were given.

In the bovine the present findings were in agreement with Wolhynski, F. A. (1928) on the distribution of both cranial and caudal vagal cardiac nerves. Other descriptions by previous authors in the artiodactyla, in regards to these nerves, were incomplete. Waites (1957), in the sheep, although he gave no anatomical descriptions, illustrated vagal cardiac nerves to each of the areas indicated in the present investigation (Table 8). In the canine, Mizeres (1955a, b) referred to cranial and caudal vagal cardiac nerves on the right side. This designation applied to nerves which arose from the right vagus between the origin of the recurrent laryngeal nerve and the division of the right vagus into dorsal and ventral trunks. A vagal cardiac nerve, which was illustrated as arising from the vagus nerve cranial to the recurrent laryngeal nerve, was not named. In the present investigation vagal cardiac nerves were found as originating on either side of the origin of the cranially passing left and right recurrent laryngeal nerves. Therefore, the origin of the recurrent laryngeal nerve was established as the division between the cranial and caudal vagal cardiac nerves. Mizeres (1957) indicated that the left vagal cardiac

nerves passed to the left atrium and dorsal wall of the left ventricle. He followed the right vagal cardiac nerves to the cardiac plexus or right dorsal atrial wall. The summation of findings by previous investigators for the vagal cardiac nerves found in the literature review was, as has been found for other species, rather general. In the feline, the present observations on the areas innervated by vagal cardiac nerves was in agreement with Anufriew (1928).

Recurrent cardiac nerves

In the present investigation recurrent cardiac nerves were found on both sides in all species, except the feline. In these species, recurrent cardiac nerves were followed to the cardiac plexus in all cases. Other major areas of supply were generally less endowed with direct branches from these nerves. The right recurrent cardiac nerves generally followed the right coronary artery to the right auricle and ventricle, the descending and circumflex branches of the left coronary artery to the left auricle, left side of the left ventricle, and the left cranial surface of the right ventricle, or passed on either side of the caudal vena cava into the right atrium, and areas adjacent to the coronary sinus. Only Bradley (1922) mentioned recurrent cardiac nerves in the horse, however, he did not indicate their destination. Kazem-Beck (1888) noted them only on the right side in the porcine and followed them to the cranial surface of the

ventricles. In the ruminants only Perman (1924) recognized recurrent cardiac nerves, and only in the right side. These passed to the ventral surfaces of the ventricles.

More importance was given to the right recurrent cardiac nerves in the canine by Mizeres (1955a) than was recognized in the present investigation. He referred to a combined trunk on the right side which was composed of vertebral, cranial vagal, caudal vagal, and recurrent cardiac nerves, collectively, as the right recurrent cardiac nerve. It seemed more appropriate to this author to consider only nerves originating directly from the recurrent laryngeal nerves as recurrent cardiac nerves. Mizeres (1957) indicated the presence of left recurrent cardiac nerves in the canine, which passed to the left atrium. The distribution of right recurrent cardiac nerves in the present study was in agreement with Anufriew (1928) for the cat. Like the present author, he did not follow left recurrent cardiac nerves to the heart in the cat.

In the course of dissection it was noted that although the designation, cardiac nerves, has been ascribed to the nerves just described, most contain fibers which pass to other areas also. These splanchnic fibers arose at various points along the cardiac nerves, or may pass through the cardiac plexus to the lungs along the pulmonary arteries and veins. Cooper (1961), basing his anatomical information on Nonidez (1939), Mizeres (1955a) and others, has presented a method of regional neural ablation to denervate the heart

without disturbing the other visceral organs. This technique would prevent many of the sequella noted after methods which advocate cervicothoracic and thoracic ganglionectomies. The present author, however, feels that Cooper's method (1961) although superior to those involving ganglionectomies and vagotomies disregards innervation which passes through the cardiac plexus to the lungs. This organ and vasculature near the heart would then be partially denervated also. The effects of this denervation should be investigated. Although physiologically complete cardiac denervation was noted by Cooper (1961), the present author also feels that histologic verification would be necessary to substantiate the presence of complete cardiac denervation.

The present study has been limited to a gross, morphologic description of the cardiac nerves of domestic animals. It is hoped by the present author that he may continue this investigation by characterizing the cardiac nerves using physiologic and pathologic methods together with embryologic studies of related ganglia. These studies are necessary for the further understanding of this area.

SUMMARY AND CONCLUSIONS

The findings of gross dissections of the cardiac innervation in forty embalmed specimens (five each of the equine, bovine, ovine, caprine, porcine and canine and ten feline) were reported and compared. A review of nomenclature used by previous authors, the consideration of proposed nomenclature by the 1963 section of the International Commission for Veterinary Anatomical Nomenclature responsible for nomenclature on the autonomic nervous system, and the accepted nomenclature of the 1961 *Nomina Anatomica* were helpful in formulating nomenclature which facilitates the transposition of information between species.

Cardiac nerves were referred to by their ganglion of origin. The latter required considerable attention since homologous individual ganglia were not always present between species. A middle cervical ganglion was consistently found only in the caprine. Intermediate cardiac ganglia were found only in the feline and porcine. On the left side the vertebral ganglion was found to be incorporated into the cervicothoracic ganglion in the porcine and sometimes in the bovine. A cardiac ganglion of the left intervascular triangle was found in the bovine, ovine, and porcine. Besides the description of cardiac nerves which arose from the cervical and thoracic ganglia, their dimensions and communicating rami were noted.

Cardiac nerves were generally similar between specimens of each species. Interspecies comparisons of these nerves yielded both similarities and differences. Sympathetic cardiac innervation in the ruminants was found to originate primarily from the thoracic ganglia on the left side, and from these and the cervicothoracic ganglion on the right. The vertebral ganglia were of little significance in cardiac innervation in the ruminants. The additional middle cervical ganglia in the caprine also contributed cardiac nerves. In the porcine cervicothoracic cardiac nerves contributed the major sympathetic innervation to the heart. This responsibility was assumed primarily by the vertebral and cervicothoracic ganglia in the equine, caprine, and feline. The former was of greater significance in the canine. Cranial vagal cardiac nerves predominated on the left side, while caudal vagal cardiac nerves assumed a greater role in the parasympathetic innervation of the heart from the right side. Recurrent cardiac nerves did not form a major nerve supply to the heart in any species. Generally, the cardiac nerves followed blood vessels from near the origin of each nerve to its destination in a specific area of the heart. Six general areas were recognized as receiving the majority of cardiac nerves. These extended along the course of the right coronary artery; descending and circumflex branches of the left coronary artery on the left side; circumflex branch of the

left coronary artery caudally and on the right side; between the venae cavae; between the caudal vena cava and left atrium; and into the cardiac plexus. To some extent the first five are extensions of the latter; however, major branches of cardiac nerves generally passed through, or independent from, the cardiac plexus to supply these areas. Lesser contributions joined these major branches from the cardiac plexus. This results in a compensatory system in which possibly any cardiac nerve entering the cardiac plexus may assume some responsibility in supplying all the major areas of the heart, thereby augmenting the major nerves to these areas. In addition to cardiac innervation cardiac nerves passed to other thoracic viscera, either along their course to the heart or from the cardiac plexus. Nerves from the latter area passed along pulmonary vessels to the lungs.

In all species nerves from the sympathetic ganglia extended to the vicinity of the atrioventricular node and coronary sinus primarily by the left sympathetic cardiac nerves. Both left and right vagal and recurrent cardiac nerves generously supplied this area. Sympathetic, parasympathetic, and afferent cardiac nerves extending between the venae cavae towards the sinoatrial node in all species, originated primarily from the right side. The innervation, extending along the right coronary artery anteriorly and to the right, the descending and circumflex branches of the

left coronary artery on the left, and the cranial surface of the heart, was found to differ between species in regards to the origin of their major supply.

BIBLIOGRAPHY

- Akaevskii, A. I.
1962 Anatomiya domashnikh zhivotnykh (Anatomy of domestic animals). Moskva, SSSR, Izdatelstvo Sel'skokhozyaistvennoi Literatury Zhurnalov I Plakatov.
- Allan, F. D.
1958 An analysis of the cervico-thoracic visceral branches of the vagus and the sympathetic trunk in the presence of an anomalous right subclavian artery. Anatomical Record 132: 71-79.
- Anufriew, W. N.
1928 Die herznerven des katze. Zeitschrift für die Gesamte Anatomie 86: 639-654.
- Argaud, R.
1911a Sur la présence de ganglions nerveux dans l'épaisseur de la valvule de thébésius chez ovis aries. Comptes Rendus des Seances de la Societé de Biologie, Paris 70: 699-700.
- Argaud, R.
1911b Sur l'innervation de la zone auriculaire droit qui réfond á l'origine de la systole card. Comptes Rendus des Seances de la Societé de Biologie, Paris 70: 1022-1023.
- Argaud, R.
1911c Note sur l'innervation intra-cardiaque. Comptes Rendus des Séances de la Societé de Biologie, Paris 71:149-150.
- Axford, M.
1928 Some observations on the cervical sympathetic in man. Journal of Anatomy 62: 301-318.
- Ball, J. D.
1910 Andreas Vesalius. Saint Louis, Missouri, Saint Louis, Medical Science Press.
- Berkley, H. J.
1894 The intrinsic nerve supply of the cardiac ventricles in certain vertebrates. Johns Hopkins Hospital Reports 4: 248-255. Original not available; cited in Nettleship, W. A. 1936. Experimental studies on the afferent innervation of the cat's heart. Journal of Comparative Neurology 64: 115.

- Bernhardt, E.
1868 Anatomische und physiologische untersuchungen über den nerve depressor bei der katze. Dissertation, Dorpat. Original not available; cited in Anufriew, W. N. 1928. Die herznerven der katze. Zeitschrift für die Gesamte Anatomie 86: 639.
- Bidder, F.
1852 Ueber functionell verschiedene und räumlich getrennte nervencentra im froschherzen. Archiv für Anatomie, Physiologie, und Wissenschaftliche Medicin 1852: 163-144.
- Bisenkov, N. P.
1965 Characteristic physiological features of the coronary sinus of the heart (translated title). Vestnik Khirurgii imeni I. I. Grekova 94: 47-52. Original not available; abstracted in Excerpta Medica Section XVIII Cardiovascular Diseases 9: 864. 1965.
- Blin, P. C.
1958 Vergleichend-anatomische untersuchungen über das ganglion stellatum der haussäugetiere sowie über seine morphogenese an hand von makroskopischen befunden. Verhandlungen der Anatomischen Gesellschaft auf der fünfundfünfzigsten Versammlung in Frankfurt/Main vom 9 bis 13 April 1958. pp. 74-89. Jena, Germany. VebGustav Fischer Verlag.
- Boehm, R.
1875 Untersuchungen über den nervus accelerator cordis der katze. Archiv für Experimentelle Pathologie und Pharmakologie 4: 255-279.
- Bourdelle, E.
1920 Porc. In Montane, L., Bourdelle, E., and Bressou, C., editors. Anatomie regionale des animaux domestiques. Volume 3. Paris, France, Librairie J. B. Bailliere et Fils.
- Bourdelle, E. and Bressou, C.
1938 Equides cheval-ane-mulet. In Montane, L., Bourdelle, E., and Bressou, C., editors. Anatomie regionale des animaux domestiques. Deuxieme edition. Volume 1. Paris, France, Librairie J. B. Bailliere et Fils.

- Bourdelle, E. and Bressou, C.
1953 Carnivores Chien et Chat. In Montane, L.,
Bourdelle, E., and Bressou, C., editors. Anatomie
regionale des animaux domestiques. Volume 4.
Paris, France, Librairie J. B. Bailliere et Fils.
- Boyd, J. D.
1941 The nerve supply of the mammalian ductus arteriosus.
Journal of Anatomy 75: 457-468.
- Bradley, O. C.
1922 The topographical anatomy of the thorax and abdomen
of the horse. Edinburgh, Scotland, W. Green and
Son, Limited.
- Bradley, O. C.
1923 The topographical anatomy of the head and neck of
the horse. Edinburgh, Scotland, W. Green and Son,
Limited.
- Breland, O. P.
1953 Manual of comparative anatomy. Second edition.
New York, New York, McGraw-Hill Book Company, Inc.
- Bronk, D. W., Ferguson, L. K., Margaria, R., and Solandt, D. Y.
1936 Activity of cardiac sympathetic centers. American
Journal of Physiology 117: 237-249.
- Bruni, A. C. and Zimmerl, U.
1951 Anatomia degli animali domestici. Second edition.
Volume two. Milano, Italy, Casa Editrice Dotter
Francesco Vollardi.
- Chauveau, A. and Arloing, S.
1905 The comparative anatomy of domesticated animals.
Second English edition. New York, New York,
D. Appleton and Company.
- Choulant, J. L.
1920 Anatomists. Chicago, Illinois. The University of
Chicago Press.
- Christensen, K., Polley, E. H., and Lewis, E.
1952 The nerves along the vertebral artery and innerva-
tion of the blood vessels of the hind brain of the
cat. Journal of Comparative Neurology 96: 71-91.

- Cooper, T., Gilbert, J. W., Bloodwell, R. D., and Crout, J. R.
1961 Chronic extrensic cardiac denervation by regional neural ablation: description of the operation, verification of the denervation and its effects on myocardial catecholamines. *Circulation Research* 9: 275-281.
- Cyon, E. und Ludwig, C.
1866 Die reflexe eines der sensiblen nerven des Herzens auf die motorischen der blutgefäße. *Sächsischen Akademie der Wissenschaften Mathematisch-Phkysische Classe Berichte* 18: 307-328.
- Davies, D. V. and Davies, F.
1964 *Gray's anatomy*. Thirty-third edition. London, England, Longmans, Green and Company, Limited.
- Davies, F., Francis, E. T. B., and King, T. S.
1952 Neurological studies of the cardiac ventricles of mammals. *Journal of Anatomy* 86: 130-143.
- Donald, P. E. and Shepherd, J. T.
1963 Response to exercise in dogs with cardiac denervation. *American Journal of Physiology* 205: 393-400.
- Durward, A.
1953 Peripheral nervous system. In Brash, J. C., editor. *Cunningham's textbook of anatomy*. pp. 1009-1147. Ninth edition. London, England, Oxford University Press.
- Ellenberger, W. and Baum, H.
1943 *Handbuch der vergleichenden anatomie der haustriere*. Eighteenth edition. Berlin, Germany, Springer Verlag.
- Fallopilus, Gabriello
1561 *Observations anatomicae*. Venice. Original not available; cited in Ball, J. M. 1910. *Andreas Vesalius*. p. 121. Saint Louis, Missouri, Saint Louis Medical Science Press.
- Fisher, A. W. F.
1965 The intrinsic innervation of the pulmonary vessels. *Acta Anatomica* 60: 481-496.
- Foley, J. D. and DuBois, F. S.
1940 A quantitative and experimental study of the cervical sympathetic trunk. *Journal of Comparative Neurology* 72: 587-603.

- Foust, H. L. and Getty, R.
1960 Atlas and dissection guide for the study of anatomy of domestic animals. Third edition. Ames, Iowa, Iowa State University Press.
- Galen, C. (131-200 A.D.)
1538 Opera omnia. Three volumes. Baileae. J. Hervagium et J. Erasmium. Original not available; cited in Mitchell, G. A. G. 1953. Anatomy of the autonomic nervous system. p. 1. Edinburgh, Scotland, E. and S. Livingstone, Limited.
- Gardner, E., Gray, D. J., and O'Rahilly, R.
1963 Anatomy: a regional study of human structure. Second edition. Philadelphia, Pennsylvania, W. B. Saunders Company.
- Gaskell, W. H. and Gadow, H.
1883 On the anatomy of the cardiac nerves in certain cold-blooded vertebrates. Journal of Physiology 5: 362-372.
- Getty, R.
1964 Atlas for applied veterinary anatomy. Second edition. Ames, Iowa, Iowa State University Press.
- Grant, J. C. B.
1958 A method of anatomy. Sixth edition. Baltimore, Maryland, The Williams and Wilkins Company.
- Greenberg, S. R.
1954 Sympathetic components of the vagus cardiac nerves of the dog. Anatomical Record 118: 304-305.
- Greenberg, S. R.
1956 A fiber analysis of the vagus cardiac rami and the cervical sympathetic nerves in the dog. Journal of Comparative Neurology 104: 33-48.
- Greenfield, L. J. and Ebert, P. A.
1963 Cardiac denervation effect in hypoxia and hypercapnia. Archives of Surgery 87: 717-721.
- Habel, R. E.
1961 Applied anatomy: a laboratory guide for veterinary students. Ithaca, New York, Author.
- Habel, R. E.
1964 Guide to the dissection of domestic ruminants. Ann Arbor, Michigan, Edwards Brothers, Incorporated.

- Hardesty, I.
1933 The nervous system. In Jackson, C. M., editor. Morris' human anatomy. pp. 825-1127. Ninth edition. Philadelphia, Pennsylvania, W. B. Saunders Company.
- Harrison, B. M.
1948 Dissection of the cat: a laboratory manual. Saint Louis, Missouri, C. V. Mosby Company.
- Hippocrates
340 B.C. On the heart. Original not available; cited in Gardner, E., Gray, D. J., and O'Rahilly, R. 1963. Anatomy: a regional study of human structure. p. 7. Second edition. Philadelphia, Pennsylvania, W. B. Saunders Company.
- Hirsch, E. F.
1962 Innervation of human heart. III. Conductive system. Archives of Pathology 74: 427-439.
- Hirsch, E. F.
1963 Innervation of human heart. V. Comparative study of intrinsic innervation of heart in vertebrates. Experimental and Molecular Pathology 2: 384-401.
- Hirsch, E. F., Kaiser, G. C., and Cooper, T.
1964 Experimental heart block in the dog. I. The distribution of nerves, their ganglia, and terminals in the septal myocardium of the dog and the human hearts. Archives of Pathology 78: 523-532.
- Hirsch, E. F., Kaiser, G. C., and Cooper, T.
1965a Experimental heart block in the dog. II. Injuries of the septal nerves. Archives of Pathology 79: 86-107.
- Hirsch, E. F., Kaiser, G. C., and Cooper, T.
1965b Experimental heart block in the dog. III. Distribution of the vagus and sympathetic nerves in the septum. Archives of Pathology 79: 441-451.
- Hoffman, H. H. and Kuntz, A.
1957 Vertebral nerve and plexus. Archives of Surgery 74: 430-437.
- Hopkins, G. S.
1937 Guide to the dissection and study of the blood vessels and nerves of the horse. Third edition. Ithaca, New York, New York Veterinary College at Cornell University.

- Ionescu, D. and Enachescu, M.
 1928 Untersuchungen bei säugetieren und beim menschen über die aus dem, brustgrenystron des sympathicus unterhalb des ganglion stellatum entsprungenen herznerven. Zeitschrift für die Gesamte anatomie 85: 476-489.
- Ionescu, D., Teitel-Bernard, A., Iliescu, C., and Enachescu, M.
 1928 Über die flunktionen der sympathisches thorakelen herznerven. Pflüger's Archiv für die gesamte Physiologie des Menschen und der Tiere 219: 47-58.
- Jackson, C. M.
 1933 Morris' human anatomy. Ninth edition. Philadelphia, Pennsylvania, P. Blakiston's Son and Company, Incorporated.
- Jamieson, R. W.
 1952 The cervical sympathetic ganglia: an anatomical study of 100 cervico-thoracic dissections. Northwestern University Medical School Quarterly Bulletin 26: 219-227.
- Jonnesco, T.
 1923 Le sympathique cervico-thoracique. Paris, France, Masson. Original not available; cited in Wrete, M. 1959. The anatomy of the sympathetic trunks in man. Journal of Anatomy 93: 451.
- Kazem-Beck, A.
 1888 Beitrag zur innervation des herzens. Archiv für Anatomie und Physiologie 12: 325-349.
- Kemper, G. W. H.
 1905 The world's anatomists. Philadelphia, Pennsylvania, P. Blakeston's, Son and Company.
- Koch, T.
 1965 Lehrbuch der veterinär-anatomie. Volume 3. Die grossen versorgungs und steuerungssysteme. Jena, Germany, Veb Gustav Fischer Verlag.
- Kopsch, F.
 1957 Nomina anatomica: vergleichende übersicht der Basler, Jenaer, und Pariser nomenklatur. 5. Auflage. Stuttgart, Germany, Georg Thieme Verlag.
- Koroleva, A. A.
 1957 The thoracic section of the sympathetic trunk in pigs. Uchenye Zapiski Vitebskogo Veterinarnogo Instituta 15: 178-183.

- Kreidmann, A.
1878 Anatomische untersuchungen über den nervus depressor beim menschen und hunde. Archiv für Anatomie und Physiologie 1878: 405-415.
- Kuntz, A.
1949 The neuroanatomic basis of the autonomic nervous system. First edition. Springfield, Illinois, Charles C. Thomas.
- Kuntz, A.
1953 The autonomic nervous system. Fourth edition. Philadelphia, Pennsylvania, Lea and Febiger.
- Larsell, O.
1953 The nervous system. In Morris' human anatomy. pp. 903-1211. Eleventh edition. New York, New York, The Blakiston Company.
- Laubmann, W.
1931 Anatomische studie über den halssympathicus des menschen. Zeitschrift für die gesamte Anatomie 96: 787-805.
- Lavrentiev, B. I.
1946 The innervation of the heart. American Review of Soviet Medicine 3: 229-235.
- Lim Boon Keng, M. B.
1893 On the nervous supply of the dog's heart. Journal of Physiology 14: 467-483.
- Long, D. M., Truex, R. C., Friedmann, K. R., Olsen, A. K., and Phillips, S. J.
1958 Heart rate of the dog following autonomic denervation. Anatomical Record 130: 73-89.
- Ludwig, C.
1848 Über die herznerven des frosches. Archiv für Anatomie, Physiologie, und Wissenschaftliche Medicin 1848: 139-143.
- Luisada, A. A.
1954 Heart: a physiologic and clinical study of cardiovascular diseases. Second edition. Baltimore, Maryland, The Williams and Wilkins Company.
- Mannu, A.
1914 Ricerche anatomo-comperative sul simpatico cervicale nei mammiferi. Internationale Monatsschrift für Anatomie und Physiologie 30:49-168.

- Mannu, A.
1915 Osservazioni sul simpatico cervical die mammiferi. Internationale Monatsschrift für Anatomie und Physiologie 31: 116-127.
- May, N. D. S.
1964 The anatomy of the sheep. Second edition. Brisbane, Queensland, Australia, University of Queensland Press.
- McFadyean, J.
1903 The anatomy of the horse. New York, New York, William R. Jenkins Veterinary Publisher and Bookseller.
- McFadyean, J.
1922 The anatomy of the horse. A dissection guide. Third edition. Edinburgh, Scotland, W. and A. K. Johnston, Limited.
- McLeod, W. M.
1958 Bovine anatomy. Second edition. Minneapolis, Minnesota, Burgess Publishing Company.
- Meyling, H. A. and Borg, H. T.
1957 The conducting system of the heart in hooved animals. Cornell Veterinarian 47: 419-447.
- Miller, M. E.
1962 Guide to the dissection of the dog. Third edition. Ann Arbor, Michigan, Edward Brothers, Inc.
- Miller, M. E., Christensen, G. C., and Evans, H. E.
1964 Anatomy of the dog. Philadelphia, Pennsylvania, W. B. Saunders Company.
- Miller, M. R. and Kasahara, M.
1964 Studies on the nerve endings in the heart. American Journal of Anatomy 115: 217-234.
- Miot, [initials not given]
1876 Recherches physiologiques sur l'innervation du coeur bruxelles. Original not available; cited in Paul, C. 1884. Diagnosis and treatment of diseases of the heart. p. 30. New York, New York, William Wood and Company.
- Mitchell, G. A. G.
1953 Anatomy of the autonomic nervous system. Edinburgh, Scotland, E. and S. Livingstone.

- Mitchell, G. A. G.
1956 Cardiovascular innervation. Edinburgh, Scotland, E. and S. Livingstone.
- Mizeres, N. J.
1955a The anatomy of the autonomic nervous system in the dog. *American Journal of Anatomy* 96: 285-318.
- Mizeres, N. J.
1955b Isolation of the cardioinhibitory branches of the right vagus nerve in the dog. *Anatomical Record* 123: 437-446.
- Mizeres, N. J.
1957 The course of the left cardio-inhibitory fibers in the dog. *Anatomical Record* 127: 109-116.
- Mizeres, N. J.
1958 The origin and course of the cardioaccelerator fibers in the dog. *Anatomical Record* 132: 261-280.
- Mizeres, N. J.
1963 The cardiac plexus in man. *American Journal of Anatomy* 112: 141-151.
- Montané, L. and Bourdelle, E.
1913 Cheval. In Montané, L. and Bourdelle, E., editors. *Anatomie regionale des animaux domestiques*. Volume 1. Paris, France, Librairie J. B. Bailliere et Fils.
- Montané, L. and Bourdelle, E.
1917 Ruminants. In Montané, L. and Bourdelle, E., editors. *Anatomie regionale des animaux domestiques*. Volume 2. Paris, France, Librairie J. B. Bailliere et Fils.
- Netter, F. H.
1962 The ciba collection of medical illustrations. I. Nervous system. Summit, New Jersey, Ciba Pharmaceutical Company.
- Nettleship, W. A.
1936 Experimental studies on the afferent innervation of the cat's heart. *Journal of Comparative Neurology* 64: 115-134.
- Neubauer, J. E.
1772 *Descriptio anatomica nervorum cardiacorum*. Jena, Germany. Original not available; cited in Mannu,

A. 1914. Ricerche anatomo-comparative sul simpatico cervicale nei mammiferi. *International Monatsschrift für Anatomie und Physiologie* 30: 51.

Nomina anatomica

1956 Baltimore, Maryland, The Williams and Wilkins Company.

Nomina anatomica

1961 Second edition. New York, New York, Excerpta Medica Foundation.

Nonidez, J. F.

1936 Observations on the blood supply and innervation of the aortic paraganglion of the cat. *Journal of Anatomy* 70: 215-224.

Nonidez, J. F.

1937a Identification of the receptor areas in the vena cavae and pulmonary veins which initiate reflex cardiac acceleration (Bainbridges reflex). *American Journal of Anatomy* 61: 203-232.

Nonidez, J. F.

1937b Distribution of the aortic nerve fibers and the epithelioid bodies (sypracardial 'paraganglia') in the dog. *Anatomical Record* 69: 299-318.

Nonidez, J. F.

1939 Studies on the innervation of the heart. I. Distribution of the cardiac nerves, with special reference to the identification of the sympathetic and parasympathetic postganglionies. *American Journal of Anatomy* 65: 361-401.

Paul, C.

1884 Diagnosis and treatment of diseases of the heart. New York, New York, William Wood and Company.

Perman, E.

1924 Anatomische untersuchung über die herznerven bei den höheren säugetieren und bei menschen. *Zeitschrift für die Gesamte Anatomie* 71: 382-457.

Phillips, S. J.

1965 Innervation of the heart and major vessels. In Mills, J. and Moyer, J. H., editors. Shock and hypotension. pp. 10-21. New York, New York, Grune and Stratton, Incorporated.

- Purkinje, J. E.
1845 Microscopisch-neurologische beobachtungen. Archiv für Anatomie, Physiologie und Wissenschaftliche Medicin 7: 281-295.
- Randall, W. C.
1965 Nervous control of the heart. Baltimore, Maryland, The Williams and Wilkins Company.
- Randall, W. C., McNally, N., Cowan, J., Caliguiri, L., and Rohse, W. G.
1957 Functional analysis of the cardioaugmentor and cardioaccelerator pathways in the dog. American Journal of Physiology 191: 213-217.
- Randall, W. C., Priola, D. V., Ulmer, R. H.
1963 A functional study of distribution of cardiac sympathetic nerves. American Journal of Physiology 205: 1227-1231.
- Ransom, W. B.
1884 On the cardiac rhythm of invertebrata. Journal of Physiology 5: 261-341.
- Ransom, S. W. and Billingsley, P. R.
1918 The thoracic truncus sympathicus, rami communicantes and splanchnic nerves in the cat. Journal of Comparative Neurology 29: 405-440.
- Reighard, J. and Jennings, H. S.
1935 Anatomy of the cat. New York, New York, Henry Holt and Company.
- Remak, R.
1838 Ueber die berichtungen des organischen nervensystem. Neue Notizen aus dem Gebiete der Natur-und Heilkunde (Froriep) 7: 65-70. Original not available; cited in Davies, F., Francis, E. T. B., and King, T. S. 1952. Neurological studies of the cardiac ventricles of mammals. Journal of Anatomy 86: 130.
- Remak, R.
1839 Über die ganglien der herznerven des menschen und deren physiologische bedeutung. Wochenschrift für die Gesammte Heilkunde 10: 149-154. Original not available; cited in Davis, F., Francis, E. T. B., and King, T. S. 1952. Neurological studies of the cardiac ventricles of mammals. Journal of Anatomy 86: 130.

- Remak, R.
1844 Neurologische erläuterungen. Archiv für Anatomie, Physiologie und Wissenschaftliche Medicin 6: 463-472.
- Reynier, [initials not given]
1880 Des nerfs du coeuru, anatomie et physiologie. These d'agregation, Paris, France. Original not available; cited in Paul, C. 1884. Diagnosis and treatment of diseases of the heart. pp. 38. New York, New York, William Wood and Company.
- Rooney, J. R., II.
1956 Guide to the dissection of the horse. Third edition. Ann Arbor, Michigan, J. W. Edwards, Publisher, Incorporated.
- Sacomanno, G.
1943 The components of the upper thoracic sympathetic nerves. Journal of Comparative Neurology 78-79: 355-378.
- Scarpa, [initials not given]
1794 Tabulae Neurologicae. Ticini. Original not available; cited in Davies, F., Francis, E. T. B., and King, T. S. 1952. Neurological studies of the cardiac ventricles of mammals. Journal of Anatomy 86: 130.
- Schmaltz, R.
1911 Atlae der anatomie des pferdes. Teil II. Berlin, Germany, Verlagsbuchhandlung von Richard Schoetz.
- Schmaltz, R.
1927 Atlas der anatomie des pferdes. IV. Die eingeweide. Berlin, Germany, Verlagsbuchhandlung von Richard Schoetz.
- Schmiedeberg, O.
1871 Ueber die innervationsverhältnisse des hundeherzens. Sächsischen Akademie der Wissenschaften Mathematisch-Physische Classe Berichte 23: 148-170.
- Schreiber, J., Frewein, J., and Walter, P.
1963 Systema nervosum autonomicum. Unpublished typewritten report proposed to the International Commission for Veterinary Anatomical Nomenclature. Hanover, Germany, Section, Division, Gebiet VI.

- Schumacher, S.
1902 Zur frage der herzzinnervation bei den saugetieren.
Anatomischer Anzeiger 21: 1-7.
- Schurawlew, A. N.
1928 Die herznerven des hundes. Zeitschrift für die
Gesamte Anatomie 86: 655-697.
- Senac, J. B.
1749 Traité de la structure du coeur, de son action et
de ses maladies. Paris, France, J. Vincent. pp.
116-138. Original not available; cited in
Mizeres, N. J. 1963. The cardiac plexus in man.
American Journal of Anatomy 112: 141.
- Silverman, E. H.
1963 Zur topographie des nervus vertebratis bei
wiederkäuer und fleischfresser. Inaugural
dissertation, Munich, Germany, Ludwig-Maximilians-
Universität zu München.
- Sisson, S. and Grossman, J. D.
1953 The anatomy of the domesticated animals. Fourth
edition. Philadelphia, Pennsylvania, W. B.
Saunders Company.
- Stromberg, M. W.
1964 The autonomic nervous system. In Miller, M. E.,
Christensen, G. C., and Evans, H. E. Anatomy of
the dog. pp. 626-644. Philadelphia, Pennsylvania,
W. B. Saunders Company.
- Strangeways, T.
1917 Veterinary anatomy. Tenth edition. Chicago,
Illinois, Chicago Medical Book Company.
- Tagand, R. and Barone, R.
1964 Anatomie des equides domestiques. Fascicule II.
Nerfs-système sympathique, glandes endocrines.
Lyon, France, Laboratoire d'Anatomie, Ecole
Nationale Veterinaire.
- Taylor, W. T. and Weber, R. J.
1951 Functional mammalian anatomy. New York, New York,
D. Van Nostrand Company, Incorporated.
- Tcheng, K. T.
1949 Innervation du myocarde et du faisceau de His chez
deux mammiferes, le mouton et le chat. Cardiologia
15: 227-265.

- Tcheng, K. T.
1951 Innervation of the dogs heart. *American Heart Journal* 41: 512-523.
- Teitelbaum, H. A.
1933 The nature of the thoracic and abdominal distribution of the vagus nerve. *Anatomical Record* 55: 297-317.
- Truex, R. C.
1955 Effect of vagus nerves on heart rate of young: an anatomic-physiologic study. *Anatomical Record* 123: 201-226.
- Truex, R. C. and Carpenter, M. R.
1964 *Strong and Elwyn's human neuroanatomy*. Fifth edition. Baltimore, Maryland, Williams and Wilkins Company.
- Usenik, E. A.
1957 Sympathetic innervation of the head and neck of the horse: neuropharmacological studies of sweating in the horse. Unpublished Ph.D. thesis. Minneapolis, Minnesota, Library, University of Minnesota.
- Verity, M. A., Hughes, T., and Bevan, J. A.
1965 Innervation of the pulmonary artery bifurcation of the cat. *American Journal of Anatomy* 116: 75-90.
- Vesalius, A.
1543 *De Humani corporis fabrica*. Basel, Switzerland. Original not available; cited in Vesalius, A. 1950. *Illustrations from the works of Andreas Vesalius of Brussels: with annotations and translations by Saunders, J. B., deC. M. and O'Malley, C. D.* p. 9. Cleveland, Ohio, The World Publishing Company.
- Veterinary Anatomists World Association
1963 *Nomina anatomica veterinaria. Pars Prima*. Hannover, Germany, Author.
- Vieussens, R.
1685 *Neurographia universalis*. Original not available; cited in Perman, E. 1924. *Anatomische untersuchungen über die herznerven bei den höheren säugetieren und bei menschen*. *Zeitschrift für die Gesamte Anatomie* 71: 425.

- Viti, A.
1884 Recherches de morphologie sur le nerf depresseur chez l'homme et chez les autres mammiferes. Archives Italiennes de Biologie 5: 191-198.
- Waites, G. M. H.
1957 The course of the efferent cardiac nerves of the sheep. Journal of Physiology 139: 417-433.
- Walmsley, T.
1929 The heart. In Sharpey-Schafer, E., Symington, J., and Bryce, T. H., editors. Quain's anatomy. Eleventh edition. Volume 4, Part 3. London, England, Longmans, Green and Company.
- Wensing, C. J. G.
1964 The conductive system and its nervous component in the pigs heart. Ph.D. thesis, State University of Utrecht. Utrecht, Holland, Uitgeverij G. Van Dijk N. V., Breukelen.
- Wensing, C. J. G.
1965a Evidence for neurogenic conduction in the mammalian heart. Nature 207: 1375-1377.
- Wensing, C. J. G.
1965b Innervation des atrioventricularen reizleitungssystemen beim schwein. Zentralblatt für Veterinärmedizin 12: 531-533.
- White, J. C. and Smithwick, R. H.
1952 The autonomic nervous system. Third edition. New York, New York, Macmillan.
- Willis, T.
1664 Cerebri anatome, cui accessit nervorum descriptio et usus. London, England. Original not available; cited in Kuntz, A. 1953. The autonomic nervous system. Fourth edition. p. 16. Philadelphia, Pennsylvania, Lea and Febiger.
- Winslow, J. B.
1732 Exposition anat. de la structure du corps humain. Paris, France. Original not available; cited in Kuntz, A. 1953. The autonomic nervous system. Fourth edition. p. 17. Philadelphia, Pennsylvania. Lea and Febiger.
- Wolhynski, F. A.
1928a Die herznerven des kalbes. Zeitschrift für die Gesamte Anatomie 86: 579-607.

- Wolhynski, T.
1928b Innervation des herzkammer und vorhofsseptums des kalbes. Zeitschrift für die Gesamte Anatomie 86: 608-638.
- Wollard, H. H.
1926 The innervation of the heart. Journal of Anatomy 60: 345-373.
- Wrete, M.
1959 The anatomy of the sympathetic trunks in man. Journal of Anatomy 93:448-459.

ACKNOWLEDGMENT

The author wishes to express his gratitude to his major professor, Dr. Robert Getty, Head, Department of Veterinary Anatomy, for the opportunity to matriculate under his authoritative tutorage and particularly for his guidance and support during this present study. I also wish to thank Dr. Hugo Godinho for his aid with French and Italian translations, Dr. Nani Ghoshal for his aid with German translations, and particularly Dr. Bernard Skold for his inexhaustible willingness to repeatedly translate German articles. I wish to acknowledge the efforts of Miss Linda Hostetler in typing my rough drafts and Mrs. Renette Peterson for typing the final thesis. The cooperation and technical skill of Dr. D. J. Hillmann in photographing the specimens was greatly appreciated. To Mr. Ronald Hamm I extend my esteem for his artistic abilities and my thanks for his cooperation in illustrating the cardiac innervation. Of ultimate importance was the encouragement, and endurance of my wife Martha and our three children Janet, Carey, and James. Lastly, I wish to express my appreciation to Dr. G. C. Christensen the exemplar who initially stimulated my interest in veterinary anatomy.

CUMULATIVE KEY TO THE FIGURES

Nerves and Ganglia

- | | |
|---|---|
| <p>1 Ramus communicans
 2 Sympathetic trunk
 3 Thoracic ganglion
 3a First thoracic ganglion
 3b Second thoracic ganglion
 3c Third thoracic ganglion
 3d Fourth thoracic ganglion
 3e Fifth thoracic ganglion
 3f Sixth thoracic ganglion
 3g Seventh thoracic ganglion
 3h Eighth thoracic ganglion
 3j Ninth thoracic ganglion
 4 Cervicothoracic ganglion
 5 Ansa subclavia (caudal limb)
 5' Ansa subclavia (cranial limb)
 6 Cardiac ganglion of the left intervascular triangle
 7 Intermediate ganglion
 8 Vertebral ganglion
 9 Middle cervical ganglion
 10 Cranial cervical ganglion
 11 Vagus nerve
 12 Right recurrent laryngeal nerve
 12' Left recurrent laryngeal nerve
 13 Thoracic cardiac nerve
 14 Cranial cervicothoracic cardiac nerve
 14' Dorsal caudal cervicothoracic cardiac nerve
 14'' Ventral caudal cervicothoracic cardiac nerve
 15 Phrenic nerve
 16 Vertebral Nerve
 17 Intermediate cardiac nerve</p> | <p>18 Cranial vertebral cardiac nerve
 18' Caudal vertebral cardiac nerve
 18'' Medial caudal vertebral cardiac nerve
 18''' Lateral caudal vertebral cardiac nerve
 18'''' Dorsal vertebral cardiac nerve
 19 Middle cervical cardiac nerve
 20 Cranial cervical cardiac nerve
 21 Cranial vagal cardiac nerve
 21' Caudal vagal cardiac nerve
 22 Recurrent cardiac nerve
 23 Sympathetic nerves to phrenic nerve
 24a Eighth cervical spinal nerve
 24b Seventh cervical spinal nerve
 24c Sixth cervical spinal nerve
 24d Fifth cervical spinal nerve
 24e Fourth cervical spinal nerve
 24f Third cervical spinal nerve
 24g Second cervical spinal nerve
 25 Thoracic spinal nerve
 25a First thoracic spinal nerve
 25b Second thoracic spinal nerve
 25c Third thoracic spinal nerve
 25d Fourth thoracic spinal nerve
 25e Fifth thoracic spinal nerve
 25f Sixth thoracic spinal nerve
 25g Seventh thoracic spinal nerve
 25h Eighth thoracic spinal nerve
 25j Ninth thoracic spinal nerve
 26 Vascular nerve
 27 Accessory intraneural ganglion
 28 Cardiac plexes
 29 Inferior ganglion of the vagus nerve</p> |
|---|---|

Structures

A	Rib	N	Common carotid artery
Aa	First rib	N'	Left common carotid artery
Ab	Second rib	N''	Right common carotid artery
Ac	Third rib	O	Right vena azygos
Ad	Fourth rib	O'	Left vena azygos (hemiazygos vein)
Ae	Fifth rib	P	Cranial vena cava
Af	Sixth rib	Q	Caudal vena cava
Ag	Seventh rib	R	Right atrium
Ah	Eighth rib	R'	Right auricle
Aj	Ninth rib	S	Left atrium
B	Longus colli muscle	S'	Left auricle
C	Esophagus	T	Right ventricle
D	Intercostal artery	U	Left ventricle
D'	Intercostal vein	V	Pericardium
E	Aorta	W	Trachea
F	Brachiocephalic artery	X	Bronchus
G	Subclavian artery	X'	Apical bronchus
G'	Left subclavian artery	X''	Primary bronchus
G''	Right subclavian artery	Y	Pulmonary artery
H	Costocervical artery	Y'	Pulmonary vein
H'	Costocervical vein	Z	Lung
I	Transverse colli artery (dorsal artery)	AA	Ligamentum arteriosum
I'	Transverse colli vein	BB	Right coronary artery
J	Supreme intercostal artery (subcostal artery)	BB'	Descending branch of left coronary artery
J'	Supreme intercostal vein	BB''	Circumflex branch of left coronary artery
K	Vertebral artery	CC	Great cardiac vein
K'	Vertebral vein	DD	Coronary sinus
L	Deep cervical artery	EE	Thoracic duct
L'	Deep cervical artery	FF	Middle cardiac vein
M	Costocervico-vertebral artery		
M'	Costocervico-vertebral vein		

APPENDIX A: TABLES

Table 1. Equine: dimensions of the ansa subclavia and of the ganglia of origin for cardiac nerves in millimeters

Equine Number	Approximate Equine Weight In Pounds	Cervicothoracic Ganglion						Vertebral Ganglion						Ansa Subclavia								
		Left			Right			Left			Right			Left				Right				
		Length		Width	Length		Width	Length		Width	Length		Width	Length		Width	Length		Width			
		C-C	D-V	M-L	C-C	D-V	M-L	C-C	D-V	M-L	C-C	D-V	M-L	C-C	D-V	M-L	Cranial Limb	Caudal Limb	Cranial Limb	Caudal Limb	Cranial Limb	Caudal Limb
1	800	55	13	2	40	15	3	15	8	2	15	10	2	20	120	10	2	25	110	10	2	
2	1100	70	10	2	40	8	2	15	7	2	20	5	2	15	160	6	1	35	200	6	2	
3	1000	65	10	2	50	10	2	10	5	2	8	5	2	10	150	6	2	45	150	5	3	
4	700	30	4	1	40	8	2	10	5	2	15	6	2	20	100	4	1	20	90	5	2	
5	200	40	7	2	40	6	2	20	6	2	13	4	2	10	60	5	1	20	80	8	4	

C-C - Craniocaudal D-V - Dorsoventral M-L - Mediolateral

Table 2. Bovine: dimensions of the ansa subclavia and of the ganglia of origin for cardiac nerves in millimeters

Bovine Number	Approximate Bovine Weight In Pounds	Cervicothoracic Ganglion						Vertebral Ganglion						Ansa Subclavia							
		Left			Right			Left			Right			Left				Right			
		Length		Width	Length		Width	Length		Width	Length		Width	Length		Width	Length		Width		
		C-C	D-V	M-L	C-C	D-V	M-L	C-C	D-V	M-L	C-C	D-V	M-L	Cranial Limb	Caudal Limb	Cranial Limb	Caudal Limb	Cranial Limb	Caudal Limb	Cranial Limb	Caudal Limb
1	50	20	7	5	11	6	4	Blends with cervicothor- acic ganglion			8	4	2	2	40	0.5	1.0	25	65	1.5	1.5
2	50	20	8	4	18	8	4	5	2	1	7	2	1.5	20	50	1.5	0.5	25	65	1.3	0.7
3	100	25	8	5	25	3	5	Blends with cervicothor- acic ganglion			15	5	2	0	50	0	.75	50	100	1.5	2.0
4	600	25	7	2	20	6	3	13	4	1	Destroyed		50	70	2.0	2.0	50	110	2.0	2.0	
5	800	25	8	3	20	3	3	Blends with cervicothor- acic ganglion			10	4	2	0	100	0	1.0	60	170	2.0	2.0

C-C - Craniocaudal D-V - Dorsoventral M-L - Mediolateral

Table 3. Ovine: dimensions of the ansa subclavia and of the ganglia of origin for cardiac nerves in millimeters

Ovine Number	Approximate Ovine Weight In Pounds	Cervicothoracic Ganglion						Vertebral Ganglion						Ansa Subclavia										
		Left			Right			Left			Right			Left				Right						
		Length		Width	Length		Width	Length		Width	Length		Width	Length		Width	Length		Width					
		Cranial	Caudal	Cranial	Cranial	Caudal	Cranial	Caudal	Cranial	Caudal	Cranial	Caudal	Cranial	Caudal	Cranial	Caudal	Cranial	Caudal	Cranial	Caudal				
1	110	14	5	3	20	6	3	7	4	2	5	3	1	25	50	2	2	40	70	2	2			
2	120	30	4	4	20	5	3	3	2	2	6	2	1	28	55	3	2	60	85	2	2			
3	120	17	4	3	17	5	3	Two Blended Ganglia			Two Ganglia Each			27	50	2	3	30	55	1	2			
4	110	10	5	3	17	5	3	Two Blended Ganglia			9	2	1	1	1	1	15	55	3	3	30	70	2	2
5	120	22	5	4	10	6	4	3	2	1	8	2	1	30	60	1	1	35	75	1	2			

C-C - Craniocaudal D-V - Dorsoventral M-L - Mediolateral

Table 4. Caprine: dimensions of the ansa subclavia and of the ganglia of origin for cardiac nerves in millimeters

Caprine Number	Approximate Caprine Weight In Pounds	Cervicothoracic Ganglion						Vertebral Ganglion						Middle Cervical Ganglion						Ansa Subclavia								
		Left			Right			Left			Right			Left			Right			Left				Right				
		Length		Width	Length		Width	Length		Width	Length		Width	Length		Width	Length		Width	Length		Width	Length		Width			
		C-C	D-V	M-L	C-C	D-V	M-L	C-C	D-V	M-L	C-C	D-V	M-L	C-C	D-V	M-L	C-C	D-V	M-L	C-C	D-V	M-L	C-C	D-V	M-L	C-C	D-V	M-L
1	90	10	5	3	15	4	3	1	1	1	7	3	2	5	1	1	8	2	1	10	30	2	2	40	20	2	2	
2	110	13	3	2	15	4	3	5	3	2	3	2	1	Blended with Vertebral Ganglion			20	60	2	1	70	30	2	2				
3	80	10	4	2	11	4	2	2	1	1	2	1	1	Grossly Not Identified			6	2	1	10	60	1	1	30	50	2	2	
4	75	10	4	1.5	11	3	2	1	1	1	1	1	1	4	2	1	13	2	1	30	55	1	1	35	55	1	2	
5	80	10	4	2.5	17	3	3	1	1	1	2	2	1	10	2	1	11	3	1	35	55	1	1	30	65	2	2	

C-C - Craniocaudal D-V - Dorsoventral M-L - Mediolateral

Table 5. Porcine: dimensions of the ansa subclavia and of the ganglia of origin for cardiac nerves in millimeters

Porcine Number	Approximate Porcine Weight In Pounds	Cervicothoracic Ganglion						Vertebral Ganglion						Middle Cervical Ganglion						Intermediate Ganglion						Ansa Subclavia														
		Left			Right			Left			Right			Left			Right			Left			Right			Left				Right										
		C-C	D-V	M-L	C-C	D-V	M-L	C-C	D-V	M-L	C-C	D-V	M-L	C-C	D-V	M-L	C-C	D-V	M-L	C-C	D-V	M-L	C-C	D-V	M-L	C-C	D-V	M-L	C-C	D-V	M-L	C-C	D-V	M-L	Length	Width	Length	Width		
		Limb	Limb	Limb	Limb	Limb	Limb	Limb	Limb	Limb	Limb	Limb	Limb	Limb	Limb	Limb	Limb	Limb	Limb	Limb	Limb	Limb	Limb	Limb	Limb	Limb	Limb	Limb	Limb	Limb	Limb	Limb	Limb	Limb	Limb					
1	140	20	4	3	20	3	2	Incorporated Into Cervico- thoracic Ganglion	4	3	1	Grossly Not Identified	Grossly Not Identified	2	2	1	5	3	1	0	30	0	1.5	5	50	2.0	0.8													
2	150	25	3	2	25	4	2	Incorporated Into Cervico- thoracic Ganglion	13	4	2	Grossly Not Identified	Grossly Not Identified	Grossly Not Identified	3	2	1	0	65	0	1	15	60	2.0	1.0															
3	180	8	5	2	10	5	2	Incorporated Into Cervico- thoracic Ganglion	10	2	2	5	2	2	Grossly Not Identified	Grossly Not Identified	2	1	1	Grossly Not Identified				15	60	1.0	0.5													
4	150	20	5	3	25	4	2	Incorporated Into Cervico- thoracic Ganglion	14	4	3	8	3	2	Grossly Not Identified		3	2	1	5	3	2	0	55	0	.5	10	50	3.0	1.0										
5	75	13	3	2	10	5	2	Incorporated Into Cervico- thoracic Ganglion	8	4	2	Grossly Not Identified	Grossly Not Identified	2	1	1	4	2	1	0	35	0	.2	10	30	1.5	1.0													

C-C - Craniocaudal D-V - Dorsoventral M-L - Mediolateral

Table 6. Feline: dimensions of the ansa subclavia and of the ganglia of origin for cardiac nerves in millimeters

Feline Number	Approximate Feline Weight In Pounds	Cervicothoracic Ganglion						Vertebral Ganglion						Intermediate Ganglion						Ansa Subclavia				
		Left			Right			Left			Right			Left			Right			Left Length		Right Width		
		C-C	D-V	M-L	C-C	D-V	M-L	C-C	D-V	M-L	C-C	D-V	M-L	C-C	D-V	M-L	C-C	D-V	M-L	C-C	D-V	Cranial Limb	Caudal Limb	Cranial Limb
1	8	6	4	2	6	4	2	Grossly Unidentified			2	1	1	Grossly Unidentified			Grossly Unidentified			10	23	20	30	
2	8	7	4	2	6	5	2	3	1	1	3	1	1	.5	.5	.5	Grossly Unidentified			10	20	20	30	
3	8	5	3	2	9	4	2	2	1	1	3	1	1	Grossly Not Identified			Grossly Unidentified			7	10	10	20	
4	8	6	4	2	7	5	2	3	1	1	2	2	1	Grossly Not Identified			Grossly Unidentified			8	12	15	25	
5	8	10	4	2	8	5	2	3	1	1	2	1	1	Grossly Not Identified			Grossly Unidentified			8	15	13	20	
6	8	8	4	2	6	4	1	4	1	1	4	1	1	.5	.5	.5	Grossly Unidentified			5	15	20	30	
7	8	7	4	2	7	4	2	4	1	1	3	1	1	Grossly Not Identified			Grossly Unidentified			15	20	13	20	
8	8	7	4	2	7	4	2	4	2	1	6	2	1	4	3	2	Grossly Unidentified			12	18	30	45	
9	8	7	5	2	6	4	2	Grossly Not Identified			Grossly Not Identified			Grossly Not Identified			Grossly Unidentified			15	30	20	35	
10	8	9	4	2	8	8	2	1	1	1	Grossly Not Identified			Grossly Not Identified			Grossly Unidentified			10	25	13	23	
AVERAGE		7	4	2	7	5	2	3	1	1	3	1	1								10	19	17	28

C-C - Craniocaudal D-V - Dorsoventral M-L - Mediolateral

Table 7. Canine: dimensions of the ansa subclavia and of the ganglia of origin for cardiac nerves in millimeters

Canine Number	Approximate Canine Weight In Pounds	Cervicothoracic Ganglion						Vertebral Ganglion						Ansa Subclavia								
		Left			Right			Left			Right			Left		Right		Left		Right		
		Length		Width	Length		Width	Length		Width	Length		Width	Length		Width	Length		Width	Length		Width
		Cranial	Caudal	Cranial	Cranial	Caudal	Cranial	Caudal	Cranial	Caudal	Cranial	Caudal	Cranial	Caudal	Cranial	Caudal	Cranial	Caudal	Cranial	Caudal	Cranial	Caudal
1	90	30	7	3	35	6	2	15	4	3	10	3	2	25	25	2	2	45	50	2	2	
2	60	25	4	2	25	3	1	15	4	3	10	3	2	30	30	1	2	45	55	1	1	
3	30	20	4	3	20	4	3	10	5	2	5	3	2	21	24	2	1	30	35	2	2	
4	35	20	3	2	25	4	1	10	3	2	7	3	2	15	18	3	1	20	33	2	2	
5	35	15	4	2	20	4	2	6	3	2	7	3	2	23	25	1	1	25	40	1	2	

C-C - Craniocaudal D-V - Dorsoventral M-L - Mediolateral

Table 8. Comparative distribution of the cardiac nerves

NERVES	SIDE	Along Right Coronary Artery ^a						Along the Descending and Circumflex Branches of the Left Coronary Artery on the Left Side ^b						Along the Circumflex Branch of the Left Coronary Artery Caudally and on the Right Side ^c						Between the Cranial and Vena Cava ^d									
		E	B	O	CAP	P	CAN	F	E	B	O	CAP	P	CAN	F	E	B	O	CAP	P	CAN	F	E	B	O	CAP	P	CAN	
1. Thoracic Cardiac Nerves	Left	-	-	-	-	-	-	+	-	-	-	-	-	-	+	++	+++	+++	+++	++	-	+	-	-	-	-	-	-	-
	Right	-	-	+	-	+	-	-	++	-	-	-	+	-	-	++	-	-	-	-	-	-	+	++	++	-	++	+	
2. Cervicothoracic Cardiac Nerves	Left	++	++	+	+	-	+	+	++	++	-	+	-	+	++	++	++	++	++	++	-	+	+	-	-	-	-	-	-
	Right	-	-	++	++	++	+	++	++	-	+++	++	++	+	++	++	-	-	-	-	-	-	++	++	++	++	++	++	+
3. Intermediate Cardiac Nerves	Left	-	-	-	-	-	-	-	-	-	-	-	-	-	-	-	-	-	-	+	-	+	-	-	-	-	-	-	
	Right	-	-	-	-	++	-	-	-	-	-	++	-	-	-	-	-	-	-	-	-	-	-	-	-	-	++	-	
4. Vertebral Cardiac Nerves	Left	+++	-	-	+	-	+	+	+++	-	-	+	-	++	+	++	-	-	+	-	+++	++	++	-	-	-	-	-	
	Right	-	-	-	+	++	++	++	+++	-	-	+	++	++	++	++	-	-	-	-	-	-	++	-	-	+	++	++	
5. Middle Cervical Cardiac Nerves	Left	-	-	-	++	-	-	-	-	-	++	-	-	-	-	-	-	-	++	-	-	-	-	-	-	-	-	-	
	Right	-	-	-	++	-	-	-	-	-	++	-	-	-	-	-	-	-	-	-	-	-	-	-	-	++	-	-	
6. Cranial Cervical Cardiac Nerves	Left	+	-	-	-	-	-	+	-	-	-	-	-	-	+	-	-	-	-	-	-	+	-	-	-	-	-		
	Right	-	-	-	-	-	-	+	-	-	-	-	-	-	+	-	-	-	-	-	-	+	-	-	-	-	-		
7. Cranial Vagal Cardiac Nerves	Left	++	++	-	++	-	++	+	++	++	-	++	-	++	+	+	-	-	++	+	++	+	+	-	-	-	-		
	Right	-	-	-	+	-	+	+	-	-	-	+	-	+	+	-	-	-	-	-	-	-	-	-	-	+	-		
8. Caudal Vagal Cardiac Nerves	Left	-	-	-	-	-	-	+	-	-	-	-	-	+	++	++	++	++	++	++	-	++	-	-	-	-	-		
	Right	-	-	++	++	++	++	++	-	++	++	++	++	++	++	-	-	-	-	-	-	-	++	++	++	++	++	++	
9. Recurrent Cardiac Nerves	Left	-	-	-	+	-	+	-	-	-	+	-	+	-	-	-	+	++	++	++	++	-	-	-	-	+	-		
	Right	-	-	+	++	++	++	+	++	-	-	++	++	++	+	++	-	-	-	-	-	-	++	+	-	+	++		

E = Equine P = Porcine - = Not followed to this area
 B = Bovine CAN = Canine + = Some may supply the area
 O = Ovine F = Feline ++ = Moderate supply to the area
 CAP = Caprine +++ = Major supply to the area

^aMain distribution includes the right auricle, atrium and ventricle.

^bMain distribution includes the left auricle, left ventricle on the left side, left interventricular septum and the left cranial portion of the

^cMain distribution includes the dorsum of the left auricle, ventrum of the left atrium, caudal and right sides of the left ventricle, right into right ventricle.

^dMain distribution includes the lateral right atrial wall towards the sinoatrial node and sometimes the extension across the coronary groove in

^eMain distribution may include the left atrium, right atrium, right side of the left ventricle, interatrial and interventricular septa on the r

^fMain distribution to dorsal atrial walls, great vessels, and area for intermingling of incoming branches which may then pass with major branch

Table 8. (Continued)

Along the Circumflex Branch of the Left Coronary Artery Caudally and on the Right Side ^c						Between the Cranial and Caudal Vena Cava ^d						Between the Caudal Vena Cava and Left Atrium ^e						Cardiac Plexus ^f									
E	B	O	CAP	P	CAN	F	E	B	O	CAP	P	CAN	F	E	B	O	CAP	P	CAN	F	E	B	O	CAP	P	CAN	F
++	+++	+++	+++	++	-	+	-	-	-	-	-	-	+	-	-	-	-	-	-	-	+	+	+	-	+	+	+
++	-	-	-	-	-	-	+	++	++	-	++	+	+	-	-	-	-	-	-	-	+	+	+	-	+	-	-
++	++	++	++	++	-	++	+	-	-	-	-	-	+	-	-	-	-	-	-	-	++	++	+	+	++	+	+
++	-	-	-	-	-	-	++	++	++	++	++	+	++	++	+	++	+	-	-	-	+	++	++	++	++	++	++
-	-	-	-	+	-	+	-	-	-	-	-	-	-	-	-	-	-	-	-	-	-	-	-	-	+	-	+
-	-	-	-	-	-	-	-	-	-	-	++	-	-	-	-	-	-	-	-	-	-	-	-	-	++	-	-
++	-	-	+	-	+++	++	++	-	-	-	-	-	++	-	-	-	-	-	-	-	++	-	-	+	-	++	+
++	-	-	-	-	-	-	++	-	-	+	++	++	+	++	-	-	-	-	-	++	+	++	-	-	+	++	++
-	-	-	++	-	-	-	-	-	-	-	-	-	-	-	-	-	-	-	-	-	-	-	-	++	+	-	-
-	-	-	-	-	-	-	-	-	-	++	-	-	-	-	-	-	++	-	-	-	-	-	-	++	-	-	-
+	-	-	-	-	-	-	+	-	-	-	-	-	+	-	-	-	-	-	-	-	+	-	-	-	-	-	-
+	-	-	-	-	-	-	+	-	-	-	-	-	+	-	-	-	-	-	-	-	+	-	-	-	-	-	-
+	-	-	++	+	++	+	+	-	-	-	-	-	+	-	-	-	-	-	-	-	+	+	+	++	+	++	+
-	-	-	-	-	-	-	-	-	-	+	-	+	-	-	-	-	+	-	-	-	-	+	-	+	+	+	+
++	++	++	++	++	-	++	-	-	-	-	-	-	++	-	++	++	++	++	++	++	+	++	++	++	++	++	++
-	-	-	-	-	-	-	++	++	++	++	++	++	+	++	++	++	++	++	++	++	+	++	++	++	++	++	++
-	-	+	++	++	++	-	-	-	+	-	-	-	-	-	+	+	-	-	-	-	+	+	+	+	++	++	-
++	-	-	-	-	-	-	++	+	-	+	++	-	-	++	+	-	+	-	++	-	++	+	+	++	++	++	+

area
area
the area
area

interventricular septum and the left cranial portion of the right ventricle.
 um, caudal and right sides of the left ventricle, right interatrial and interventricular septa and caudal right surface of the
 e and sometimes the extension across the coronary groove into the right longitudinal sulcus.
 ventricle, interatrial and interventricular septa on the right side, and the right caudal portion of the right ventricle.
 of incoming branches which may then pass with major branches to other five areas.

Figure 1. Equine: Lateral view of the cardiac nerves and related ganglia on the left side of the specimen.

- | | | | |
|------|--|----|-----------------------------------|
| 1 | Ramus communicans | Aa | First rib |
| 2 | Sympathetic trunk | Ab | Second rib |
| 3c | Third thoracic ganglion | Ac | Third rib |
| 4 | Cervicothoracic ganglion | B | Longus colli muscle |
| 5 | Ansa subclavia (caudal limb) | C | Esophagus |
| 5' | Ansa subclavia (cranial limb) | E | Aorta |
| 8 | Vertebral ganglion | F | Brachiocephalic artery |
| 11 | Vagus nerve | G' | Left subclavian (brachial) artery |
| 13 | Thoracic cardiac nerves | H | Costocervical artery |
| 14 | Cranial cervicothoracic cardiac nerve | K | Vertebral artery |
| 14' | Dorsal caudal cervicothoracic cardiac nerve | L | Deep Cervical Artery |
| 14'' | Ventral caudal cervicothoracic cardiac nerve | V | Pericardium |
| 16 | Vertebral nerve | | |
| 18' | Caudal vertebral cardiac nerve | | |
| 20 | Cranial cardiac nerve | | |
| 21 | Cranial vagal cardiac nerve | | |
| 24a | Eighth cervical spinal nerve | | |
| 25a | First thoracic spinal nerve | | |
| 25b | Second thoracic spinal nerve | | |
| 26 | Vascular nerves | | |

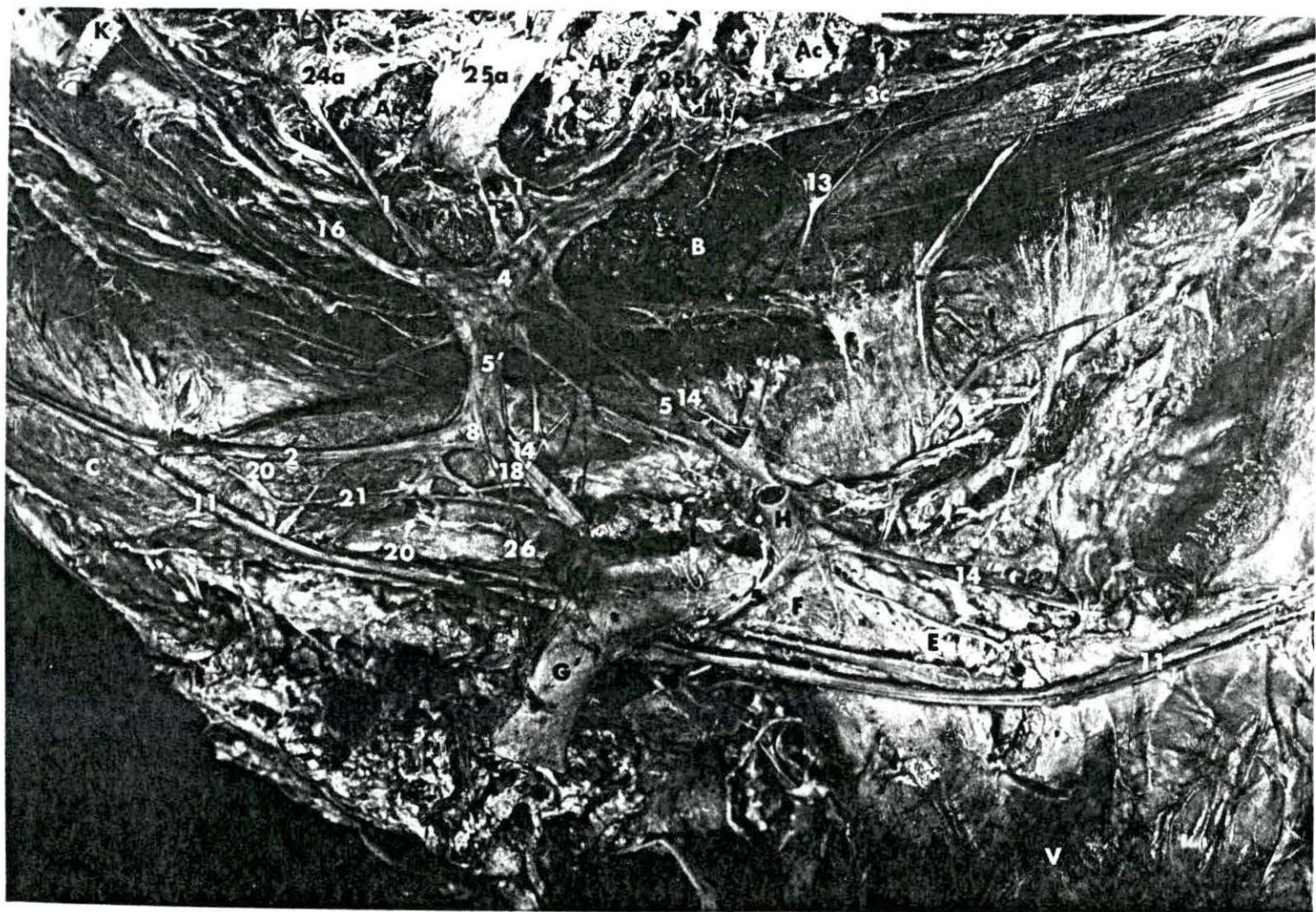

Figure 2. Equine: Lateral view of the cardiac nerves and related ganglia on the right side of the specimen.

- | | | | |
|------|--|-----|------------------------------------|
| 1 | Ramus communicans | Aa | First rib |
| 2 | Sympathetic trunk | Ab | Second rib |
| 3d | Fourth thoracic ganglion | Ac | Third rib |
| 4 | Cervicothoracic ganglion | B | Longus colli muscle |
| 5 | Ansa subclavia (caudal limb) | F | Brachiocephalic artery |
| 5' | Ansa subclavia (cranial limb) | G'' | Right subclavian (brachial) artery |
| 8 | Vertebral ganglion | H | Costocervical artery |
| 11 | Vagus nerve | L | Deep cervical artery |
| 12 | Recurrent laryngeal nerve | K | Vertebral artery |
| 13 | Thoracic cardiac nerve | N'' | Right common carotid artery |
| 14 | Cranial cervicothoracic cardiac nerve | O | Right vena azygos |
| 14' | Dorsal caudal cervicothoracic cardiac nerve | P | Cranial vena cava |
| 14'' | Ventral caudal cervicothoracic cardiac nerve | V | Pericardium |
| 15 | Phrenic nerve | W | Trachea |
| 16 | Vertebral nerve | | |
| 18' | Caudal vertebral cardiac nerve | | |
| 21' | Caudal vagal cardiac nerve | | |
| 23 | Sympathetic nerve to the phrenic nerve | | |
| 24a | Eighth cervical spinal nerve | | |
| 25a | First thoracic spinal nerve | | |
| 25b | Second thoracic spinal nerve | | |
| 26 | Vascular nerve | | |

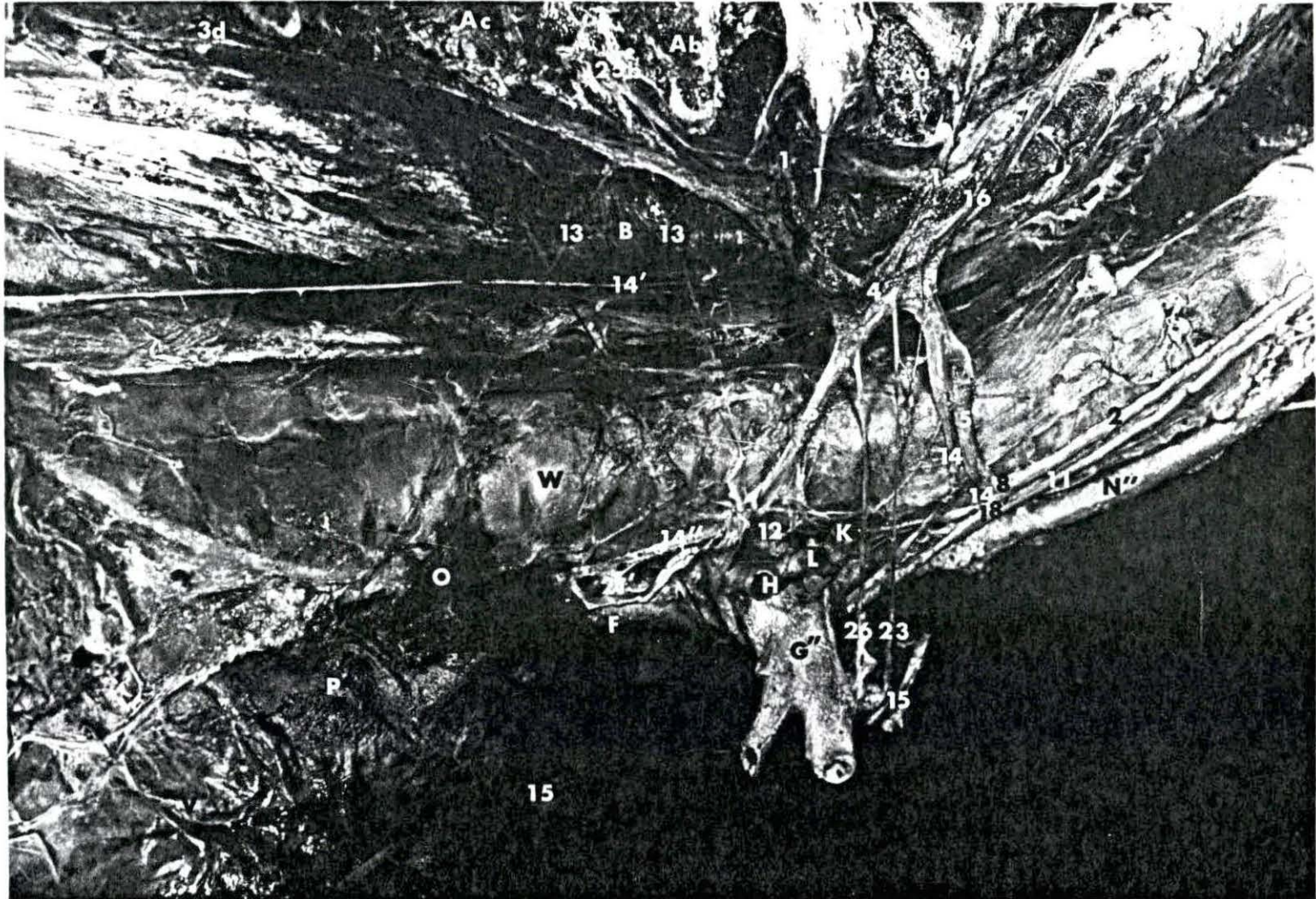


Figure 3. Bovine: Lateral view of the cardiac nerves and related ganglia on the left side of the specimen.

1	Ramus communicans	Aa	First rib
2	Sympathetic trunk	Ab	Second rib
3c	Third thoracic ganglion	Ac	Third rib
3d	Fourth thoracic ganglion	Ad	Fourth rib
3e	Fifth thoracic ganglion	Ae	Fifth rib
3f	Sixth thoracic ganglion	Af	Sixth rib
4	Cervicothoracic ganglion	Ag	Seventh rib
5	Ansa Subclavia (caudal limb)	B	Longus collimuscle
5'	Ansa subclavia (cranial limb)	C	Esophagus
6	Cardiac ganglion of the left inter-vascular triangle	D	Intercostal artery
8	Vertebral ganglion	E	Aorta
11	Vagus nerve	F	Brachiocephalic artery
13	Thoracic cardiac nerves	G'	Left subclavian artery
14'	Dorsal caudal cervicothoracic cardiac nerve	K	Vertebral artery
14''	Ventral caudal cervicothoracic cardiac nerve	L	Deep cervical artery
16	Vertebral nerve	M	Costocervico-vertebral artery
21	Cranial vagal cardiac nerve	N'	Left common carotid artery
24a	Eighth cervical spinal nerve	N''	Right common carotid artery
24b	Seventh cervical spinal nerve	O'	Left vena azygos (vena hemiazygos)
25a	First thoracic spinal nerve	R'	Right auricle
25b	Second thoracic spinal nerve	S'	Left auricle
		T	Right ventricle
		U	Left ventricle
		X	Bronchus
		Y	Pulmonary artery
		AA	Ligamentum arteriosum




Figure 4. Bovine: Lateral view of the cardiac nerves and related ganglia on the right side of the specimen.

1	Ramus communicans	Ab	Second rib
2	Sympathetic trunk	Ac	Third rib
3c	Third Thoracic ganglion	Ad	Fourth rib
3d	Fourth thoracic ganglion	Ae	Fifth rib
4	Cervicothoracic ganglion	Af	Sixth rib
5	Ansa subclavia (caudal limb)	Ag	Seventh rib
5'	Ansa subclavia (cranial limb)	B	Longus collimuscle
8	Vertebral ganglion	C	Esophagus
11	Vagus nerve	E	Aorta
12	Recurrent laryngeal nerve	F	Brachiocephalic artery
13	Thoracic cardiac nerve	G''	Right subclavian artery
14'	Dorsal caudal cervicothoracic cardiac nerve	K	Vertebral artery
14''	Ventral caudal cervicothoracic cardiac nerve	M	Costocervico-vertebral artery
16	Vertebral nerve	N''	Right common carotid artery
21'	Caudal vagal cardiac nerve	O	Right vena azygos
24a	Eighth cervical spinal nerve	P	Cranial vena cava
24b	Seventh cervical spinal nerve	Q	Caudal vena cava
25a	First thoracic spinal nerve	R	Right atrium
25b	Second thoracic spinal nerve	R'	Right auricle
27	Accessory intraneural ganglion	U	Left ventricle
		W	Trachea
		X'	Apical bronchus
		X''	Primary bronchus

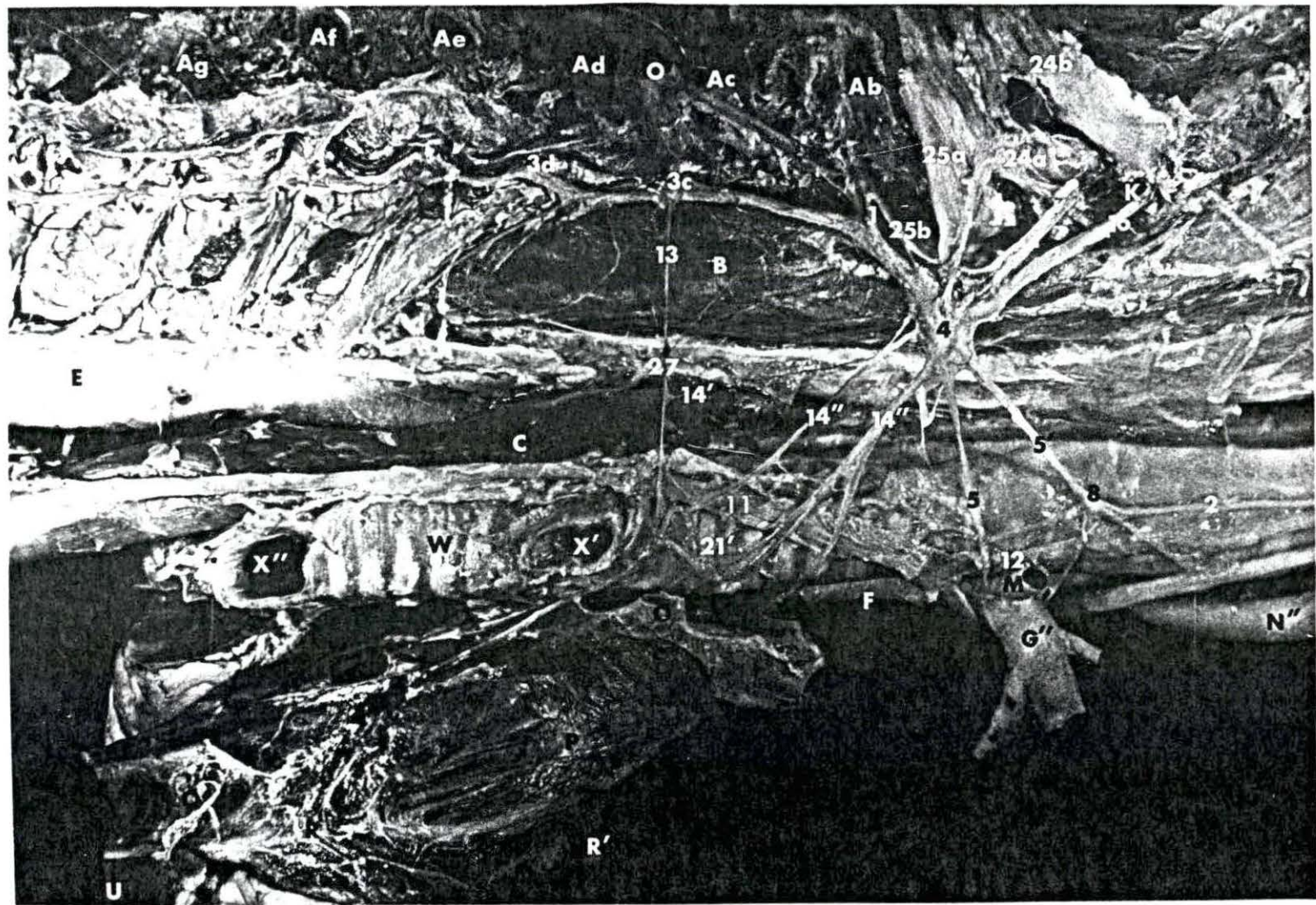


Figure 5. Ovine: Lateral view of the cardiac nerves and related ganglia on the left side of the specimen.

- | | | | |
|-----|---|----|------------------------------------|
| 1 | Ramus communicans | Aa | First rib |
| 2 | Sympathetic trunk | Ab | Second rib |
| 3c | Third thoracic ganglion | Ac | Third rib |
| 3d | Fourth thoracic ganglion | Ad | Fourth rib |
| 3e | Fifth thoracic ganglion | Ae | Fifth rib |
| 4 | Cervicothoracic ganglion | B | Longus colli muscle |
| 5 | Ansa subclavia (caudal limb) | E | Aorta |
| 5' | Ansa subclavia (cranial limb) | F | Brachiocephalic artery |
| 8 | Vertebral ganglion | G' | Left subclavian artery |
| 11 | Vagus nerve | M | Costocervico-vertebral artery |
| 13 | Thoracic cardiac nerves | N' | Left common carotid artery |
| 14" | Ventral caudal cervicothoracic cardiac nerves | O' | Left vena azygos (vena hemiazygos) |
| 16 | Vertebral nerve | S' | Left auricle |
| 21' | Cranial vagal cardiac nerve | T | Right ventricle |
| 24a | Eighth cervical spinal nerve | U | Left ventricle |
| 25a | First thoracic spinal nerve | X | Bronchus |
| | | Y | Pulmonary artery |
| | | Z | Lung |



Figure 6. Ovine: Lateral view of the cardiac nerves and related ganglia on the right side of the specimen.

1	Ramus communicans	Aa	First rib
2	Sympathetic trunk	Ab	Second rib
3c	Third thoracic ganglion	Ac	Third rib
3d	Fourth thoracic ganglion	Ad	Fourth rib
3e	Fifth thoracic ganglion	Ae	Fifth rib
4	Cervicothoracic ganglion	B	Longus colli muscle
5	Ansa subclavia (caudal limb)	C	Esophagus
5'	Ansa subclavia (cranial limb)	G''	Right subclavian artery
8	Vertebral ganglion	H	Costocervical artery
11	Vagus nerve	K	Vertebral artery
12	Recurrent laryngeal nerve	M	Costocervico vertebral trunk
13	Thoracic cardiac nerve	O	Right vena azygos
14'	Dorsal caudal cervicothoracic cardiac nerve	P	Cranial vena cava
14''	Ventral caudal cervicothoracic cardiac nerve	Q	Caudal vena cava
16	Vertebral nerve	R	Right atrium
21	Cranial vagal cardiac nerve	R'	Right auricle
21'	Caudal vagal cardiac nerve	W	Trachea
24a	Eighth cervical spinal nerve	X'	Apical bronchus
25a	First thoracic spinal nerve	X''	Primary bronchus

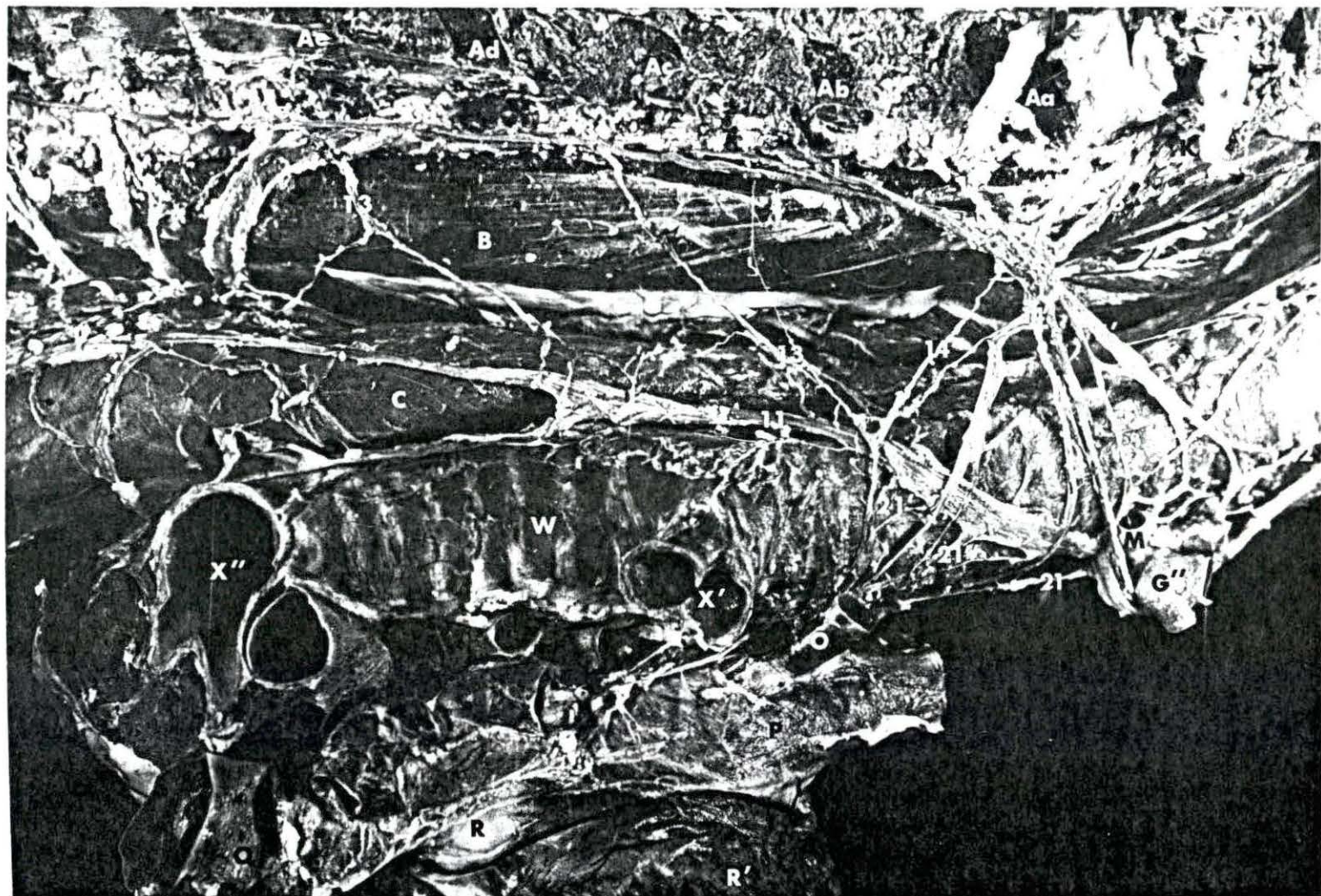


Figure 7. Caprine: Lateral view of the cardiac nerves and related ganglia on the left side of the specimen.

1	Ramus communicans	Aa	First rib
2	Sympathetic trunk	Ab	Second rib
3b	Second Thoracic ganglion	Ac	Third rib
3c	Third thoracic ganglion	Ad	Fourth rib
3d	Fourth thoracic ganglion	Ae	Fifth rib
4	Cervicothoracic ganglion	B	Longus colli muscle
8	Vertebral ganglion	C	Esophagus
9	Middle cervical ganglion	E	Aorta
11	Vagus nerve	F	Brachiocephalic artery
13	Thoracic cardiac nerves	G'	Left subclavian artery
16	Vertebral nerve	H	Costocervical artery
19	Middle cervical cardiac nerve	K	Vertebral artery
21'	Cranial vagal cardiac nerve	M	Costocervico-vertebral artery
24a	Eighth cervical spinal nerve	N'	Left common carotid artery
24b	Seventh cervical spinal nerve	O'	Left vena azygos (vena hemiazygos)
25a	First thoracic spinal nerve	R'	Right auricle
26	Vascular nerves	S'	Left auricle
		X	Bronchus
		Y	Pulmonary artery
		Z	Lung

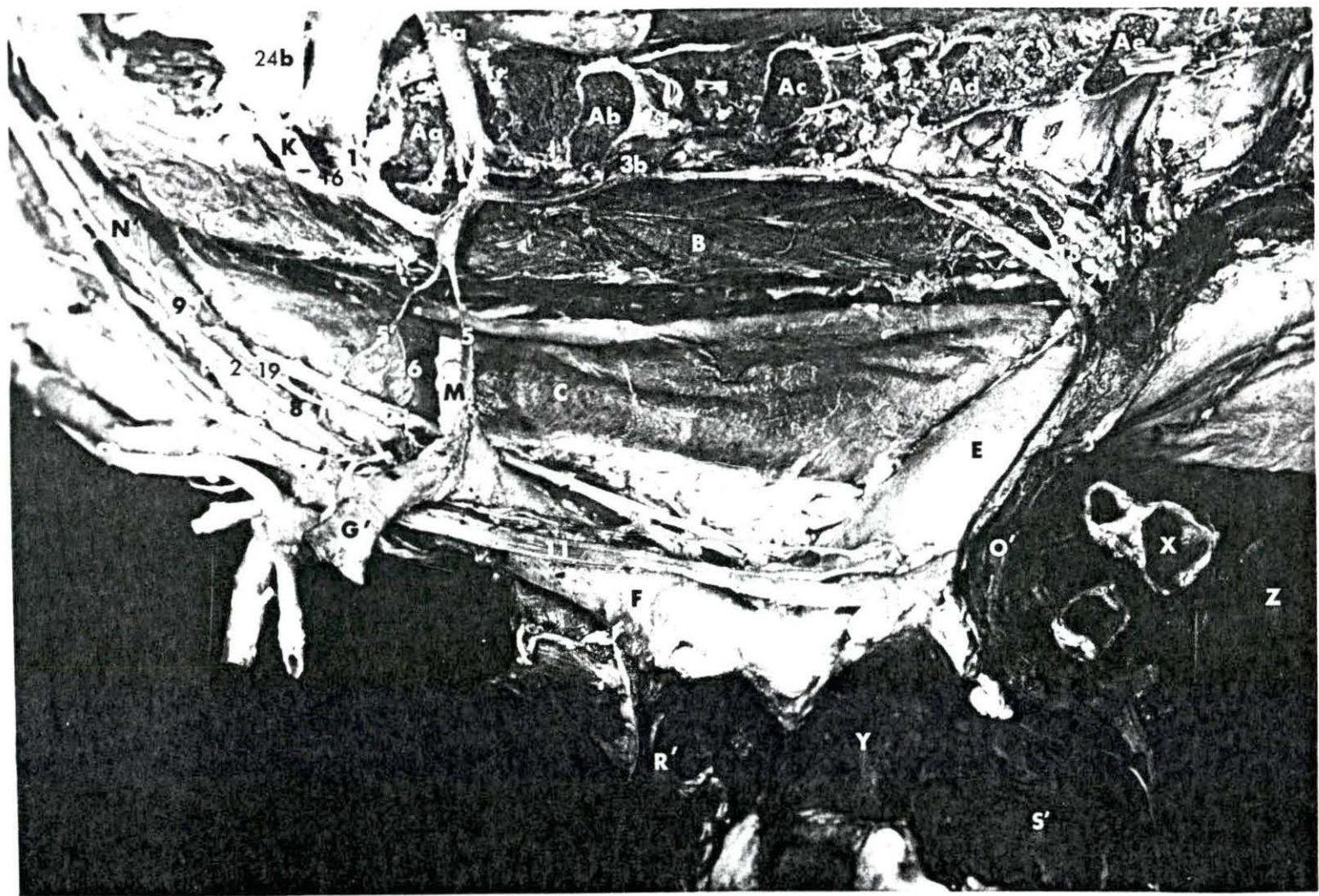


Figure 8. Caprine: Lateral view of the cardiac nerves and related ganglia on the right side of the specimen.

- | | | | |
|-----|---|-----|-------------------------------|
| 1 | Ramus communicans | Aa | First rib |
| 2 | Sympathetic trunk | Ab | Second rib |
| 3b | Second thoracic ganglion | Ac | Third rib |
| 3c | Third thoracic ganglion | B | Longus colli muscle |
| 4 | Cervicothoracic ganglion | C | Esophagus |
| 5 | Ansa subclavia (caudal limb) | G'' | Right subclavian artery |
| 5' | Ansa subclavia (cranial limb) | K | Vertebral artery |
| 8 | Vertebral ganglion | M | Costocervico-vertebral artery |
| 9 | Middle cervical ganglion | N'' | Right common carotid artery |
| 11 | Vagus nerve | P | Cranial vena cava |
| 12 | Right recurrent laryngeal nerve | Q | Caudal vena cava |
| 12' | Left recurrent laryngeal nerve | R | Right atrium |
| 14' | Dorsal caudal cervicothoracic cardiac nerve | R' | Right auricle |
| 16 | Vertebral nerve | U | Left ventricle |
| 19 | Middle cervical cardiac nerves | W | Trachea |
| 21' | Caudal vagal cardiac nerve | X' | Apical bronchus |
| 24a | Eighth cervical spinal nerve | X'' | Primary bronchus |
| 25a | First thoracic spinal nerve | | |




Figure 9. Porcine: Lateral view of the cardiac nerves and related ganglia on the left side of the specimen.

2	Sympathetic trunk	Aa	First rib
3b	Second thoracic ganglion	Ab	Second rib
3c	Third thoracic ganglion	Ac	Third rib
3d	Fourth thoracic ganglion	Ad	Fourth rib
4	Cervicothoracic ganglion	Ae	Fifth rib
5	Ansa subclavia (caudal limb)	B	Longus colli muscle
6	Cardiac ganglion of the left intervascular triangle	C	Esophagus
7	Intermediate ganglion	E	Aorta
9	Middle cervical ganglion	G'	Left subclavian artery
11	Vagus nerve	H	Costocervical artery
12	Recurrent laryngeal nerve	K	Vertebral artery
13	Thoracic cardiac nerve	L	Deep cervical artery
14	Cranial cervicothoracic cardiac nerve	N'	Left common carotid artery
16	Vertebral nerve	O'	Left vena azygos
17	Intermediate cardiac nerve	R'	Right auricle
21	Cranial vagal cardiac nerve	S'	Left auricle
24a	Eighth cervical spinal nerve	T	Right ventricle
24b	Seventh cervical spinal nerve	X	Bronchus
27	Accessory intraneural ganglion	Y	Pulmonary artery

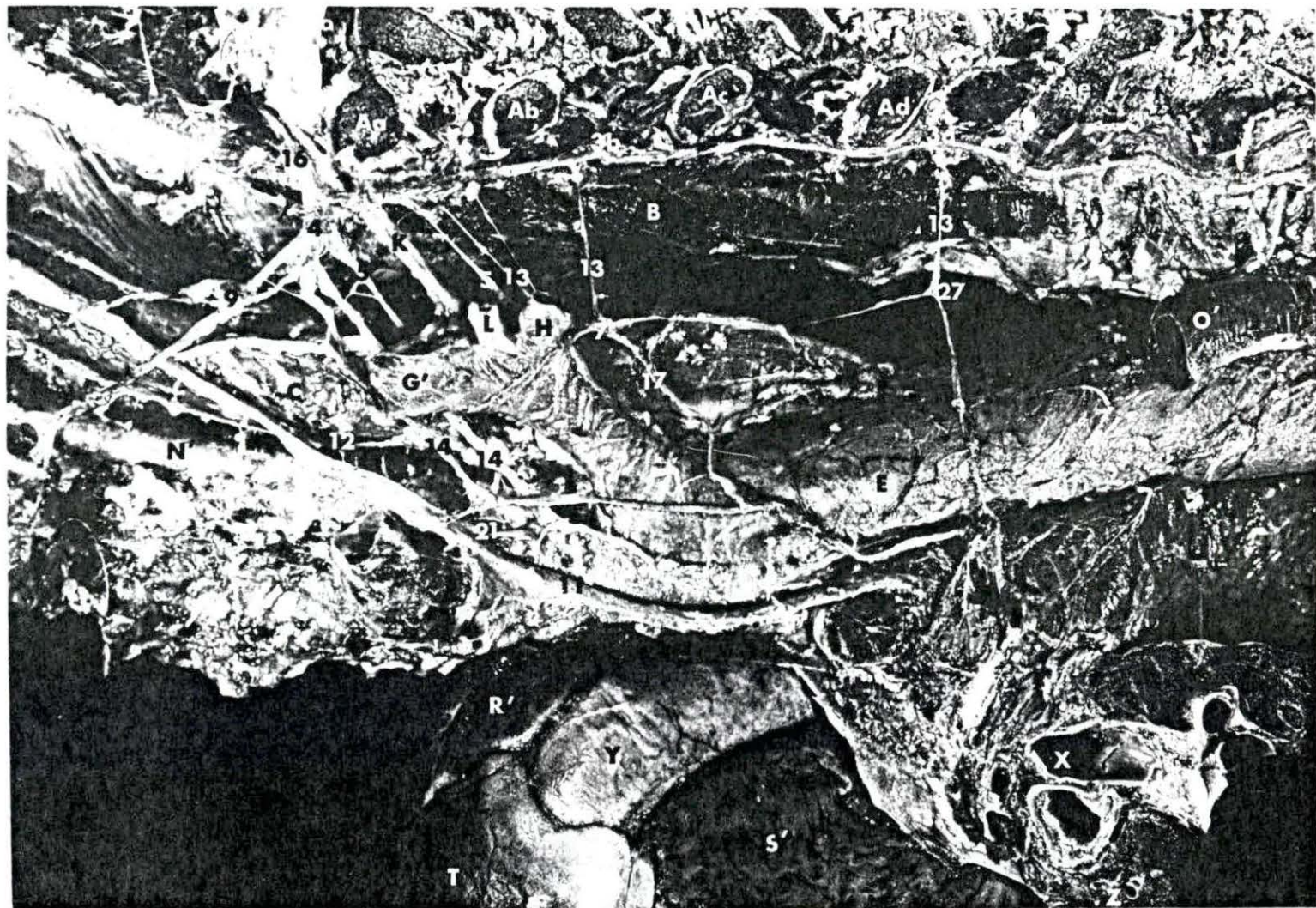


Figure 10. Porcine: Lateral view of the cardiac nerves and related ganglia on the right side of the specimen.

- | | | | |
|-----|---|----|-------------------------------|
| 1 | Ramus communicans | Aa | First rib |
| 2 | Sympathetic trunk | Ab | Second rib |
| 3a | First thoracic ganglion | Ac | Third rib |
| 3b | Second thoracic ganglion | B | Longus colli muscle |
| 3c | Third thoracic ganglion | G" | Right subclavian artery |
| 4 | Cervicothoracic ganglion | K | Vertebral artery |
| 5 | Ansa subclavia (caudal limb) | M | Costocervico-vertebral artery |
| 5' | Ansa subclavia (cranial limb) | N" | Right common carotid artery |
| 7 | Intermediate ganglion | O | Right vena azygos |
| 8 | Vertebral ganglion | P | Cranial vena cava |
| 11 | Vagus nerve | Q | Caudal vena cava |
| 12 | Recurrent laryngeal nerve | R | Right atrium |
| 13 | Thoracic cardiac nerve | R' | Right auricle |
| 14" | Ventral caudal cervicothoracic cardiac nerves | U | Left ventricle |
| 16 | Vertebral nerve | W | Trachea |
| 17 | Intermediate cardiac nerves | X | Bronchus |
| 21' | Caudal vagal cardiac nerve | | |
| 24a | Eighth cervical cardiac nerve | | |
| 24b | Seventh cervical cardiac nerve | | |
| 25a | First thoracic cardiac nerve | | |
| 26 | Vascular nerves | | |
| 27 | Accessory intraneural ganglion | | |

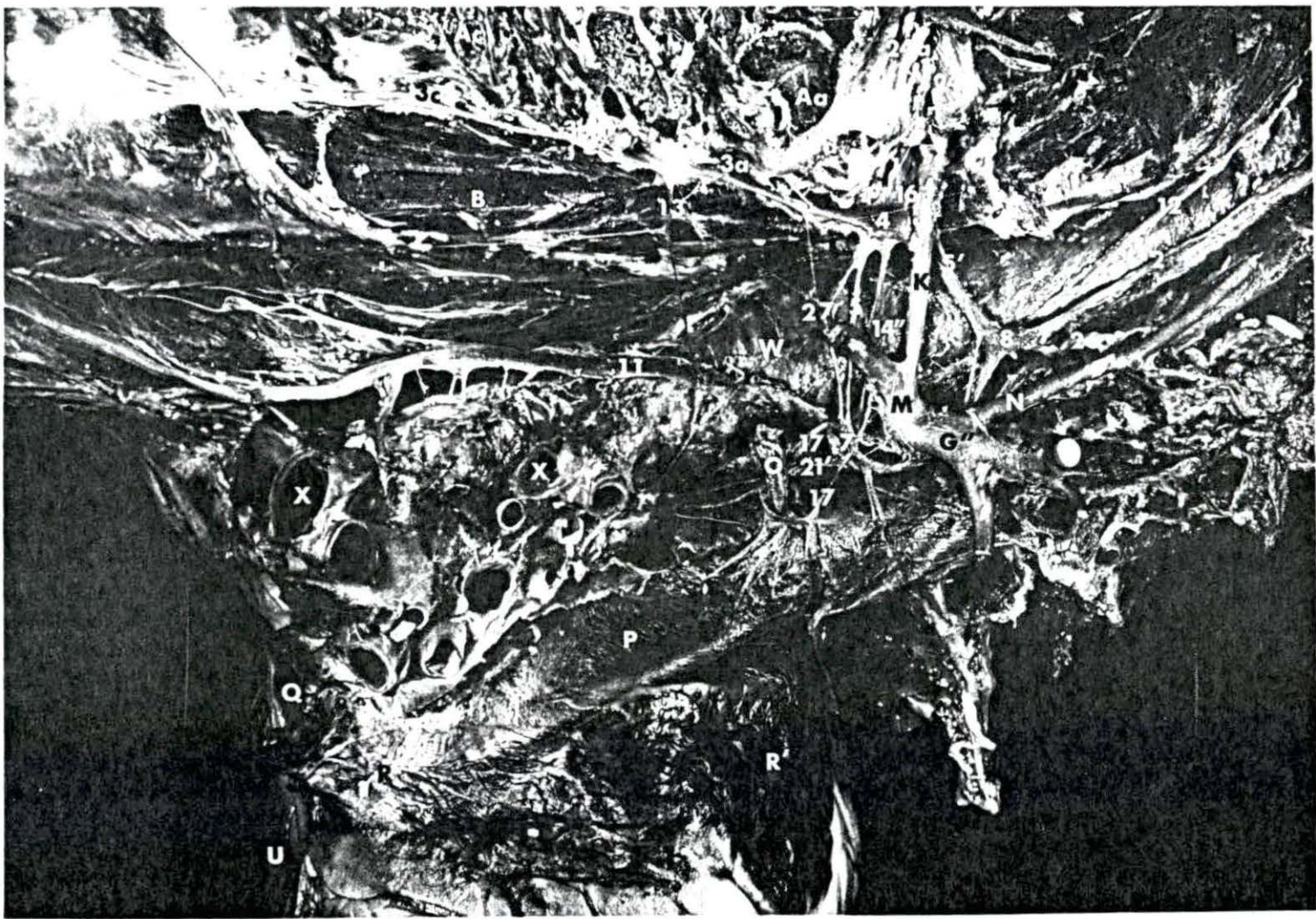


Figure 11. Feline: Lateral view of the cardiac nerves and related ganglia on the right side of the specimen.

- | | | | |
|------|--|-----|-------------------------|
| 1 | Ramus communicans | Aa | First rib |
| 2 | Sympathetic trunk | Ab | Second rib |
| 3c | Third thoracic ganglion | Ac | Third rib |
| 3d | Fourth thoracic ganglion | Ad | Fourth rib |
| 4 | Cervicothoracic ganglion | B | Longus colli muscle |
| 5 | Ansa subclavia (caudal limb) | C | Esophagus |
| 5' | Ansa subclavia (cranial limb) | F | Brachiocephalic artery |
| 8 | Vertebral ganglion | G'' | Right subclavian artery |
| 11 | Vagus nerve | H | Costocervical artery |
| 12 | Recurrent laryngeal nerve | K | Vertebral artery |
| 13 | Thoracic cardiac nerve | O | Right vena azygos |
| 14'' | Ventral caudal cervicothoracic cardiac nerve | P | Cranial vena cava |
| 16 | Vertebral nerve | Q | Caudal vena cava |
| 18' | Caudal vertebral cardiac nerve | R | Right atrium |
| 21' | Caudal vagal cardiac nerve | R' | Right auricle |
| 24a | Eighth cervical spinal nerve | T | Right ventricle |
| 24b | Seventh cervical spinal nerve | U | Left ventricle |
| 24c | Sixth cervical spinal nerve | W | Trachea |
| 25a | First thoracic spinal nerve | X | Bronchus |

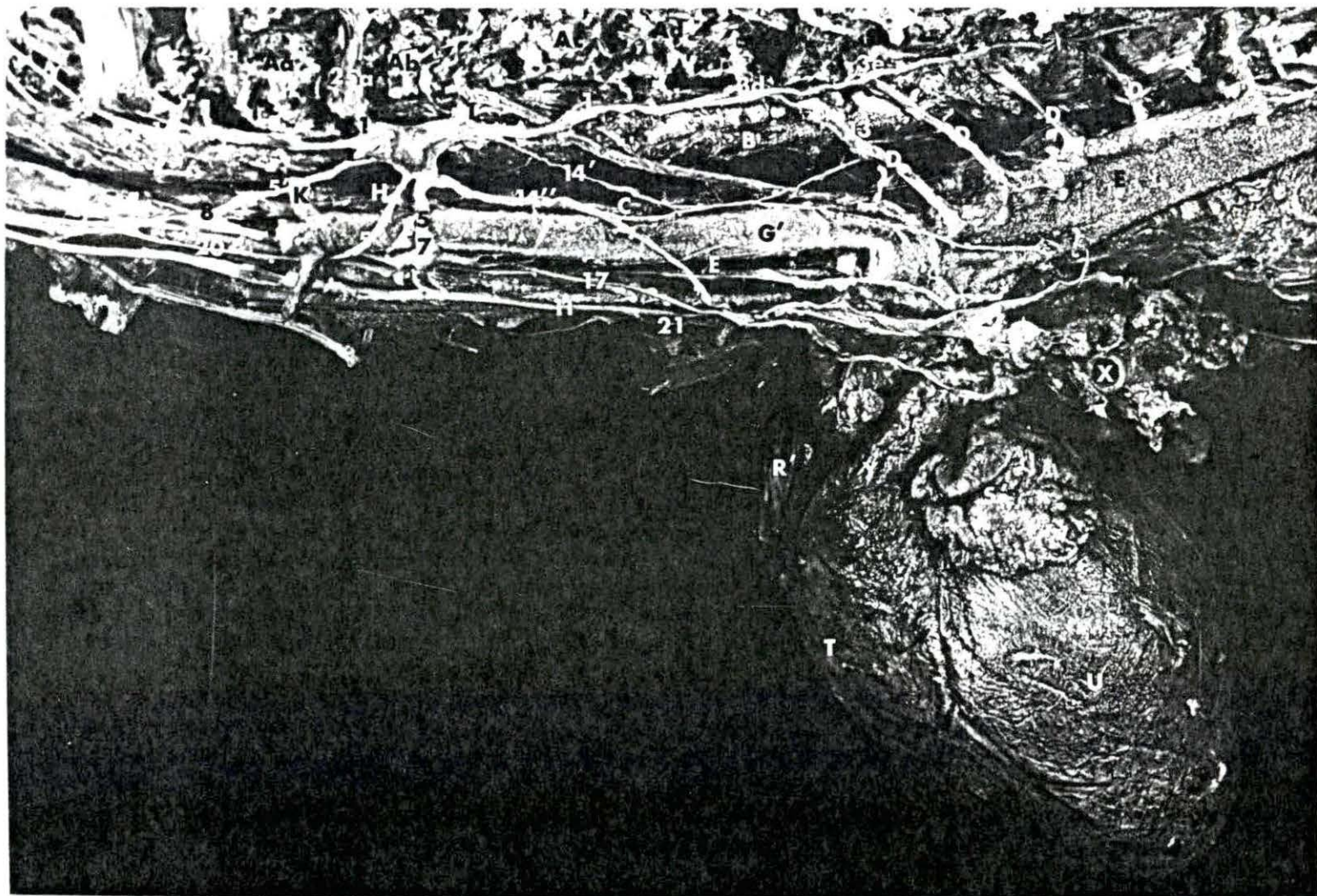


Figure 12. Feline: Lateral view of the cardiac nerves and related ganglia on the left side of the specimen.

- | | | | |
|------|--|----|------------------------|
| 1 | Ramus communicans | Aa | First rib |
| 2 | Sympathetic trunk | Ab | Second rib |
| 3d | Fourth thoracic ganglion | Ac | Third rib |
| 3e | Fifth thoracic ganglion | Ad | Fourth rib |
| 4 | Cervicothoracic ganglion | B | Longus collimuscle |
| 5 | Ansa subclavia (caudal limb) | C | Esophagus |
| 5' | Ansa subclavia (cranial limb) | D | Intercostal artery |
| 7 | Intermediate ganglion | E | Aorta |
| 8 | Vertebral ganglion | G' | Left subclavian artery |
| 11 | Vagus nerve | H | Costocervical artery |
| 13 | Thoracic cardiac nerve | K | Vertebral artery |
| 14' | Dorsal caudal cervicothoracic cardiac nerve | R' | Right auricle |
| 14'' | Ventral caudal cervicothoracic cardiac nerve | S' | Left auricle |
| 16 | Vertebral nerve | T | Right ventricle |
| 17 | Intermediate cardiac nerve | U | Left ventricle |
| 20 | Cranial cardiac nerve | X | Bronchus |
| 21 | Cranial vagal cardiac nerve | Y | Pulmonary artery |
| 24a | Eighth cervical spinal nerve | | |
| 24b | Seventh cervical spinal nerve | | |
| 25a | First thoracic spinal nerve | | |

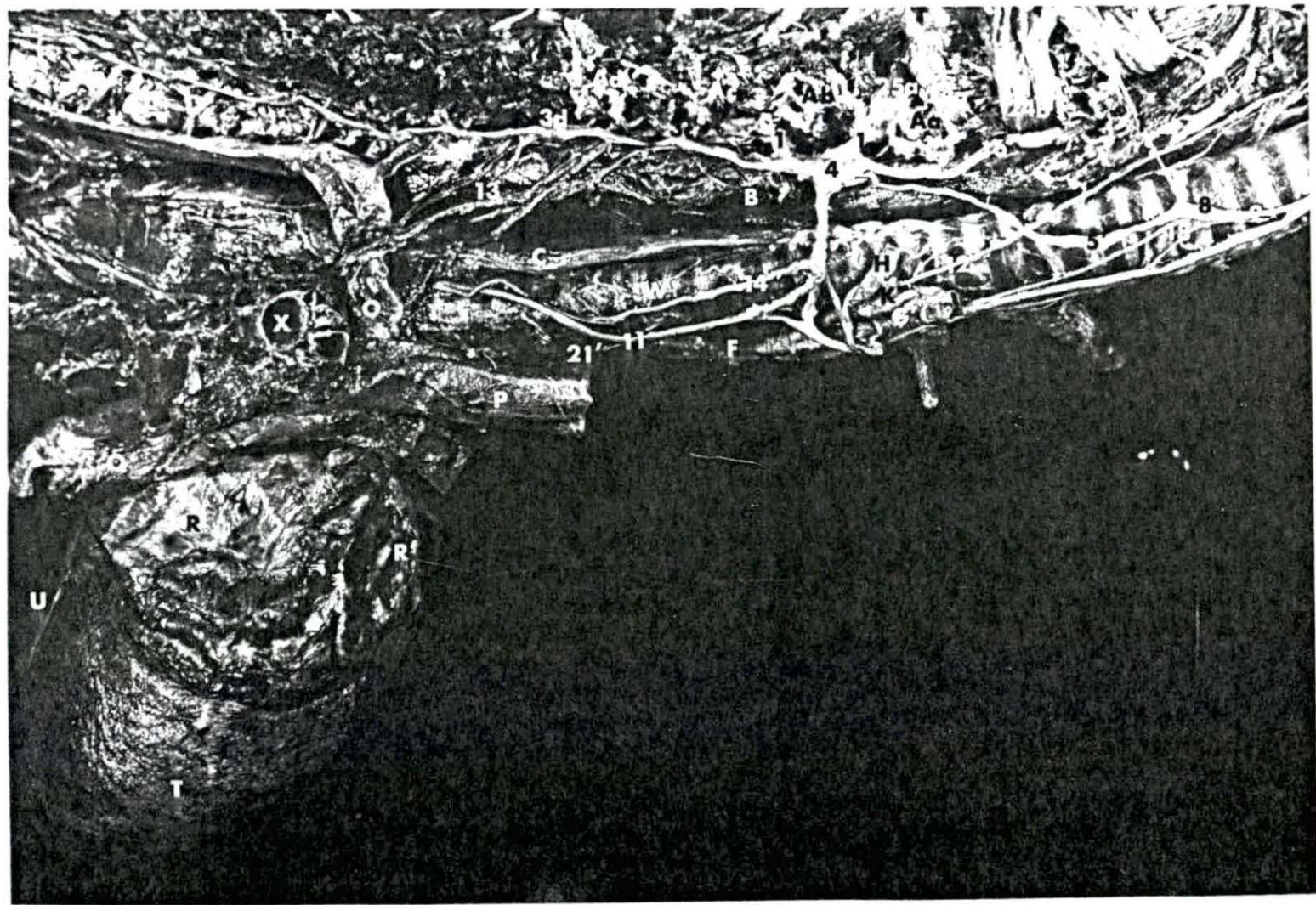


Figure 13. Canine: Lateral view of the cardiac nerves and related ganglia on the left side of the specimen.

1	Ramus communicans	Ab	Second rib
3e	Fifth thoracic ganglion	Ac	Third rib
3f	Sixth thoracic ganglion	Ad	Fourth rib
3g	Seventh thoracic ganglion	Ae	Fifth rib
4	Cervicothoracic ganglion	Af	Sixth rib
5	Ansa subclavia (caudal limb)	B	Longus collimuscle
5'	Ansa subclavia (cranial limb)	C	Esophagus
8	Vertebral ganglion	D	Intercostal artery
11	Vagus nerve	E	Aorta
12	Recurrent laryngeal nerve	G'	Left subclavian artery
14'	Dorsal caudal cervicothoracic cardiac nerve	K	Vertebral artery
14''	Ventral caudal cervicothoracic cardiac nerve	R'	Right auricle
16	Vertebral nerve	S'	Left auricle
18	Cranial vertebral cardiac nerve	T	Right ventricle
18'	Medial caudal vertebral cardiac nerve	U	Left ventricle
18''	Lateral caudal vertebral cardiac nerve	X	Bronchus
21'	Caudal vagal cardiac nerve	Y	Pulmonary artery

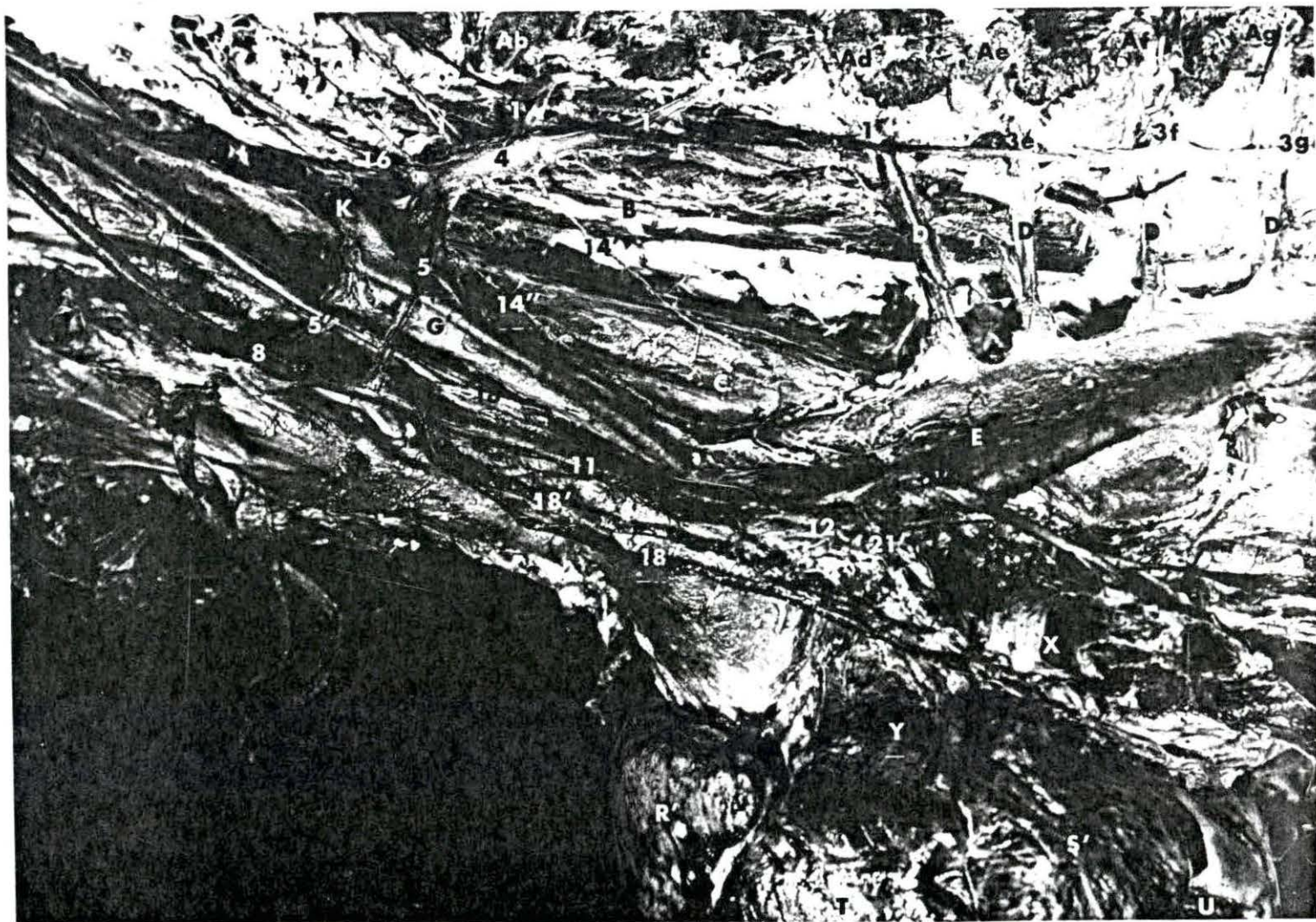

Figure 14. Canine: Lateral view of the cardiac nerves and related ganglia on the right side of the specimen.

- | | | | |
|-----|--|----|-----------------------------|
| 1 | Ramus communicans | Aa | First rib |
| 3d | Fourth thoracic ganglion | Ab | Second rib |
| 3e | Fifth thoracic ganglion | Ac | Third rib |
| 4 | Cervicothoracic ganglion | Ad | Fourth rib |
| 5 | Ansa subclavia (caudal limb) | B | Longus colli muscle |
| 5' | Ansa subclavia (cranial limb) | G" | Right subclavian artery |
| 8 | Vertebral ganglion | K | Vertebral artery |
| 11 | Vagus nerve | N" | Right common carotid artery |
| 12 | Recurrent laryngeal nerve | O | Right vena azygos |
| 13 | Thoracic cardiac nerve | P | Cranial vena cava |
| 14" | Ventral caudal cervicothoracic cardiac nerve | Q | Caudal vena cava |
| 16 | Vertebral nerve | R | Right atrium |
| 18' | Caudal vertebral cardiac nerve | R' | Right auricle |
| 21' | Caudal vagal cardiac nerve | T | Right ventricle |
| 24a | Eighth cervical spinal nerve | U | Left ventricle |
| 24b | Seventh cervical spinal nerve | W | Trachea |
| 25a | First thoracic spinal nerve | X | Bronchus |
| 26 | Vascular nerves | Y' | Pulmonary vein |

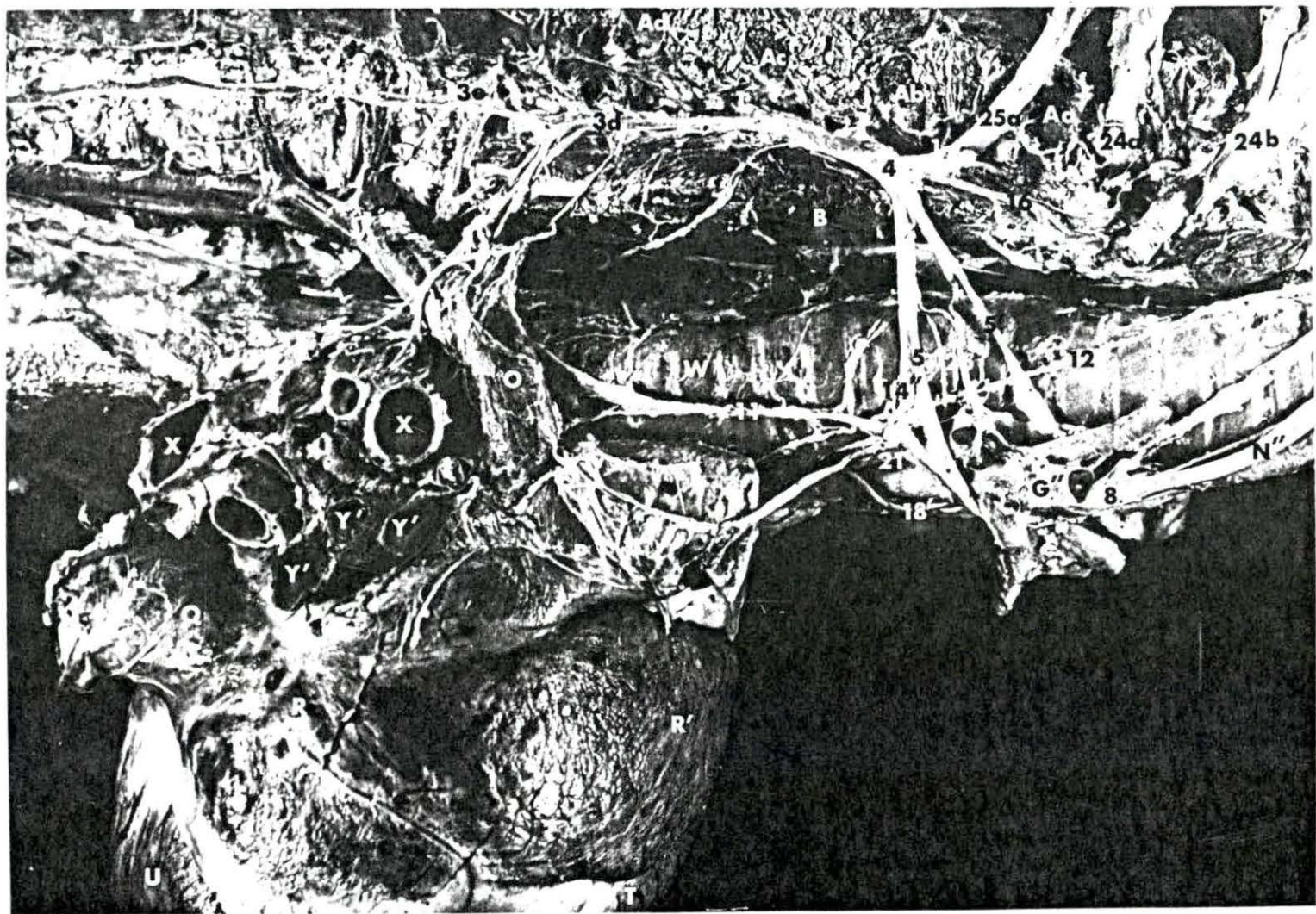


Figure 15. Equine: Left lateral illustration of the cardiac nerves and related ganglia

1	Ramus communicans	Af	Sixth rib
2	Sympathetic trunk	Ag	Seventh rib
3c	Third thoracic ganglion	Ah	Eighth rib
3d	Fourth thoracic ganglion	Aj	Ninth rib
3e	Fifth thoracic ganglion	B	Longus colli muscle
3f	Sixth thoracic ganglion	C	Esophagus
3g	Seventh thoracic ganglion	D	Intercostal artery
3h	Eighth thoracic ganglion	D'	Intercostal vein
3j	Ninth thoracic ganglion	E	Aorta
4	Cervicothoracic ganglion	G'	Left subclavian artery
5	Ansa subclavia (caudal limb)	H	Costocervical artery
5'	Ansa subclavia (cranial limb)	I	Transverse colli artery (dorsal artery)
8	Vertebral ganglion	J	Supreme intercostal artery (subcostal artery)
11	Vagus nerve	K	Vertebral artery
12'	Left recurrent laryngeal nerve	L	Deep cervical artery
13	Thoracic cardiac nerve	M'	Costocervico-vertebral vein
14'	Dorsal caudal cervicothoracic cardiac nerve	N'	Left common carotid artery
14''	Ventral caudal cervicothoracic cardiac nerve	P	Cranial vena cava
16	Vertebral nerve	R'	Right auricle
18'	Caudal vertebral cardiac nerve	S'	Left auricle
20	Cranial cervical cardiac nerve	T	Right ventricle
21	Cranial vagal cardiac nerve	U	Left ventricle
21'	Caudal vagal cardiac nerve	W	Trachea
24a	Eighth cervical spinal nerve	X	Bronchus
25a	First thoracic spinal nerve	Y	Pulmonary artery
25b	Second thoracic spinal nerve	Z	Lung
26	Vascular nerve	AA	Ligamentum arteriosum
Aa	First rib	BB'	Descending branch of left coronary artery
Ab	Second rib	BB''	Circumflex branch of left coronary artery
Ac	Third rib	CC	Great cardiac vein
Ad	Fourth rib		
Ae	Fifth rib		

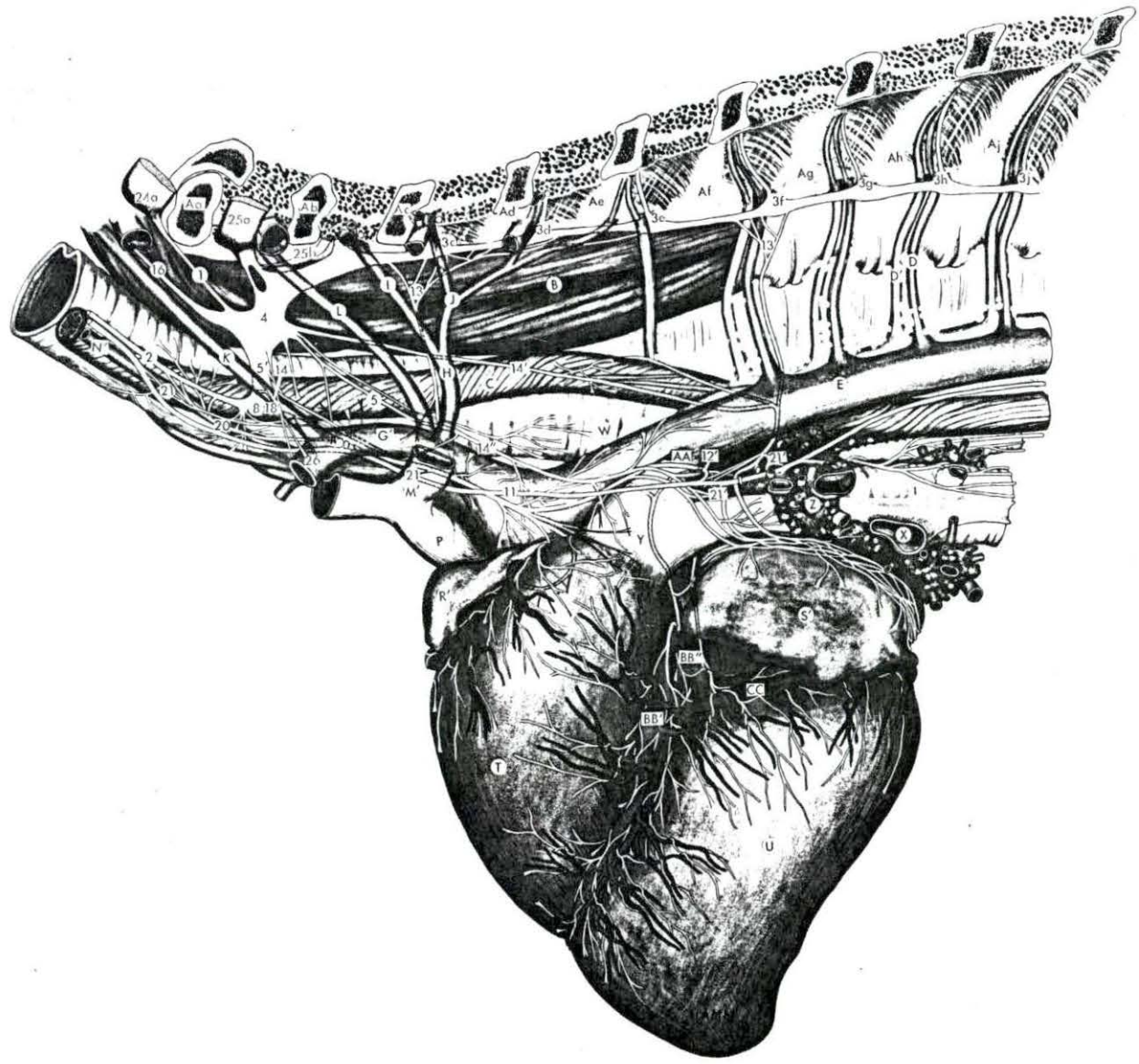


Figure 16. Equine: Right lateral illustration of the cardiac nerves and related ganglia.

1	Ramus communicans	Ad	Fourth rib
2	Sympathetic trunk	Ae	Fifth rib
3c	Third thoracic ganglion	Af	Sixth rib
3d	Fourth thoracic ganglion	Ag	Seventh rib
3e	Fifth thoracic ganglion	Ah	Eighth rib
3f	Sixth thoracic ganglion	Aj	Ninth rib
3g	Seventh thoracic ganglion	B	Longus colli muscle
3h	Eighth thoracic ganglion	C	Esophagus
4	Cervicothoracic ganglion	D	Intercostal artery
5	Ansa subclavia (caudal limb)	D'	Intercostal vein
5'	Ansa subclavia (cranial limb)	G''	Right subclavian artery
8	Vertebral ganglion	H'	Costocervical vein
11	Vagus nerve	K	Vertebral artery
12	Right recurrent laryngeal nerve	K'	Vertebral vein
12'	Left recurrent laryngeal nerve	L'	Deep cervical vein
13	Thoracic cardiac nerve	O	Right vena azygos
14	Cranial cervicothoracic cardiac nerve	P	Cranial vena cava
14'	Dorsal cervicothoracic cardiac nerve	Q	Caudal vena cava
14''	Ventral cervicothoracic cardiac nerve	R	Right atrium
16	Vertebral nerve	R'	Right auricle
18'	Caudal vertebral cardiac nerve	S	Left atrium
20	Cranial cervical cardiac nerve	T	Right ventricle
21'	Caudal vagal cardiac nerve	U	Left ventricle
22	Recurrent cardiac nerve	W	Trachea
23	Sympathetic nerve to phrenic nerve	X	Bronchus
24a	Eighth cervical spinal nerve	Z	Lung
25a	First thoracic spinal nerve	BB	Right coronary artery
25b	Second thoracic spinal nerve	BB''	Circumflex branch of left coronary artery
Aa	First rib	CC	Great cardiac vein
Ab	Second rib	EE	Thoracic duct
Ac	Third rib	FF	Middle cardiac vein

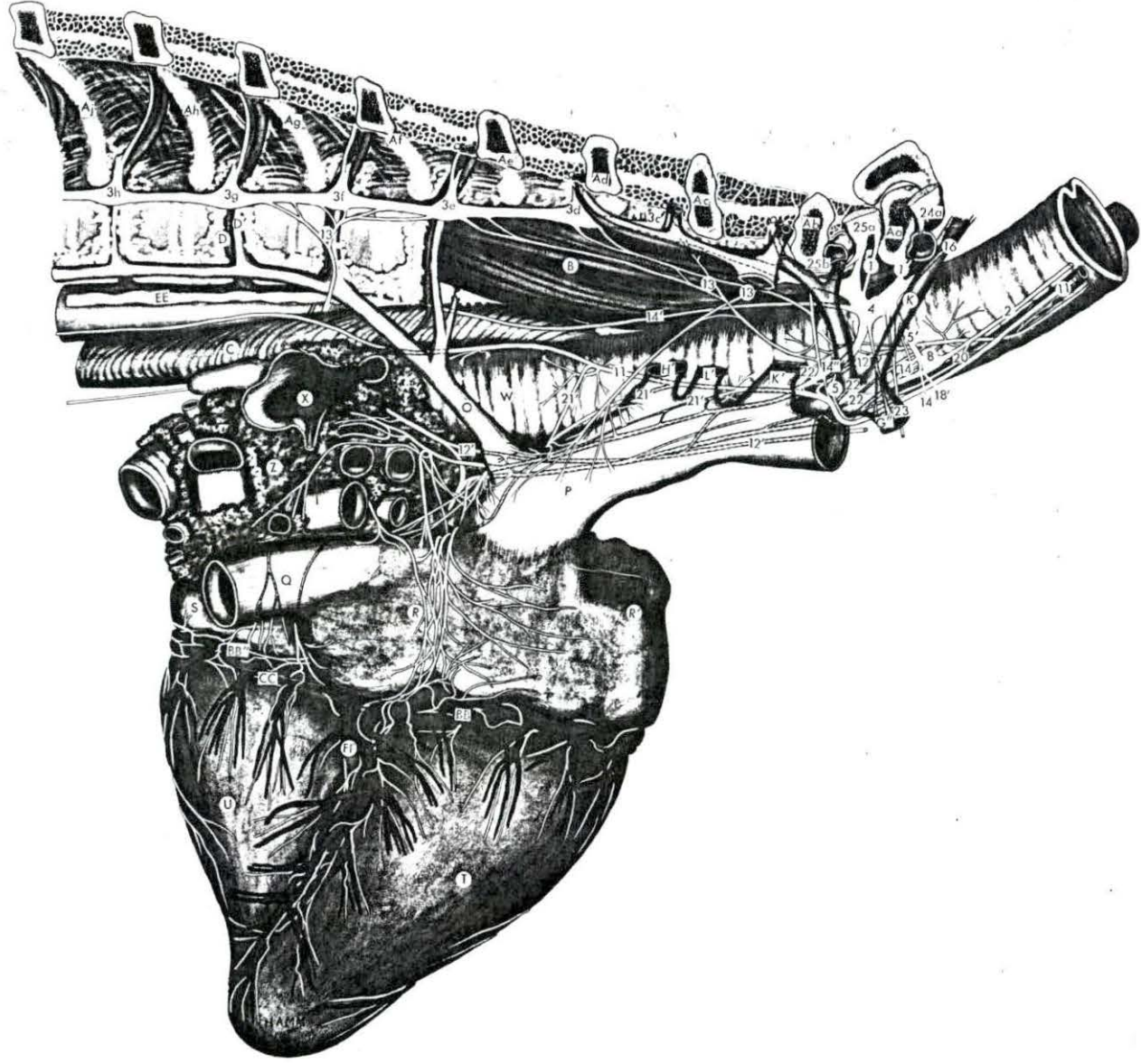


Figure 17. Bovine: Left lateral illustration of the cardiac nerves and related ganglia.

1	Ramus communicans	Ae	Fifth rib
2	Sympathetic trunk	Af	Sixth rib
3c	Third thoracic ganglion	Ag	Seventh rib
3d	Fourth thoracic ganglion	Ah	Eighth rib
3e	Fifth thoracic ganglion	Aj	Ninth rib
3f	Sixth thoracic ganglion	B	Longus colli muscle
3g	Seventh thoracic ganglion	C	Esophagus
3h	Eighth thoracic ganglion	D	Intercostal artery
3j	Ninth thoracic ganglion	D'	Intercostal vein
4	Cervicothoracic ganglion	F	Brachiocephalic artery
5	Ansa subclavia (caudal limb)	G'	Left subclavian artery
5'	Ansa subclavia (cranial limb)	H	Costocervical artery
6	Cardiac ganglion of the left intervascular triangle	I	Transverse colli artery
8	Vertebral ganglion	K	Vertebral artery
11	Vagus nerve	L	Deep cervical artery
12'	Left recurrent laryngeal nerve	M	Costocervico-vertebral artery
13	Thoracic cardiac nerve	M'	Costocervico-vertebral vein
14'	Dorsal caudal cervicothoracic cardiac nerve	N'	Left common carotid artery
14''	Ventral caudal cervicothoracic cardiac nerve	N''	Right common carotid artery
16	Vertebral nerve	O'	Left vena azygos (Hemiazygos vein)
21	Cranial vagal cardiac nerve	P	Cranial vena cava
21'	Caudal vagal cardiac nerve	R'	Right auricle
22	Recurrent cardiac nerve	S'	Left auricle
24a	Eighth cervical spinal nerve	T	Right ventricle
25a	First thoracic spinal nerve	U	Left ventricle
25b	Second thoracic spinal nerve	W	Trachea
26	Vascular nerves	X	Bronchus
Ab	Second rib	Y	Pulmonary artery
Ac	Third rib	Z	Lung
- Ad	Fourth rib	AA	Ligamentum arteriosum
		BB	Right coronary artery
		BB'	Descending branch of left coronary artery
		CC	Great cardiac vein
		EE	Thoracic duct

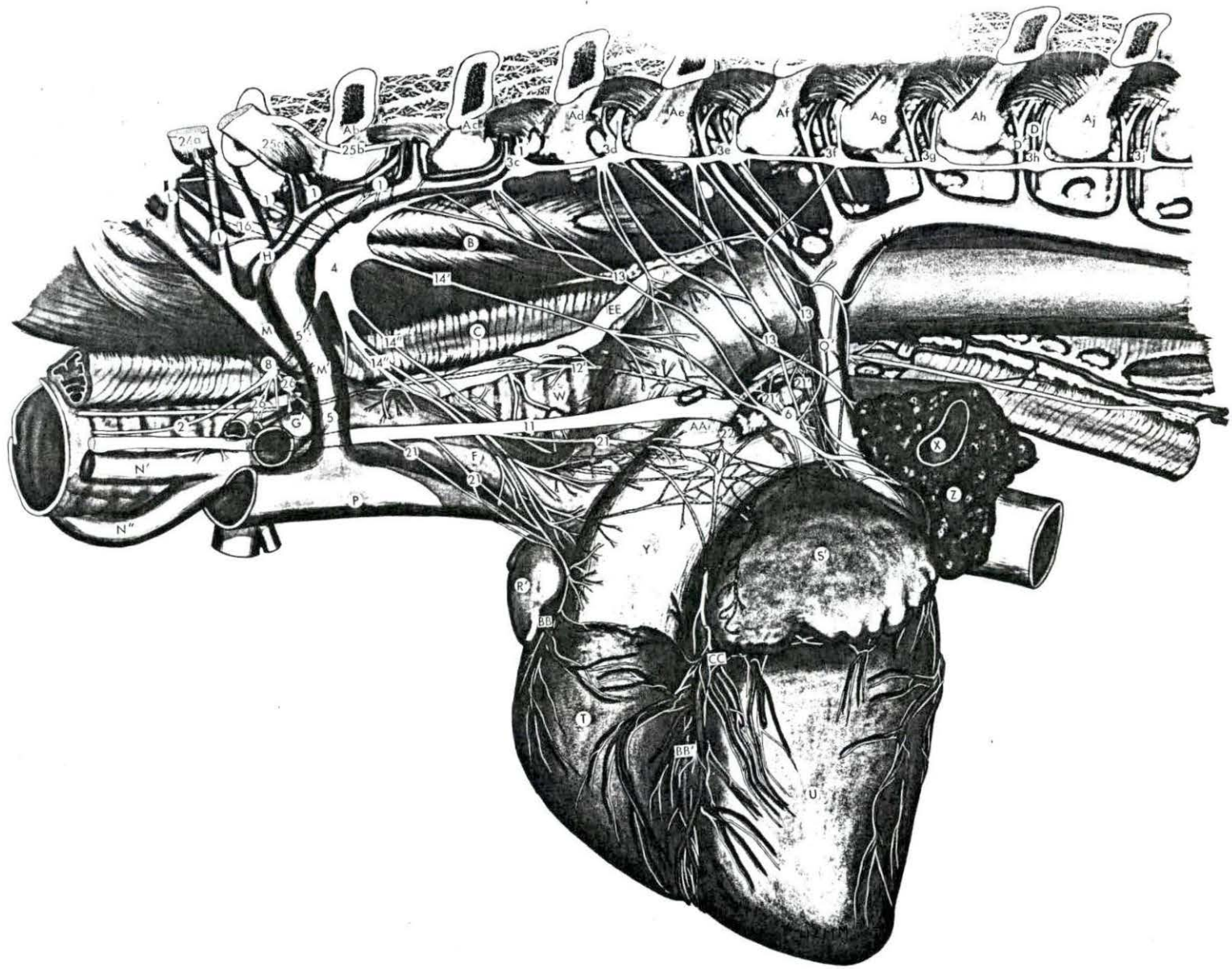


Figure 18. Bovine: Right lateral illustration of the cardiac nerves and related ganglia.

1	Ramus communicans	Ag	Seventh rib
2	Sympathetic trunk	Ah	Eighth rib
3c	First thoracic ganglion	Aj	Ninth rib
3d	Second thoracic ganglion	B	Longus colli muscle
3e	Third thoracic ganglion	C	Esophagus
3f	Fourth thoracic ganglion	D	Intercostal artery
3h	Sixth thoracic ganglion	D'	Intercostal artery
3j	Seventh thoracic ganglion	D''	Intercostal vein
4	Cervicothoracic ganglion	G''	Right subclavian artery
5	Ansa subclavia (caudal limb)	H	Costocervical artery
5'	Ansa subclavia (cranial limb)	K	Vertebral artery
8	Vertebral ganglion	L	Deep cervical artery
11	Vagus nerve	M	Costocervico-vertebral artery
12	Right recurrent laryngeal nerve	M'	Costocervico-vertebral vein
13	Thoracic cardiac nerve	N''	Right common carotid artery
14'	Dorsal caudal cervicothoracic cardiac nerve	O	Right vena azygos
14''	Ventral caudal cervicothoracic cardiac nerve	P	Cranial vena cava
16	Vertebral nerve	Q	Caudal vena cava
21'	Caudal vagal cardiac nerve	R	Right atrium
22	Recurrent cardiac nerve	R'	Right auricle
24a	Eighth cervical spinal nerve	T	Right ventricle
25a	First thoracic spinal nerve	U	Left ventricle
25b	Second thoracic spinal nerve	W	Trachea
26	Vascular nerves	X'	Apical bronchus
27	Accessory intraneural ganglion	X''	Primary bronchus
Aa	First rib	Z	Lung
Ab	Second rib	BB	Right coronary artery
Ac	Third rib	BB''	Circumflex branch of left coronary artery
Ad	Fourth rib	FF	Middle cardiac vein
Ae	Fifth rib		
Af	Sixth rib		

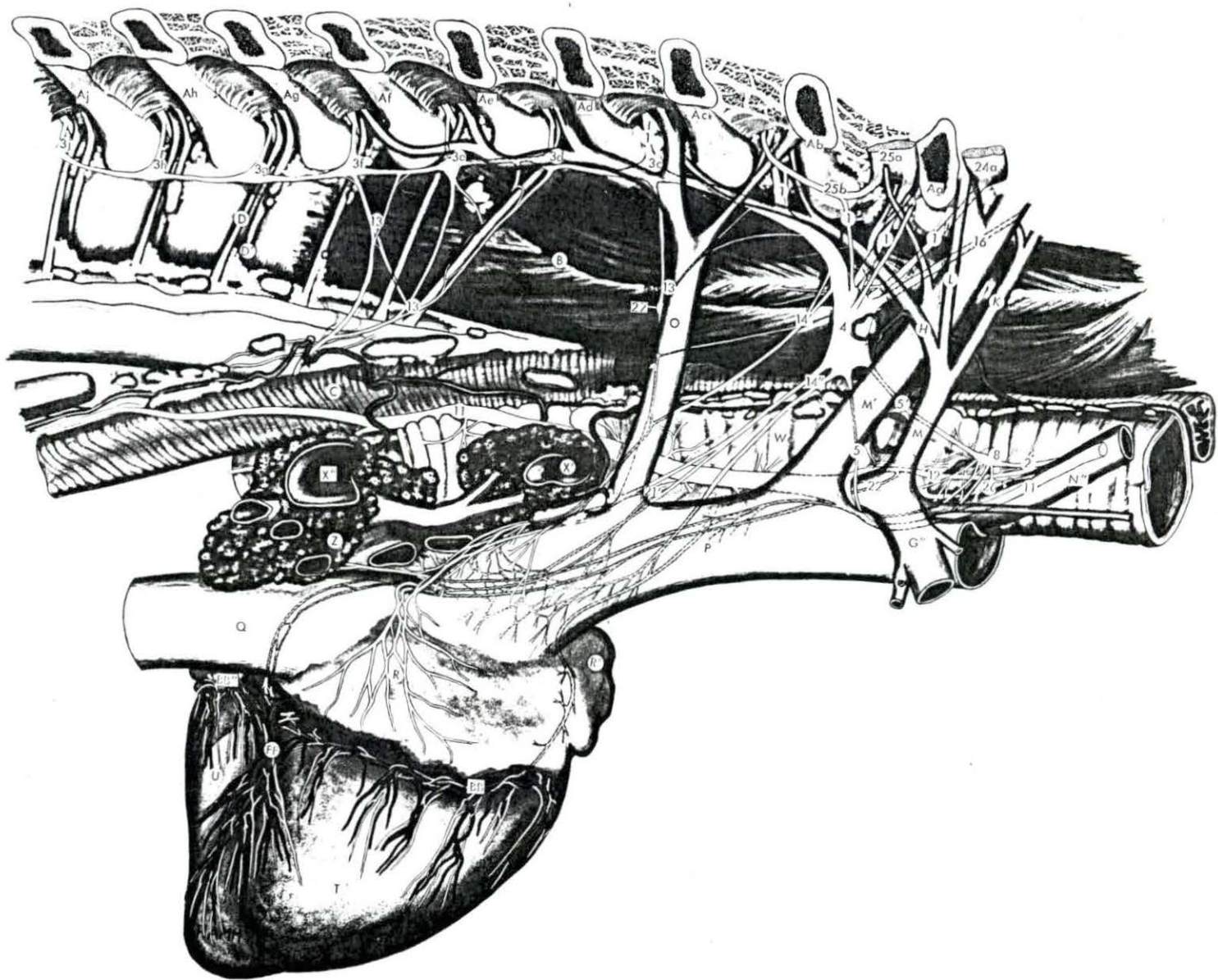


Figure 19. Ovine: Left lateral illustration of the cardiac nerves and related ganglia.

- | | | | |
|------|--|------|--|
| 1 | Ramus communicans | Ag | Seventh rib |
| 2 | Sympathetic trunk | Ah | Eighth rib |
| 3b | Second thoracic ganglion | Aj | Ninth rib |
| 3c | Third thoracic ganglion | B | Longus colli muscle |
| 3d | Fourth thoracic ganglion | C | Esophagus |
| 3e | Fifth thoracic ganglion | D | Intercostal artery |
| 3f | Sixth thoracic ganglion | D' | Intercostal vein |
| 3g | Seventh thoracic ganglion | E | Aorta |
| 3h | Eighth thoracic ganglion | F | Brachiocephalic artery |
| 4 | Cervicothoracic ganglion | G' | Subclavian artery |
| 5 | Ansa subclavia (caudal limb) | M | Costocervico-vertebral artery |
| 5' | Ansa subclavia (cranial limb) | M' | Costocervico-vertebral vein |
| 6 | Cardiac ganglion of the left
intervascular triangle | N' | Left common carotid artery |
| 8 | Vertebral ganglion | O' | Left vena azygos (hemiazygos vein) |
| 11 | Vagus nerve | R' | Right auricle |
| 12' | Left recurrent laryngeal nerve | S' | Left auricle |
| 13 | Thoracic cardiac nerve | T | Right ventricle |
| 14'' | Ventral caudal cervicothoracic
cardiac nerve | U | Left ventricle |
| 16 | Vertebral nerve | W | Trachea |
| 21 | Cranial vagal cardiac nerve | X | Bronchus |
| 21' | Caudal vagal cardiac nerve | Y | Pulmonary artery |
| 24a | Eighth cervical spinal nerve | Z | Lung |
| 24b | Seventh cervical spinal nerve | AA | Ligamentum arteriosum |
| 25a | First thoracic spinal nerve | BB' | Descending branch of left coronary
artery |
| 26 | Vascular nerve | BB'' | Circumflex branch of left coronary
artery |
| Aa | First rib | CC | Great cardiac vein |
| Ab | Second rib | | |
| Ac | Third rib | | |
| Ad | Fourth rib | | |
| Ae | Fifth rib | | |
| Af | Sixth rib | | |

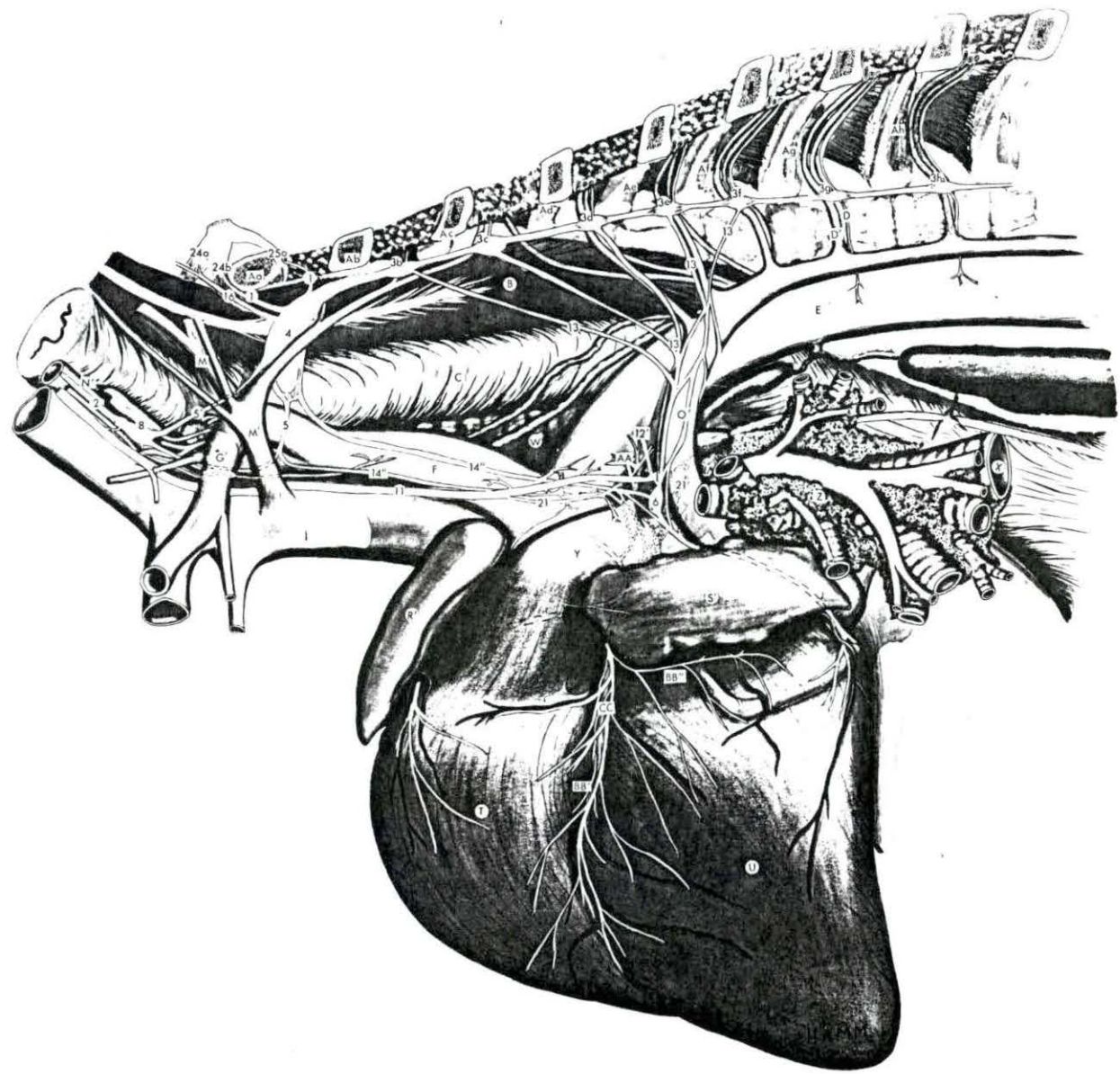


Figure 20. Ovine: Right lateral illustration of the cardiac nerves and related ganglia.

- | | | | |
|------|--|----|-------------------------------|
| 1 | Ramus communicans | Ae | Fifth rib |
| 2 | Sympathetic trunk | Af | Sixth rib |
| 3c | Third thoracic ganglion | Ag | Seventh rib |
| 3d | Fourth thoracic ganglion | Ah | Eighth rib |
| 3e | Fifth thoracic ganglion | Aj | Ninth rib |
| 3f | Sixth thoracic ganglion | B | Longus colli muscle |
| 3g | Seventh thoracic ganglion | C | Esophagus |
| 3h | Eighth thoracic ganglion | E | Aorta |
| 4 | Cervicothoracic ganglion | G" | Right subclavian artery |
| 5 | Ansa subclavia (caudal limb) | M | Costocervico-vertebral artery |
| 5' | Ansa subclavia (cranial limb) | M' | Costocervico-vertebral vein |
| 8 | Vertebral ganglion | N" | Right common carotid artery |
| 11 | Vagus nerve | P | Cranial vena cava |
| 12 | Right recurrent laryngeal nerve | Q | Caudal vena cava |
| 13 | Thoracic cardiac nerve | R | Right atrium |
| 14 | Cranial cervicothoracic cardiac nerve | R' | Right auricle |
| 14' | Dorsal caudal cervicothoracic cardiac nerve | T | Right ventricle |
| 14'' | Ventral caudal cervicothoracic cardiac nerve | U | Left ventricle |
| 16 | Vertebral nerve | W | Trachea |
| 21 | Cranial vagal cardiac nerve | X | Bronchus |
| 21' | Caudal vagal cardiac nerve | X' | Apical bronchus |
| 22 | Recurrent cardiac nerve | Z | Lung |
| 24a | Eighth cervical spinal nerve | BB | Right coronary artery |
| 24b | Seventh cervical spinal nerve | DD | Coronary sinus |
| 25a | First thoracic spinal nerve | EE | Thoracic duct |
| 26 | Vascular nerve | FF | Middle cardiac vein |
| Aa | First rib | | |
| Ab | Second rib | | |
| Ac | Third rib | | |
| Ad | Fourth rib | | |

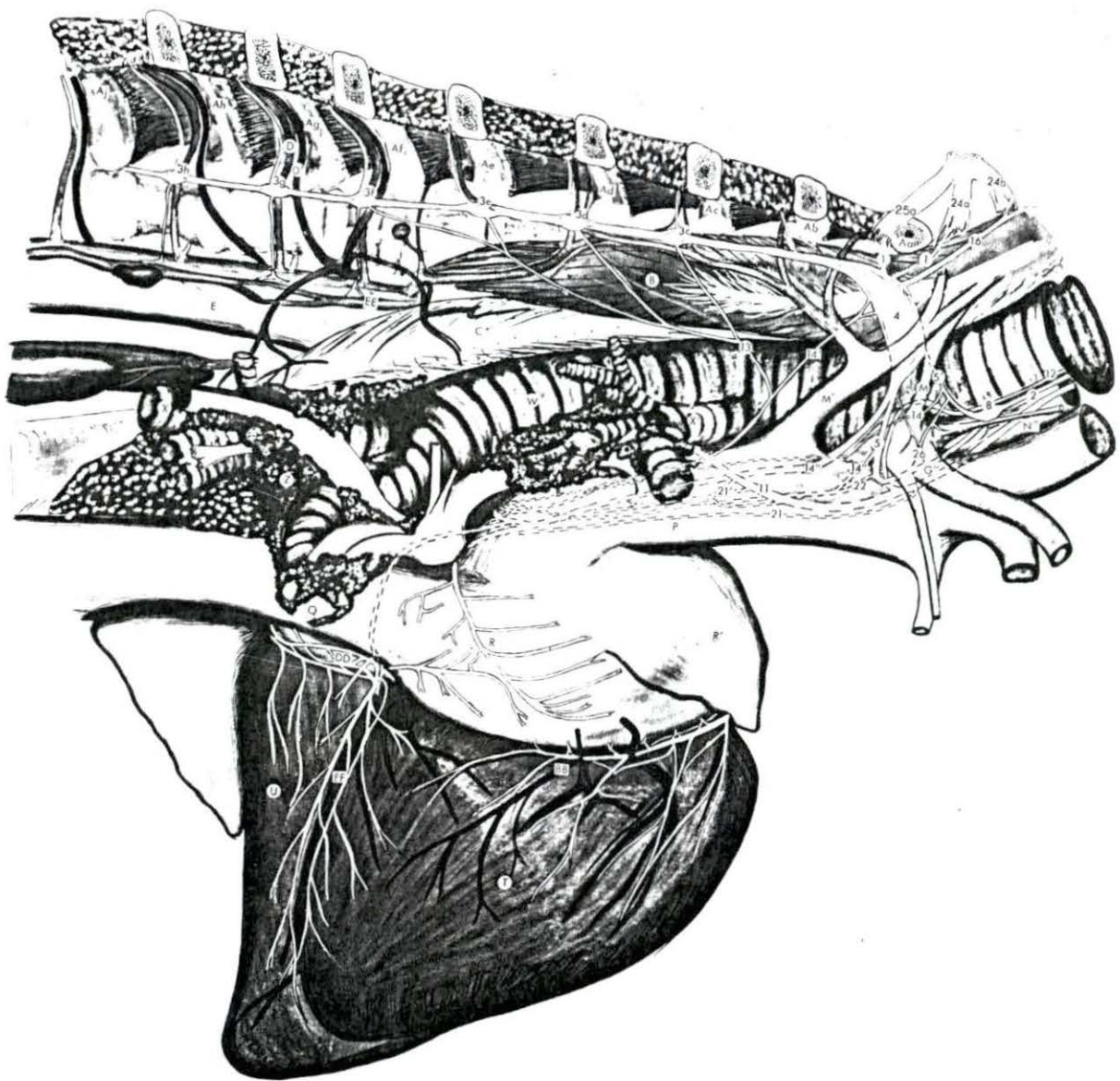


Figure 21. Caprine: Left lateral illustration of the cardiac nerves and related ganglia.

1	Ramus communicans	Af	Sixth rib
2	Sympathetic trunk	Ag	Seventh rib
3b	Second thoracic ganglion	Ah	Eighth rib
3c	Third thoracic ganglion	Aj	Ninth rib
3d	Fourth thoracic ganglion	B	Longus colli muscle
3e	Fifth thoracic ganglion	C	Esophagus
3f	Sixth thoracic ganglion	D	Intercostal artery
3g	Seventh thoracic ganglion	D'	Intercostal vein
3h	Eighth thoracic ganglion	E	Aorta
4	Cervicothoracic ganglion	F	Brachiocephalic artery
5	Ansa subclavia (caudal limb)	G'	Left subclavian artery
5'	Ansa subclavia (cranial limb)	M	Costocervico-vertebral artery
8	Vertebral ganglion	M'	Costocervico-vertebral vein
9	Middle cervical ganglion	N'	Left common carotid artery
11	Vagus nerve	O'	Left vena azygos (hemiazygos vein)
12'	Left recurrent laryngeal nerve	P	Cranial vena cava
13	Thoracic cardiac nerve	R'	Right auricle
14''	Ventral caudal cervicothoracic cardiac nerve	S'	Left auricle
16	Vertebral nerve	T	Right ventricle
18'	Caudal vertebral cardiac nerve	U	Left ventricle
19	Middle cervical cardiac nerve	W	Trachea
21	Cranial vagal cardiac nerve	X	Bronchus
21'	Caudal vagal cardiac nerve	Y	Pulmonary artery
24a	Eighth cervical spinal nerve	Z	Lung
24b	Seventh cervical spinal nerve	AA	Ligamentum arteriosum
25a	First thoracic spinal nerve	BB'	Descending branch of left coronary artery
26	Vascular nerve	BB''	Circumflex branch of left coronary artery
Aa	First rib	CC	Great cardiac vein
Ab	Second rib	EE	Thoracic duct
Ac	Third rib		
Ad	Fourth rib		
Ae	Fifth rib		

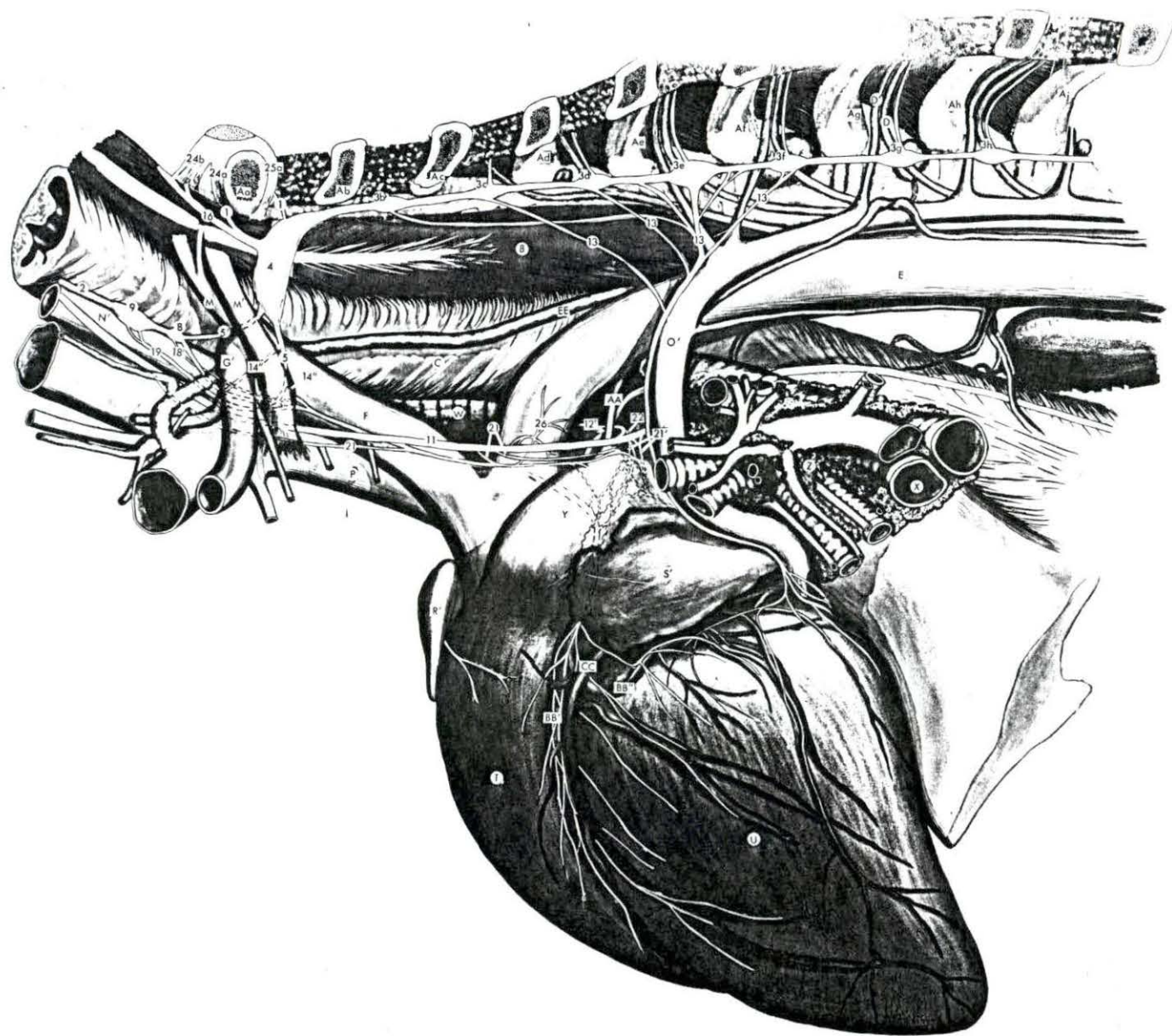


Figure 22. Caprine: Right lateral illustration of the cardiac nerves and related ganglia.

- | | | | |
|------|--|-----|-------------------------------|
| 1 | Ramus communicans | Af | Sixth rib |
| 2 | Sympathetic trunk | Ag | Seventh rib |
| 3b | Second thoracic ganglion | Ah | Eighth rib |
| 3c | Third thoracic ganglion | Aj | Ninth rib |
| 3d | Fourth thoracic ganglion | B | Longus colli muscle |
| 3e | Fifth thoracic ganglion | C | Esophagus |
| 3f | Sixth thoracic ganglion | E | Aorta |
| 3g | Seventh thoracic ganglion | G'' | Right subclavian artery |
| 3h | Eighth thoracic ganglion | M | Costocervico-vertebral artery |
| 4 | Cervicothoracic ganglion | M' | Costocervico-vertebral vein |
| 5 | Ansa subclavia (caudal limb) | N'' | Right common carotid artery |
| 5' | Ansa subclavia (cranial limb) | O | Right vena azygos |
| 8 | Vertebral ganglion | P | Cranial vena cava |
| 9 | Middle cervical ganglion | Q | Caudal vena cava |
| 11 | Vagus nerve | R | Right atrium |
| 12 | Right recurrent laryngeal nerve | R' | Right auricle |
| 14 | Cranial cervicothoracic cardiac nerve | T | Right ventricle |
| 14'' | Ventral caudal cervicothoracic cardiac nerve | U | Left ventricle |
| 16 | Vertebral nerve | W | Trachea |
| 19 | Middle cervical cardiac nerve | X | Bronchus |
| 21 | Cranial vagal cardiac nerve | X' | Apical bronchus |
| 21' | Caudal vagal cardiac nerve | Z | Lung |
| 22 | Recurrent cardiac nerve | BB | Right coronary artery |
| 24a | Eighth cervical spinal nerve | EE | Thoracic duct |
| 24b | Seventh cervical spinal nerve | FF | Middle cardiac vein |
| 25a | First thoracic spinal nerve | | |
| 26 | Vascular nerve | | |
| Aa | First rib | | |
| Ab | Second rib | | |
| Ac | Third rib | | |
| Ad | Fourth rib | | |
| Ae | Fifth rib | | |

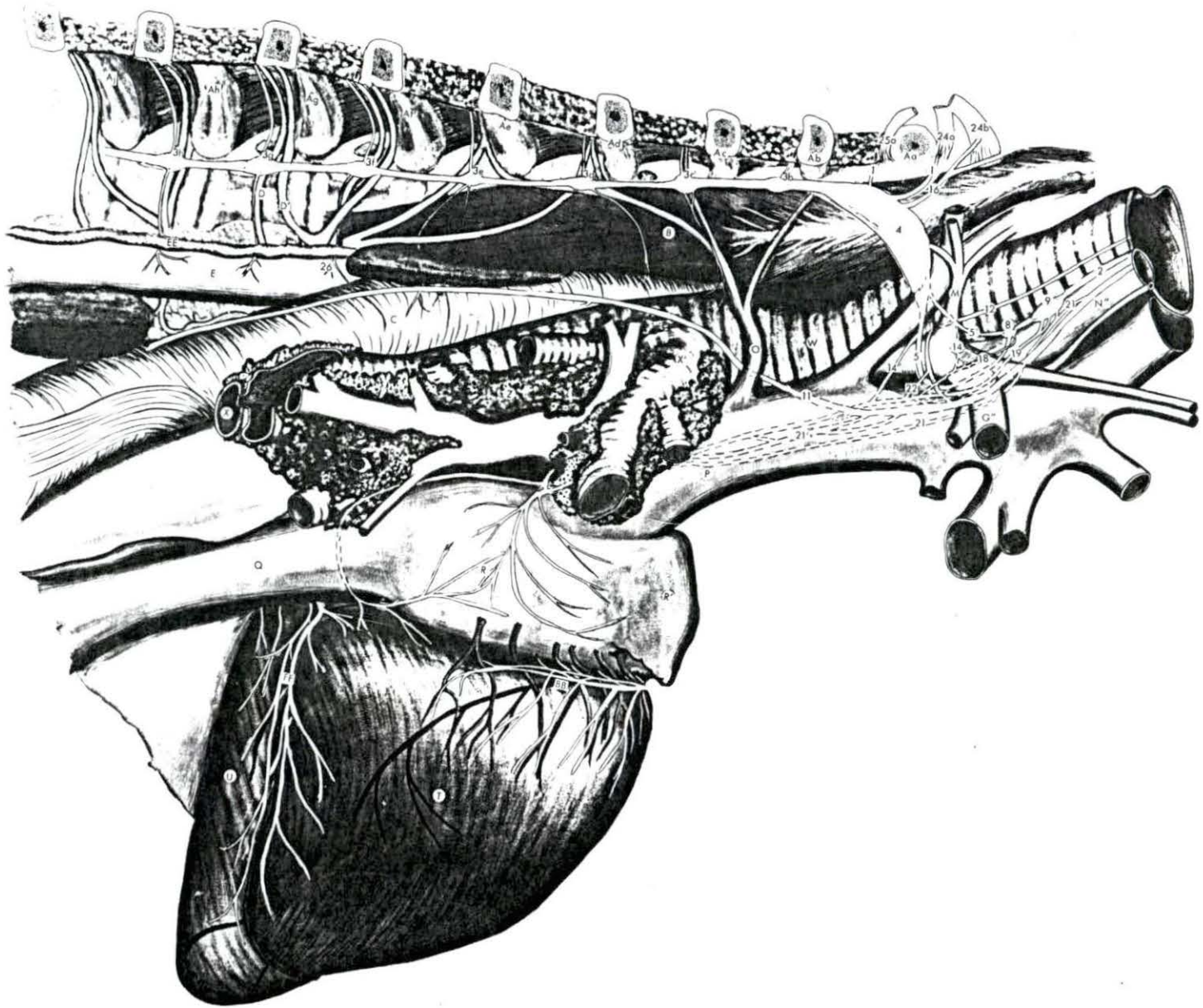


Figure 23. Porcine: Left lateral illustration of the cardiac nerves and related ganglia.

- | | | | |
|-----|--|-----|---|
| 1 | Ramus communicans | Ae | Fifth rib |
| 2 | Sympathetic trunk | Af | Sixth rib |
| 3b | Second thoracic ganglion | Ag | Seventh rib |
| 3c | Third thoracic ganglion | Ah | Eighth rib |
| 3d | Fourth thoracic ganglion | B | Longus colli muscle |
| 3e | Fifth thoracic ganglion | C | Esophagus |
| 3f | Sixth thoracic ganglion | D | Intercostal artery |
| 3g | Seventh thoracic ganglion | D' | Intercostal vein |
| 3h | Eighth thoracic ganglion | E | Aorta |
| 4 | Cervicothoracic ganglion | F | Brachiocephalic artery |
| 5 | Ansa subclavia (caudal limb) | G' | Left subclavian artery |
| 6 | Cardiac ganglion of the left inter-vascular triangle | H | Costocervical artery |
| 7 | Intermediate ganglion | K | Vertebral artery |
| 9 | Middle cervical ganglion | L | Deep cervical artery |
| 11 | Vagus nerve | M' | Costocervico-vertebral vein |
| 12' | Left recurrent laryngeal nerve | N' | Left common carotid artery |
| 13 | Thoracic cardiac nerve | O' | Left vena azygos (hemiazygos vein) |
| 14 | Cranial cervicothoracic cardiac nerve | P | Cranial vena cava |
| 16 | Vertebral nerve | R' | Right auricle |
| 17 | Intermediate cardiac nerve | S' | Left auricle |
| 19 | Middle cervical cardiac nerve | T | Right ventricle |
| 21 | Cranial vagal cardiac nerve | U | Left ventricle |
| 21' | Caudal vagal cardiac nerve | W | Trachea |
| 22 | Recurrent cardiac nerve | X | Bronchus |
| 24a | Eighth cervical spinal nerve | Y | Pulmonary artery |
| 25a | First thoracic spinal nerve | Z | Lung |
| 26 | Vascular nerve | BB' | Descending branch of left coronary artery |
| Aa | First rib | CC | Great cardiac vein |
| Ab | Second rib | | |
| Ac | Third rib | | |
| Ad | Fourth rib | | |

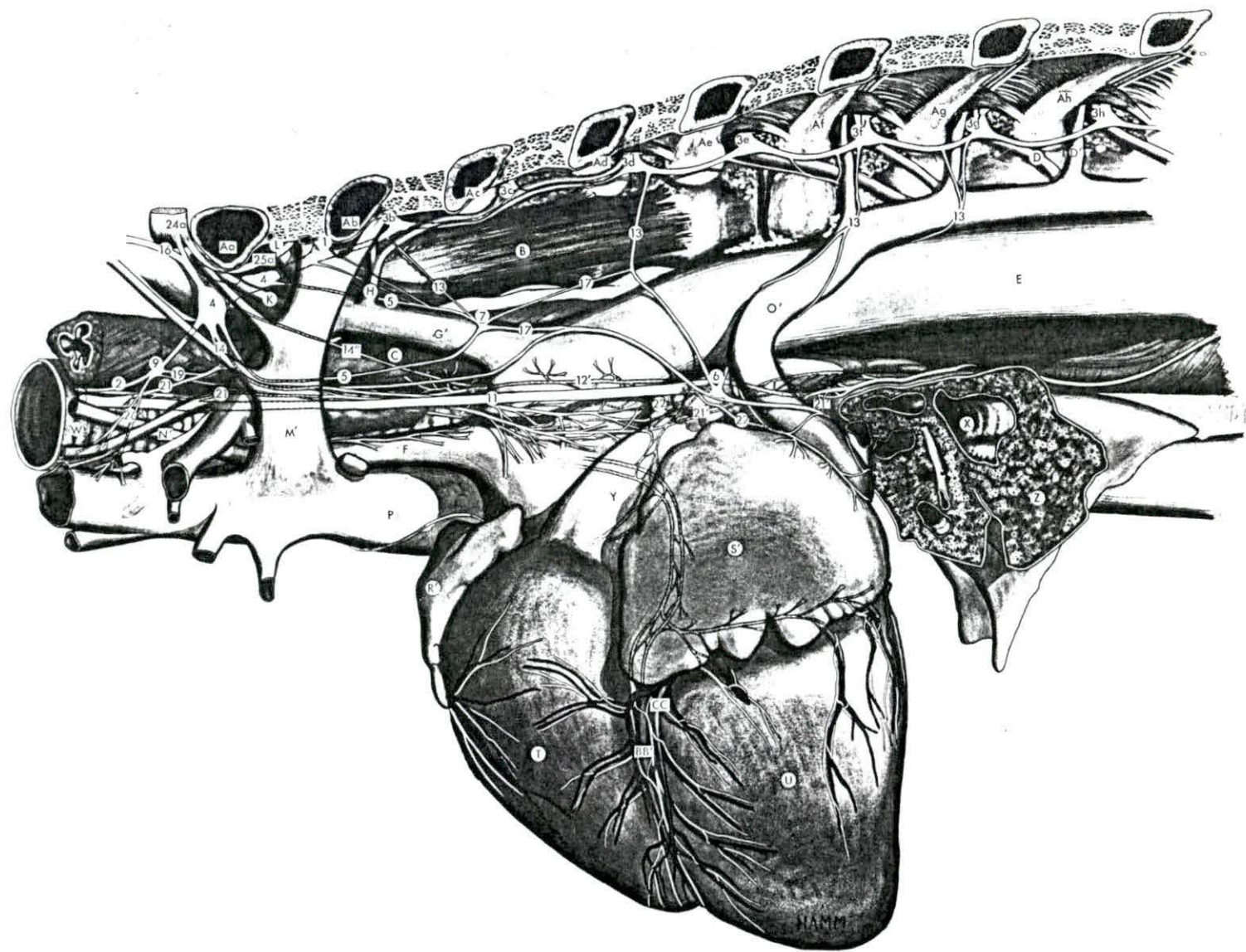


Figure 24. Porcine: Right lateral illustration of the cardiac nerves and related ganglia.

1	Ramus communicans	Ae	Fifth rib
2	Sympathetic trunk	Af	Sixth rib
3a	First thoracic ganglion	Ag	Seventh rib
3b	Second thoracic ganglion	Ah	Eighth rib
3c	Third thoracic ganglion	B	Longus colli muscle
3d	Fourth thoracic ganglion	C	Esophagus
3e	Fifth thoracic ganglion	E	Aorta
3f	Sixth thoracic ganglion	G"	Right subclavian artery
3g	Seventh thoracic ganglion	H	Costocervical artery
3h	Eighth thoracic ganglion	K	Vertebral artery
4	Cervicothoracic ganglion	N"	Right common carotid artery
5	Ansa subclavia (caudal limb)	P	Cranial vena cava
5'	Ansa subclavia (cranial limb)	Q	Caudal vena cava
7	Intermediate ganglion	R	Right atrium
8	Vertebral ganglion	R'	Right auricle
11	Vagus nerve	T	Right ventricle
12	Right recurrent laryngeal nerve	U	Left ventricle
13	Thoracic cardiac nerve	W	Trachea
14"	Ventral caudal cervicothoracic cardiac nerve	X	Bronchus
16	Vertebral nerve	Z	Lung
17	Intermediate cardiac nerve	BB	Right coronary artery
18'	Caudal vertebral cardiac nerve	DD	Coronary sinus
21'	Caudal vagal cardiac nerve	EE	Thoracic duct
22	Recurrent cardiac nerve	FF	Middle cardiac vein
24a	Eighth cervical spinal nerve		
25a	First thoracic spinal nerve		
Aa	First rib		
Ab	Second rib		
Ac	Third rib		
Ad	Fourth rib		

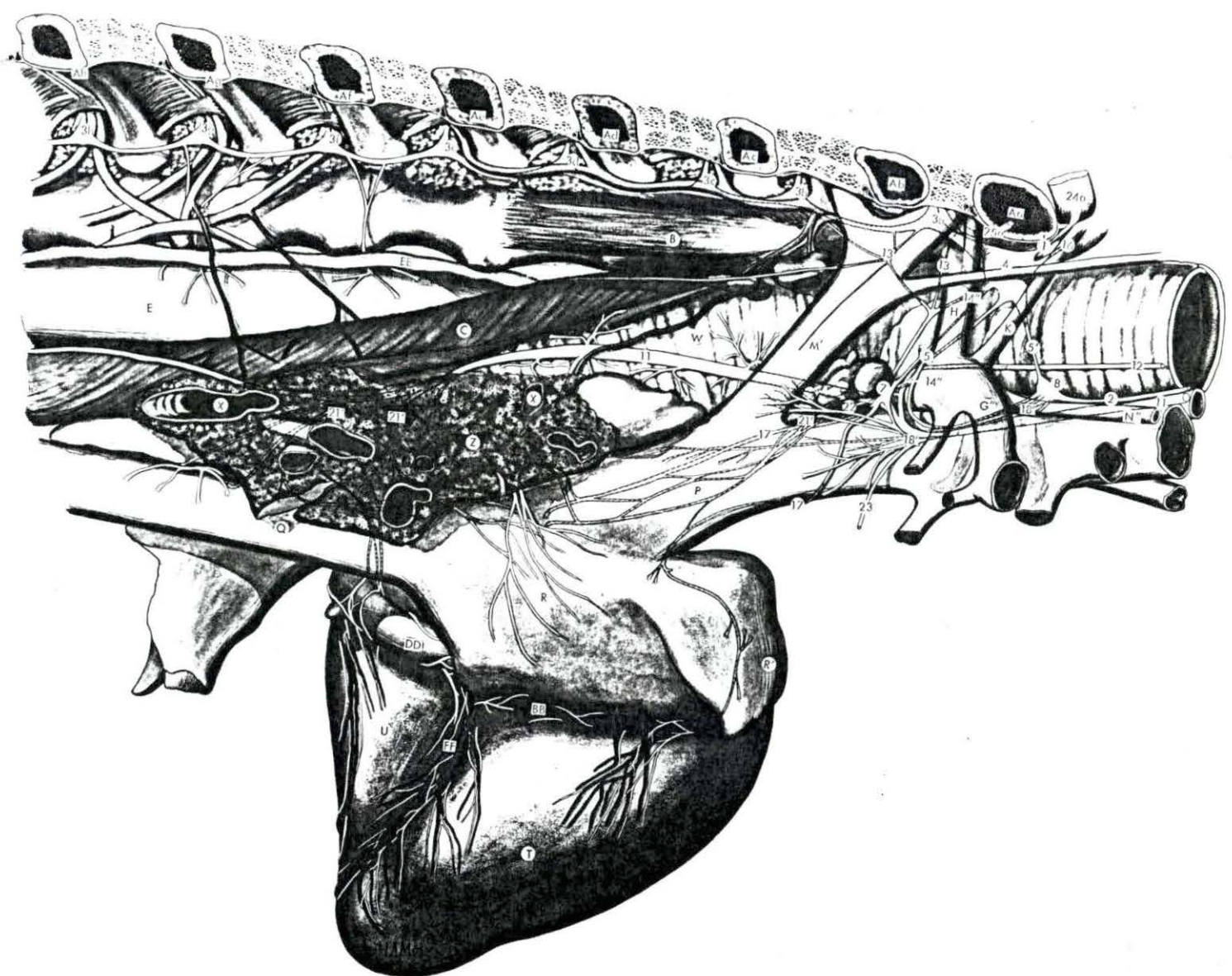


Figure 25. Feline: Left lateral illustration of the cardiac nerves and related ganglia.

- | | | | |
|------|--|------|--|
| 1 | Ramus communicans | Ad | Fourth rib |
| 2 | Sympathetic trunk | Ae | Fifth rib |
| 3c | Third thoracic ganglion | Af | Sixth rib |
| 3d | Fourth thoracic ganglion | Ag | Seventh rib |
| 3e | Fifth thoracic ganglion | Ah | Eighth rib |
| 3f | Sixth thoracic ganglion | B | Longus colli muscle |
| 3g | Seventh thoracic ganglion | C | Esophagus |
| 4 | Cervicothoracic ganglion | D | Intercostal artery |
| 5 | Ansa subclavia (caudal limb) | D' | Intercostal vein |
| 5' | Ansa subclavia (cranial limb) | F | Brachiocephalic artery |
| 7 | Intermediate ganglion | G' | Left subclavian artery |
| 8 | Vertebral ganglion | H | Costocervical artery |
| 11 | Vagus nerve | I | Transverse colli artery (dorsal artery) |
| 12' | Left recurrent laryngeal nerve | J | Supreme intercostal artery (sub-costal artery) |
| 13 | Thoracic cardiac nerve | K | Vertebral artery |
| 14' | Dorsal caudal cervicothoracic cardiac nerve | L | Deep cervical artery |
| 14'' | Ventral caudal cervicothoracic cardiac nerve | M' | Costocervico-vertebral vein |
| 16 | Vertebral nerve | N' | Left common carotid artery |
| 17 | Intermediate cardiac nerve | P | Cranial vena cava |
| 18' | Caudal vertebral cardiac nerve | R' | Right auricle |
| 20 | Cranial cervical cardiac nerve | S' | Left auricle |
| 21 | Cranial vagal cardiac nerve | T | Right ventricle |
| 21' | Caudal vagal cardiac nerve | U | Left ventricle |
| 24a | Eighth cervical spinal nerve | X | Bronchus |
| 24b | Seventh cervical spinal nerve | Y | Pulmonary artery |
| 24c | Sixth cervical spinal nerve | Z | Lung |
| 25a | First thoracic spinal nerve | AA | Ligamentum arteriosum |
| 26 | Vascular nerve | BB' | Descending branch of left coronary artery |
| Aa | First rib | BB'' | Circumflex branch of left coronary artery |
| Ab | Second rib | CC | Great cardiac vein |
| Ac | Third rib | | |

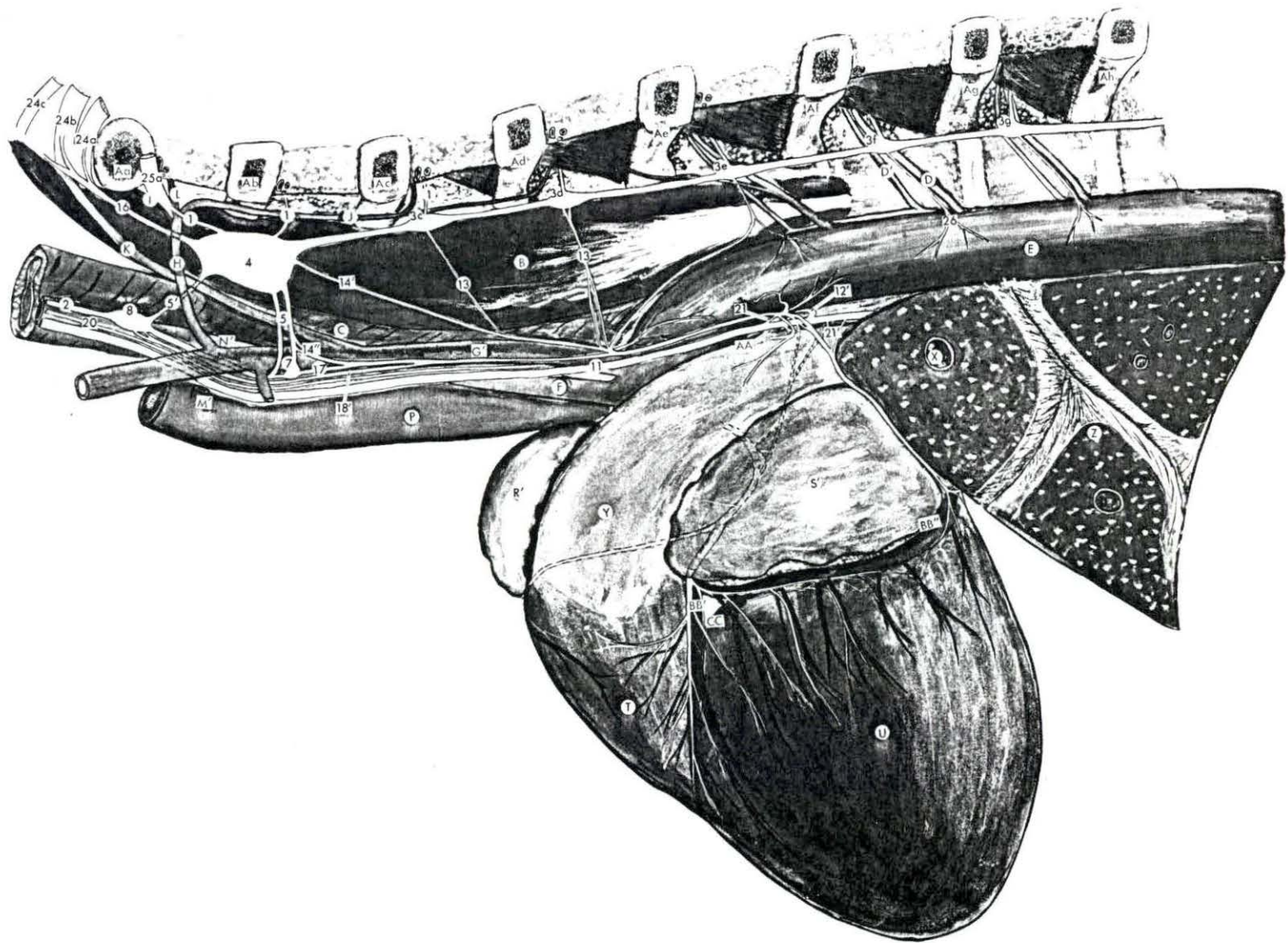


Figure 26. Feline: Right lateral illustration of the cardiac nerves and related ganglia.

1	Ramus communicans	Ah	Eighth rib
2	Sympathetic trunk	Aj	Ninth rib
3c	Third thoracic ganglion	B	Longus colli muscle
3d	Fourth thoracic ganglion	C	Esophagus
3e	Fifth thoracic ganglion	D	Intercostal artery
3f	Sixth thoracic ganglion	D'	Intercostal vein
3g	Seventh thoracic ganglion	E	Aorta
3h	Eighth thoracic ganglion	F	Brachiocephalic artery
4	Cervicothoracic ganglion	G''	Right subclavian artery
5	Ansa subclavia (caudal limb)	H	Costocervical artery
5'	Ansa subclavia (Cranial limb)	J	Supreme intercostal artery (sub-costal artery)
8	Vertebral ganglion	K	Vertebral artery
11	Vagus nerve	L	Deep cervical artery
12	Right recurrent laryngeal nerve	N''	Right common carotid artery
14''	Ventral caudal cervicothoracic cardiac nerve	O	Right vena azygos
16	Vertebral nerve	P	Cranial vena cava
18'	Caudal vertebral cardiac nerve	Q	Caudal vena cava
21	Cranial vagal cardiac nerve	R	Right atrium
21'	Caudal vagal cardiac nerve	R'	Right auricle
22	Recurrent cardiac nerve	T	Right ventricle
24a	Eighth cervical spinal nerve	U	Left ventricle
24b	Seventh cervical spinal nerve	W	Trachea
24c	Sixth cervical spinal nerve	X	Bronchus
25a	First thoracic spinal nerve	Z	Lung
26	Vascular nerve	BB	Right coronary artery
Aa	First rib	BB''	Circumflex branch of left coronary artery
Ab	Second rib	FF	Middle cardiac vein
Ac	Third rib		
Ad	Fourth rib		
Ae	Fifth rib		
Af	Sixth rib		
Ag	Seventh rib		

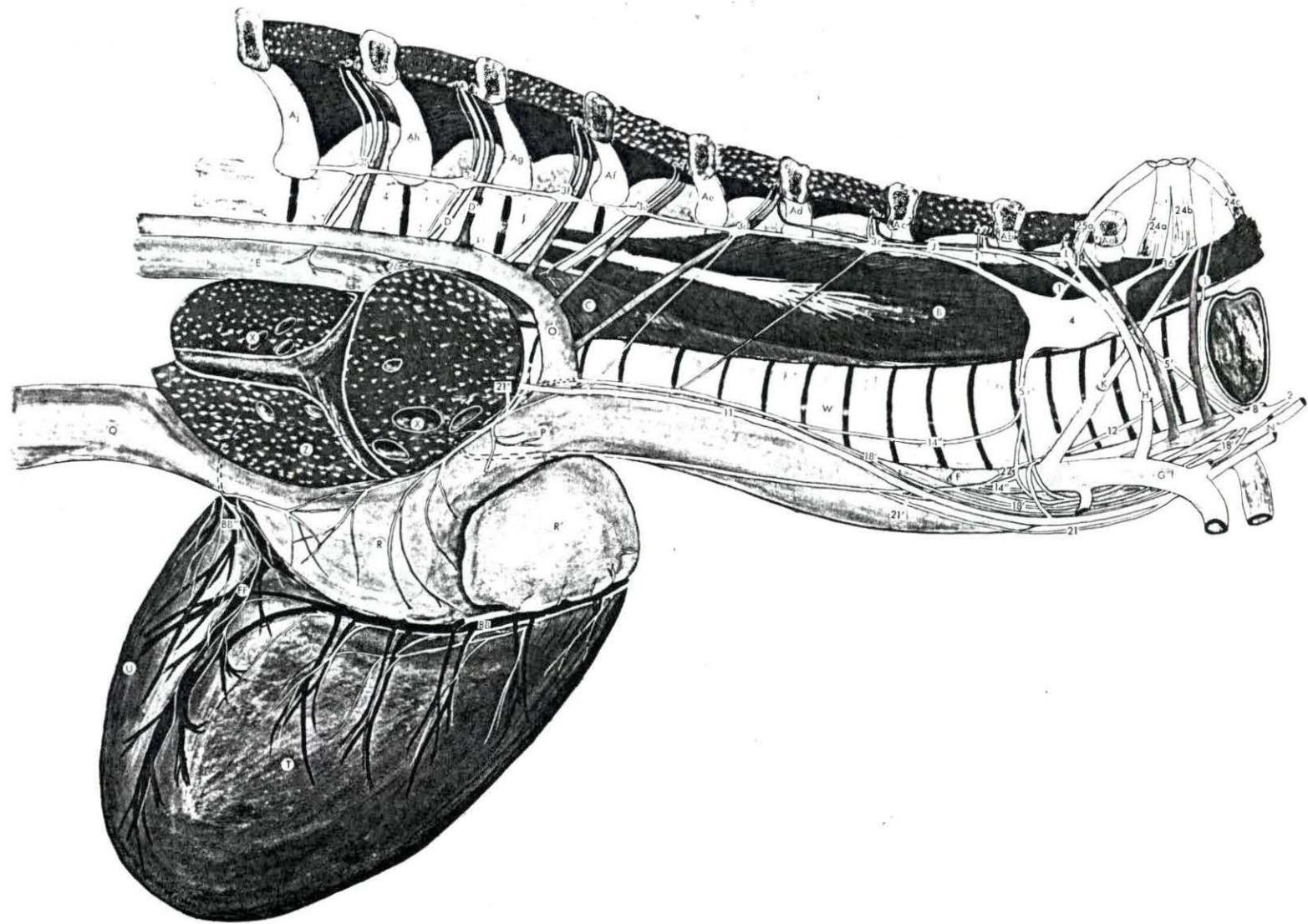


Figure 27. Canine: Left lateral illustration of the cardiac nerves and related ganglia.

1	Ramus communicans	Af	Sixth rib
2	Sympathetic trunk	Ag	Seventh rib
3d	Fourth thoracic ganglion	B	Longus colli muscle
3e	Fifth thoracic ganglion	C	Esophagus
3f	Sixth thoracic ganglion	D	Intercostal artery
3g	Seventh thoracic ganglion	D'	Intercostal vein
4	Cervicothoracic ganglion	E	Aorta
5	Ansa subclavia (caudal limb)	F	Brachiocephalic artery
5'	Ansa subclavia (cranial limb)	G'	Left subclavian artery
8	Vertebral ganglion	H	Costocervical artery
11	Vagus nerve	I	Transverse colli artery (dorsal artery)
13	Thoracic cardiac nerve	J	Supreme intercostal artery (sub-costal artery)
14	Cranial cervicothoracic cardiac nerve	K	Vertebral artery
14'	Dorsal caudal cervicothoracic cardiac nerve	L	Deep cervical artery
14''	Ventral caudal cervicothoracic cardiac nerve	M'	Costocervico-vertebral vein
16	Vertebral nerve	N'	Left common carotid artery
18	Cranial vertebral cardiac nerve	R'	Right auricle
18''	Medial caudal vertebral cardiac nerve	S'	Left auricle
18'''	Lateral caudal vertebral cardiac nerve	T	Right ventricle
18''''	Dorsal vertebral cardiac nerve	U	Left ventricle
21	Cranial vagal cardiac nerve	X	Bronchus
21'	Caudal vagal cardiac nerve	Y	Pulmonary artery
24a	Eighth cervical spinal nerve	Z	Lung
25a	First thoracic spinal nerve	AA	Ligamentum arteriosum
25b	Second thoracic spinal nerve	BB'	Descending branch of left coronary artery
Aa	First rib	CC	Great cardiac vein
Ab	Second rib		
Ac	Third rib		
Ad	Fourth rib		
Ae	Fifth rib		

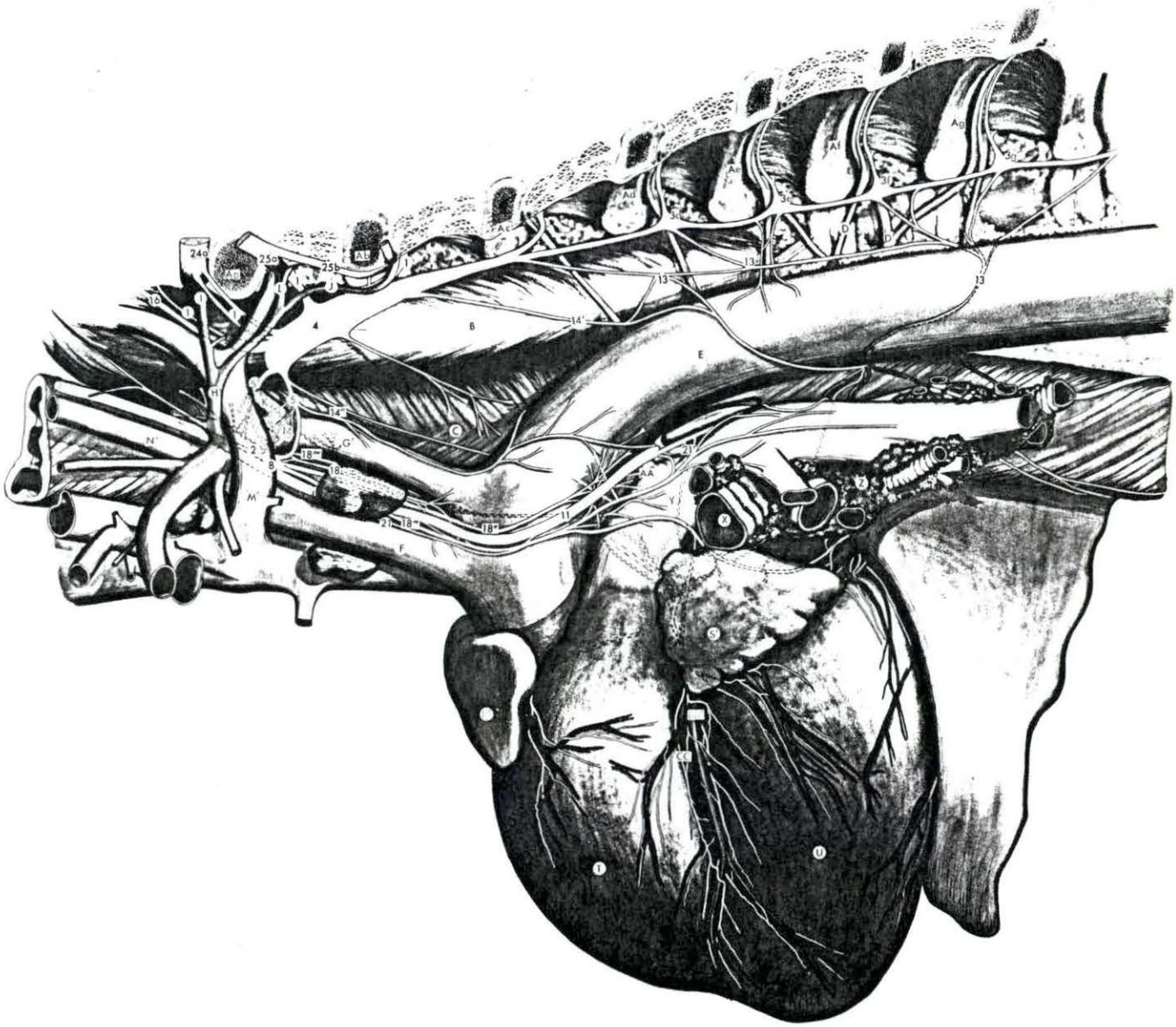


Figure 28. Canine: Right lateral illustration of the cardiac nerves and related ganglia.

- | | | | |
|------|--|-----|---|
| 1 | Ramus communicans | E | Aorta |
| 2 | Sympathetic trunk | G'' | Right subclavian artery |
| 3c | Third thoracic ganglion | H | Costocervical artery |
| 3d | Fourth thoracic ganglion | I | Transverse colli artery (dorsal artery) |
| 3e | Fifth thoracic ganglion | K | Vertebral artery |
| 3f | Sixth thoracic ganglion | M' | Costocervico-vertebral vein |
| 3g | Seventh thoracic ganglion | N'' | Right common carotid artery |
| 4 | Cervicothoracic ganglion | O | Right vena azygos |
| 5 | Ansa subclavia (caudal limb) | P | Cranial vena cava |
| 5' | Ansa subclavia (cranial limb) | Q | Caudal vena cava |
| 8 | Vertebral ganglion | R | Right atrium |
| 11 | Vagus nerve | R' | Right auricle |
| 12 | Right recurrent laryngeal nerve | T | Right ventricle |
| 13 | Thoracic cardiac nerve | U | Left ventricle |
| 14'' | Ventral caudal cervicothoracic cardiac nerve | W | Trachea |
| 16 | Vertebral nerve | X | Bronchus |
| 18' | Caudal vertebral cardiac nerve | Z | Lung |
| 21' | Caudal vagal cardiac nerve | BB | Right coronary artery |
| 22 | Recurrent cardiac nerve | | |
| 24a | Eighth cervical spinal nerve | | |
| 25a | First thoracic spinal nerve | | |
| 26 | Vascular nerve | | |
| Aa | First rib | | |
| Ab | Second rib | | |
| Ac | Third rib | | |
| Ad | Fourth rib | | |
| Ae | Fifth rib | | |
| Af | Sixth rib | | |
| Ag | Seventh rib | | |
| B | Longus colli muscle | | |
| D | Intercostal artery | | |
| D' | Intercostal vein | | |

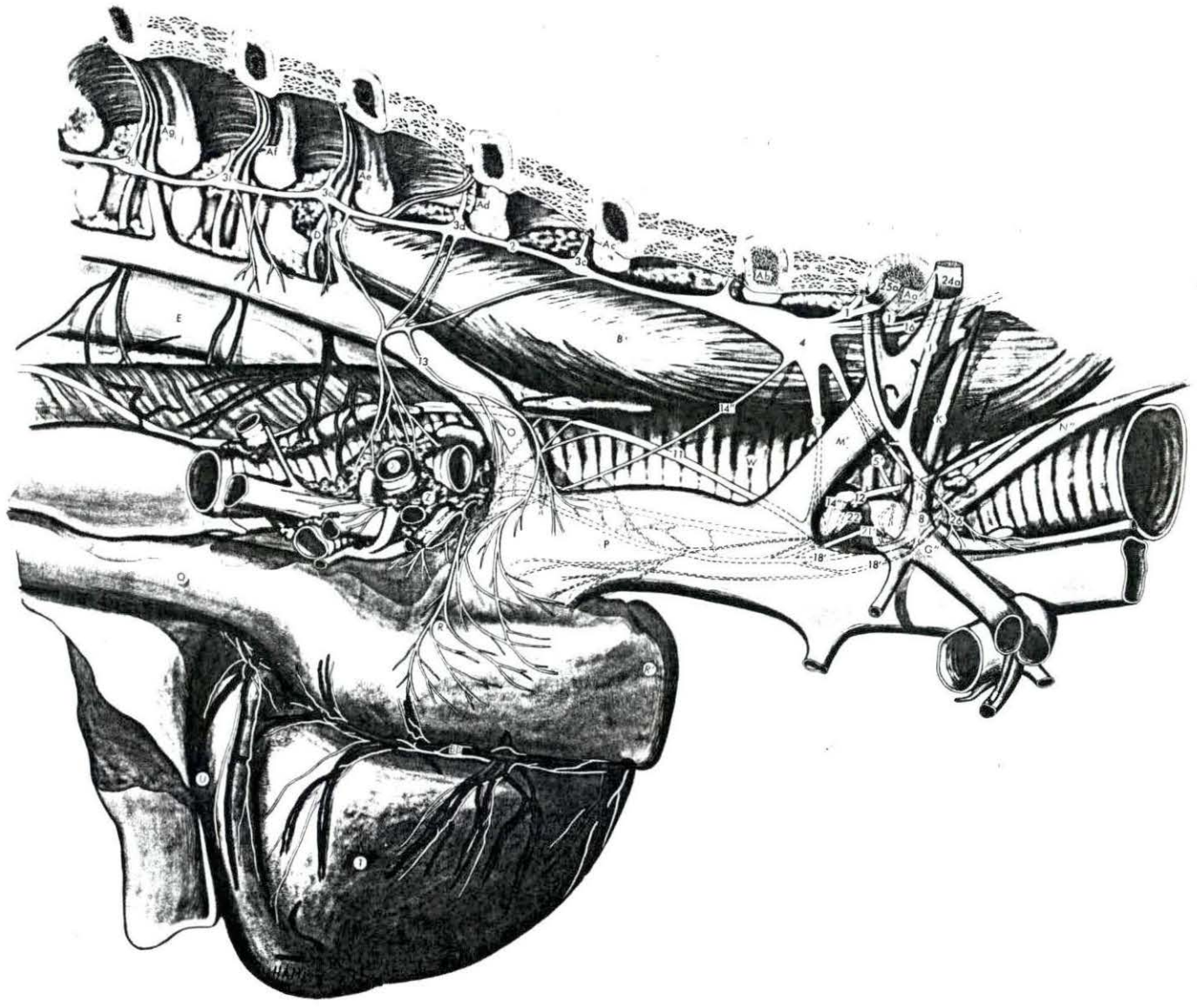


Figure 29. Equine: Dorsal view of the cardiac innervation. The sympathetic trunks and vagi are reflected laterally.

- | | | | |
|------|--|------|---|
| 1 | Ramus communicans | 24g | Second cervical spinal nerve |
| 2 | Sympathetic trunk | 25a | First thoracic spinal nerve |
| 3c | Third thoracic ganglion | 25b | Second thoracic spinal nerve |
| 3d | Fourth thoracic ganglion | 25c | Third thoracic spinal nerve |
| 3e | Fifth thoracic ganglion | 25d | Fourth thoracic spinal nerve |
| 3f | Sixth thoracic ganglion | 25e | Fifth thoracic spinal nerve |
| 3g | Seventh thoracic ganglion | 25f | Sixth thoracic spinal nerve |
| 3h | Eighth thoracic ganglion | 25g | Seventh thoracic spinal nerve |
| 4 | Cervicothoracic ganglion | 25h | Eighth thoracic spinal nerve |
| 5 | Ansa subclavia (caudal limb) | 28 | Cardiac plexus |
| 5' | Ansa subclavia (cranial limb) | 29 | Inferior ganglion of the vagus nerve |
| 8 | Vertebral ganglion | E | Aorta |
| 10 | Cranial cervical ganglion | F | Brachiocephalic artery |
| 11 | Vagus nerve | O | Right vena azygos |
| 12 | Right recurrent laryngeal nerve | P | Cranial vena cava |
| 12' | Left recurrent laryngeal nerve | Q | Caudal vena cava |
| 13 | Thoracic cardiac nerve | R' | Right auricle |
| 14 | Cranial cervicothoracic cardiac nerve | S' | Left auricle |
| 14' | Dorsal caudal cervicothoracic cardiac nerve | T | Right ventricle |
| 14'' | Ventral caudal cervicothoracic cardiac nerve | U | Left ventricle |
| 16 | Vertebral nerve | Y | Pulmonary artery |
| 18' | Caudal vertebral cardiac nerve | Y' | Pulmonary vein |
| 20 | Cranial cervical cardiac nerve | AA | Ligamentum arteriosum |
| 21 | Cranial vagal cardiac nerve | BB | Right coronary artery |
| 21' | Caudal vagal cardiac nerve | BB' | Descending branch of left coronary artery |
| 22 | Recurrent cardiac nerve | BB'' | Circumflex branch of left coronary artery |
| 24a | Eighth cervical spinal nerve | CC | Great cardiac vein |
| 24b | Seventh cervical spinal nerve | | |
| 24c | Sixth cervical spinal nerve | | |
| 24d | Fifth cervical spinal nerve | | |
| 24e | Fourth cervical spinal nerve | | |
| 24f | Third cervical spinal nerve | | |

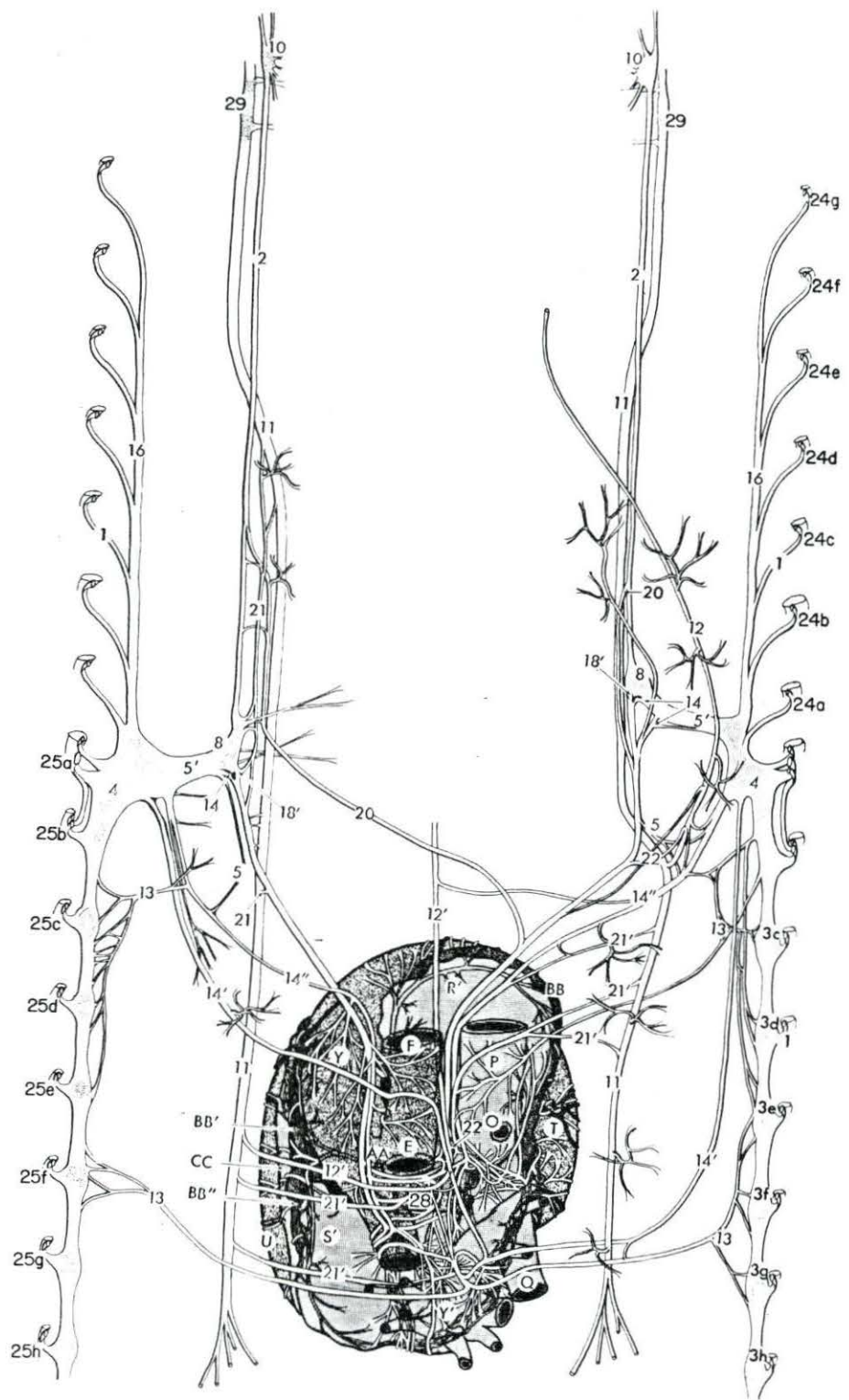


Figure 30. Bovine: Dorsal view of the cardiac innervation. The sympathetic trunks and vagi are reflected laterally.

- | | | | |
|------|---|-----|---|
| 1 | Ramus communicans | 25f | Sixth thoracic spinal nerve |
| 2 | Sympathetic trunk | 25g | Seventh thoracic spinal nerve |
| 3c | Third thoracic ganglion | 25h | Eighth thoracic spinal nerve |
| 3d | Fourth thoracic ganglion | 27 | Accessory intraneural ganglion |
| 3e | Fifth thoracic ganglion | 28 | Cardiac plexus |
| 3f | Sixth thoracic ganglion | 29 | Inferior ganglion or the vagus nerve |
| 3g | Seventh thoracic ganglion | E | Aorta |
| 3h | Eighth thoracic ganglion | F | Brachiocephalic artery |
| 4 | Cervicothoracic ganglion | O | Right vena azygos |
| 5 | Ansa subclavia (caudal limb) | O' | Left vena azygos (hemiazygos vein) |
| 5' | Ansa subclavia (cranial limb) | P | Cranial vena cava |
| 6 | Cardiac ganglion of the left intervascular triangle | Q | Caudal vena cava |
| 8 | Vertebral ganglion | R | Right atrium |
| 10 | Cranial cervical ganglion | R' | Right auricle |
| 11 | Vagus nerve | S' | Left auricle |
| 12 | Right recurrent laryngeal nerve | T | Right ventricle |
| 12' | Left recurrent laryngeal nerve | U | Left ventricle |
| 13 | Thoracic cardiac nerve | Y | Pulmonary artery |
| 14' | Dorsal caudal cervicothoracic cardiac nerve | BB' | Descending branch of left coronary artery |
| 14'' | Ventral caudal cervicothoracic cardiac nerve | | |
| 16 | Vertebral nerve | | |
| 21 | Cranial vagal cardiac nerve | | |
| 21' | Caudal vagal cardiac nerve | | |
| 22 | Recurrent cardiac nerve | | |
| 24a | Eighth cervical spinal nerve | | |
| 24b | Seventh cervical spinal nerve | | |
| 24c | Sixth cervical spinal nerve | | |
| 24d | Fifth cervical spinal nerve | | |
| 24e | Fourth cervical spinal nerve | | |
| 24f | Third cervical spinal nerve | | |
| 24g | Second cervical spinal nerve | | |
| 25a | First thoracic spinal nerve | | |
| 25b | Second thoracic spinal nerve | | |
| 25c | Third thoracic spinal nerve | | |
| 25d | Fourth thoracic spinal nerve | | |
| 25e | Fifth thoracic spinal nerve | | |

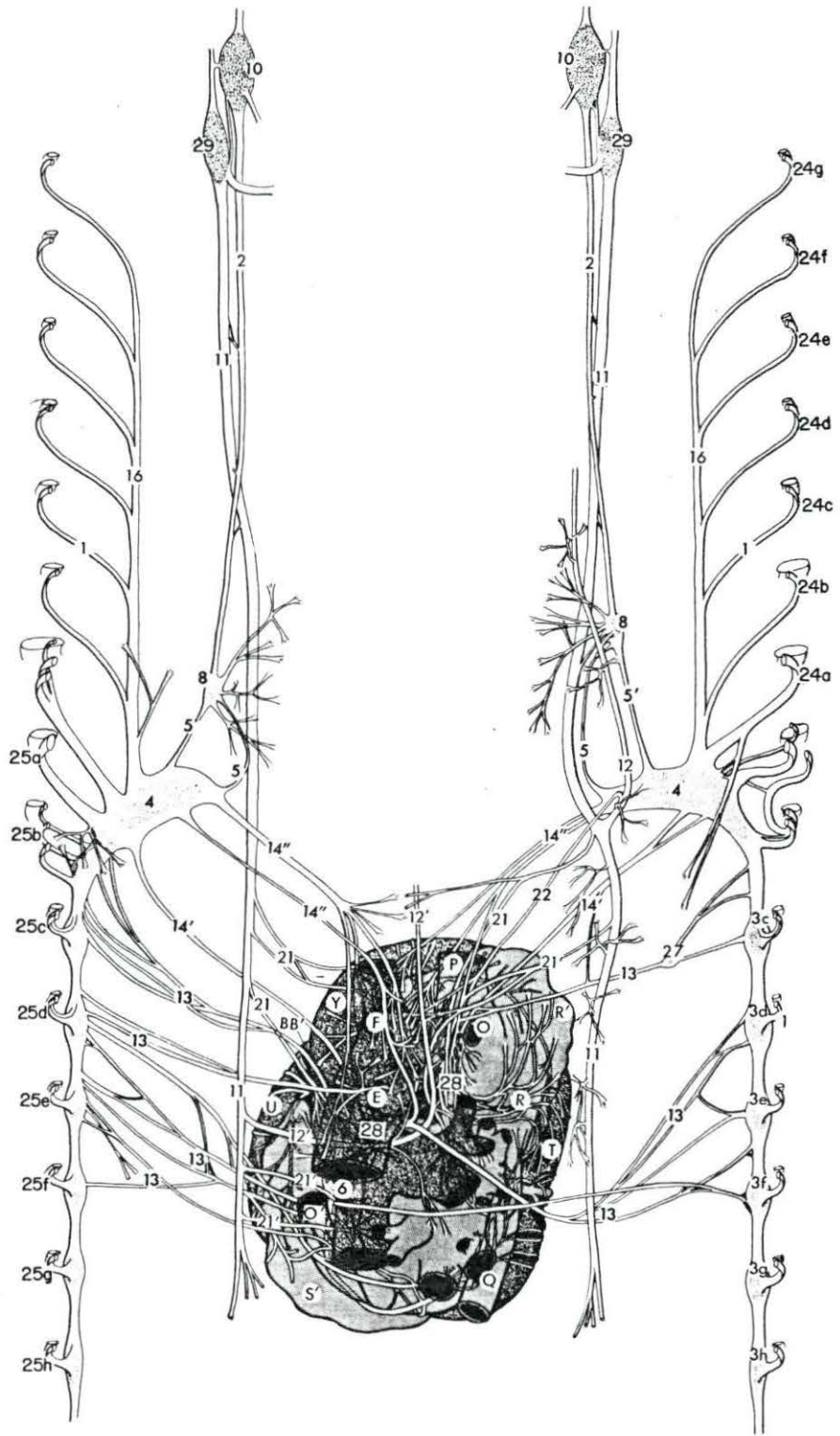


Figure 31. Ovine: Dorsal view of the cardiac innervation. The sympathetic trunks and vagi are reflected laterally.

- | | | | |
|------|---|------|---|
| 1 | Ramus communicans | 25a | First thoracic spinal nerve |
| 2 | Sympathetic trunk | 25b | Second thoracic spinal nerve |
| 3b | Second thoracic ganglion | 25c | Third thoracic spinal nerve |
| 3c | Third thoracic ganglion | 25d | Fourth thoracic spinal nerve |
| 3d | Fourth thoracic ganglion | 25e | Fifth thoracic spinal nerve |
| 3e | Fifth thoracic ganglion | 25f | Sixth thoracic spinal nerve |
| 3f | Sixth thoracic ganglion | 25g | Seventh thoracic spinal nerve |
| 3g | Seventh thoracic ganglion | 25h | Eighth thoracic spinal nerve |
| 3h | Eighth thoracic ganglion | 26 | Vascular nerve |
| 4 | Cervicothoracic ganglion | 28 | Cardiac plexes |
| 5 | Ansa subclavia (caudal limb) | 29 | Inferior ganglion of the vagus nerve |
| 5' | Ansa subclavia (cranial limb) | E | Aorta |
| 6 | Cardiac ganglion of the left intervascular triangle | F | Brachiocephalic artery |
| 8 | Vertebral ganglion | O | Right vena azygos |
| 10 | Cranial cervical ganglion | O' | Left vena azygos (hemiazygos vein) |
| 11 | Vagus nerve | P | Cranial vena cava |
| 12 | Right recurrent laryngeal nerve | Q | Caudal vena cava |
| 12' | Left recurrent laryngeal nerve | R | Right atrium |
| 13 | Thoracic cardiac nerve | R' | Right auricle |
| 14' | Dorsal caudal cervicothoracic cardiac nerve | S' | Left auricle |
| 14'' | Ventral caudal cervicothoracic cardiac nerve | T | Right ventricle |
| 16 | Vertebral nerve | U | Left ventricle |
| 21 | Cranial vagal cardiac nerve | Y | Pulmonary artery |
| 21' | Caudal vagal cardiac nerve | Y' | Pulmonary vein |
| 22 | Recurrent cardiac nerve | BB | Right coronary artery |
| 24a | Eighth cervical spinal nerve | BB' | Descending branch of left coronary artery |
| 24b | Seventh cervical spinal nerve | BB'' | Circumflex branch of left coronary artery |
| 24c | Sixth cervical spinal nerve | | |
| 24d | Fifth cervical spinal nerve | | |
| 24e | Fourth cervical spinal nerve | | |
| 24f | Third cervical spinal nerve | | |
| 24g | Second cervical spinal nerve | | |

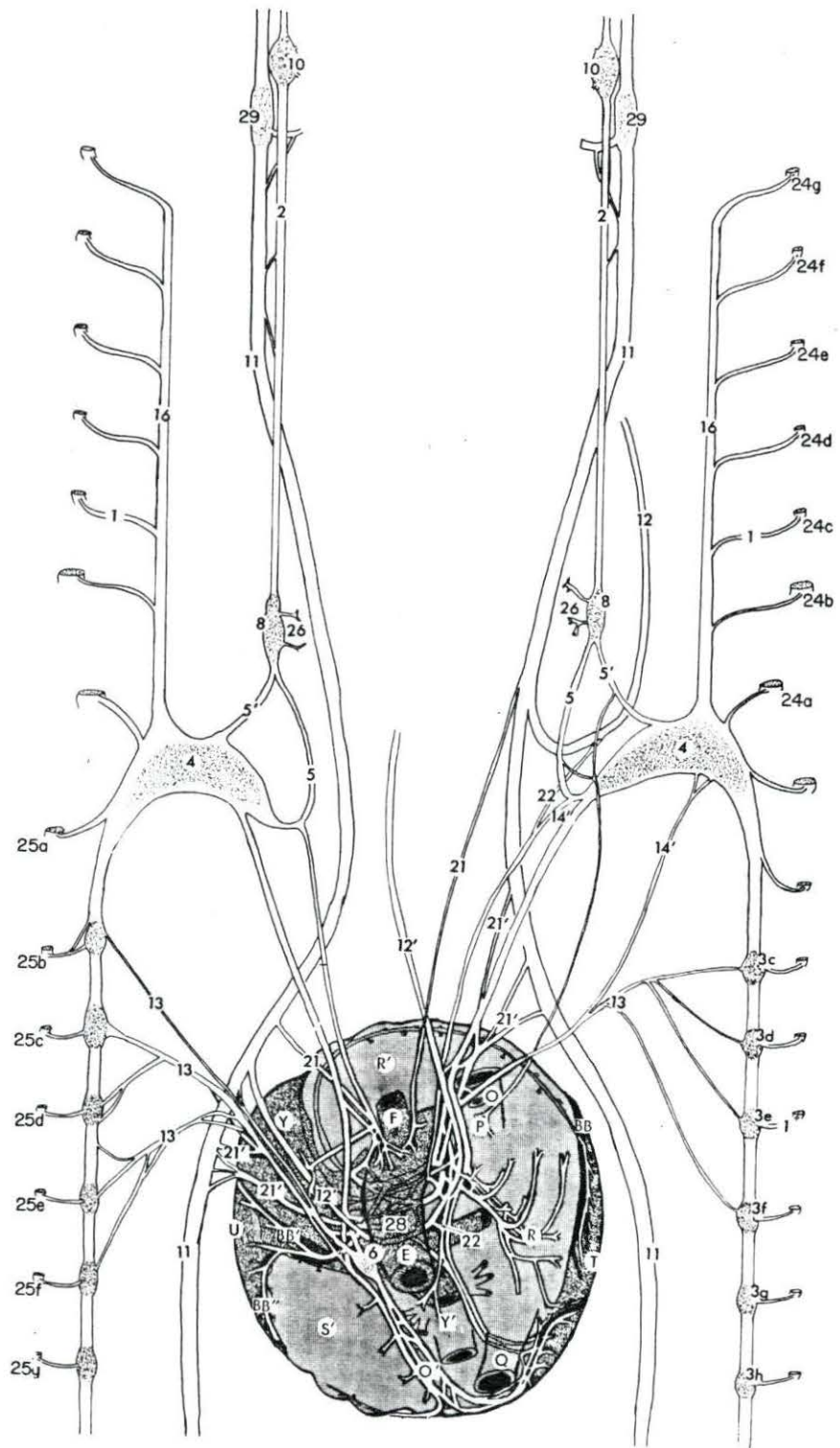


Figure 32. Caprine: Dorsal view of the cardiac innervation. The sympathetic trunks and vagi are reflected laterally.

- | | | | |
|------|--|------|---|
| 1 | Ramus communicans | 25a | First thoracic spinal nerve |
| 2 | Sympathetic trunk | 25b | Second thoracic spinal nerve |
| 3b | Second thoracic ganglion | 25c | Third thoracic spinal nerve |
| 3c | Third thoracic ganglion | 25d | Fourth thoracic spinal nerve |
| 3d | Fourth thoracic ganglion | 25e | Fifth thoracic spinal nerve |
| 3e | Fifth thoracic ganglion | 25f | Sixth thoracic spinal nerve |
| 3f | Sixth thoracic ganglion | 25g | Seventh thoracic spinal nerve |
| 3g | Seventh thoracic ganglion | 25h | Eighth thoracic spinal nerve |
| 3h | Eighth thoracic ganglion | 28 | Cardiac plexes |
| 4 | Cervicothoracic ganglion | 29 | Inferior ganglion of the vagus nerve |
| 5 | Ansa subclavia (caudal limb) | E | Aorta |
| 5' | Ansa subclavia (cranial limb) | F | Brachiocephalic artery |
| 8 | Vertebral ganglion | O | Right vena azygos |
| 9 | Middle cervical ganglion | O' | Left vena azygos (hemiazygos vein) |
| 10 | Cranial cervical ganglion | P | Cranial vena cava |
| 11 | Vagus nerve | Q | Caudal vena cava |
| 12 | Right recurrent laryngeal nerve | R | Right atrium |
| 12' | Left recurrent laryngeal nerve | R' | Right auricle |
| 13 | Thoracic cardiac nerve | S' | Left auricle |
| 14 | Cranial cervicothoracic cardiac nerve | T | Right ventricle |
| 14'' | Ventral caudal cervicothoracic cardiac nerve | U | Left ventricle |
| 16 | Vertebral nerve | Y | Pulmonary artery |
| 18' | Caudal vertebral cardiac nerve | Y' | Pulmonary vein |
| 19 | Middle cervical cardiac nerve | BB | Right coronary artery |
| 21 | Cranial vagal cardiac nerve | BB' | Descending branch of left coronary artery |
| 21' | Caudal vagal cardiac nerve | BB'' | Circumflex branch of left coronary artery |
| 22 | Recurrent cardiac nerve | | |
| 24a | Eighth cervical spinal nerve | | |
| 24b | Seventh cervical spinal nerve | | |
| 24c | Sixth cervical spinal nerve | | |
| 24d | Fifth cervical spinal nerve | | |
| 24e | Fourth cervical spinal nerve | | |
| 24f | Third cervical spinal nerve | | |
| 24g | Second cervical spinal nerve | | |

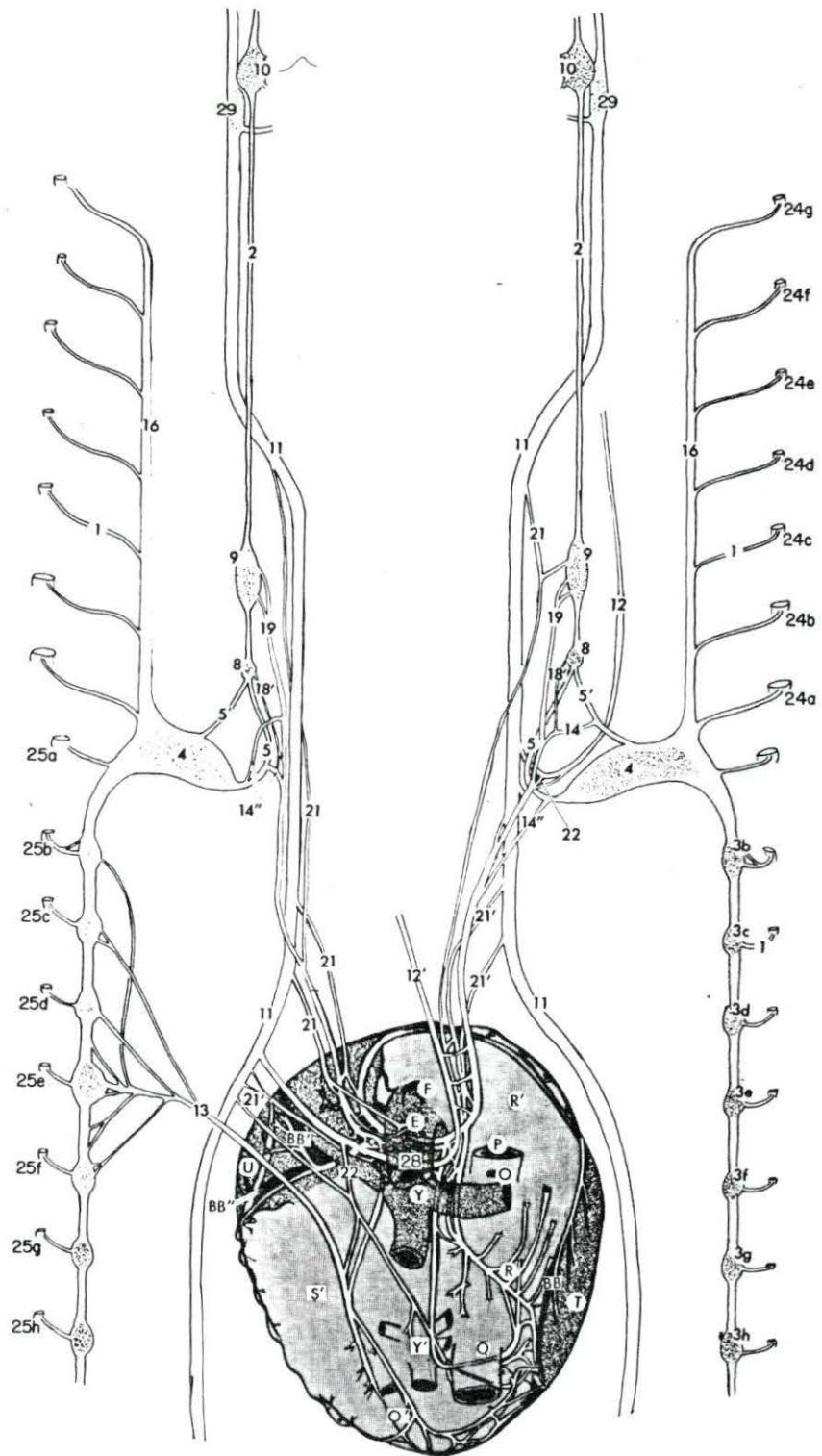


Figure 33. Porcine: Dorsal view of the cardiac innervation. The sympathetic trunks and vagi are reflected laterally.

- | | | | |
|------|---|-----|---|
| 1 | Ramus communicans | 24f | Third cervical spinal nerve |
| 2 | Sympathetic trunk | 24g | Second cervical spinal nerve |
| 3a | First thoracic ganglion | 25a | First thoracic spinal nerve |
| 3b | Second thoracic ganglion | 25b | Second thoracic spinal nerve |
| 3c | Third thoracic ganglion | 25c | Third thoracic spinal nerve |
| 3d | Fourth thoracic ganglion | 25d | Fourth thoracic spinal nerve |
| 3e | Fifth thoracic ganglion | 25e | Fifth thoracic spinal nerve |
| 3f | Sixth thoracic ganglion | 25f | Sixth thoracic spinal nerve |
| 3g | Seventh thoracic ganglion | 25g | Seventh thoracic spinal nerve |
| 3h | Eighth thoracic ganglion | 25h | Eighth thoracic spinal nerve |
| 4 | Cervicothoracic ganglion | 26 | Vascular nerve |
| 5 | Ansa subclavia (caudal limb) | 28 | Cardiac plexus |
| 5' | Ansa subclavia (cranial limb) | 29 | Inferior ganglion of the vagus nerve |
| 6 | Cardiac ganglion of the left intervascular triangle | E | Aorta |
| 7 | Intermediate ganglion | F | Brachiocephalic artery |
| 8 | Vertebral ganglion | G' | Left subclavian artery |
| 9 | Middle cervical ganglion | O' | Left vena azygos (hemiazygos vein) |
| 10 | Cranial cervical ganglion | P | Cranial vena cava |
| 11 | Vagus nerve | Q | Caudal vena cava |
| 12 | Right recurrent laryngeal nerve | R | Right atrium |
| 12' | Left recurrent laryngeal nerve | R' | Right auricle |
| 13 | Thoracic cardiac nerve | S' | Left auricle |
| 14 | Cranial cervicothoracic cardiac nerve | T | Right ventricle |
| 14'' | Ventral caudal cervicothoracic cardiac nerve | U | Left ventricle |
| 16 | Vertebral nerve | Y | Pulmonary artery |
| 17 | Intermediate cardiac nerve | BB | Right coronary artery |
| 18' | Caudal vertebral cardiac nerve | BB' | Descending branch of left coronary artery |
| 19 | Middle cervical cardiac nerve | | |
| 21 | Cranial vagal cardiac nerve | | |
| 21' | Caudal vagal cardiac nerve | | |
| 22 | Recurrent cardiac nerve | | |
| 24a | Eighth cervical spinal nerve | | |
| 24b | Seventh cervical spinal nerve | | |
| 24c | Sixth cervical spinal nerve | | |
| 24d | Fifth cervical spinal nerve | | |
| 24e | Fourth cervical spinal nerve | | |

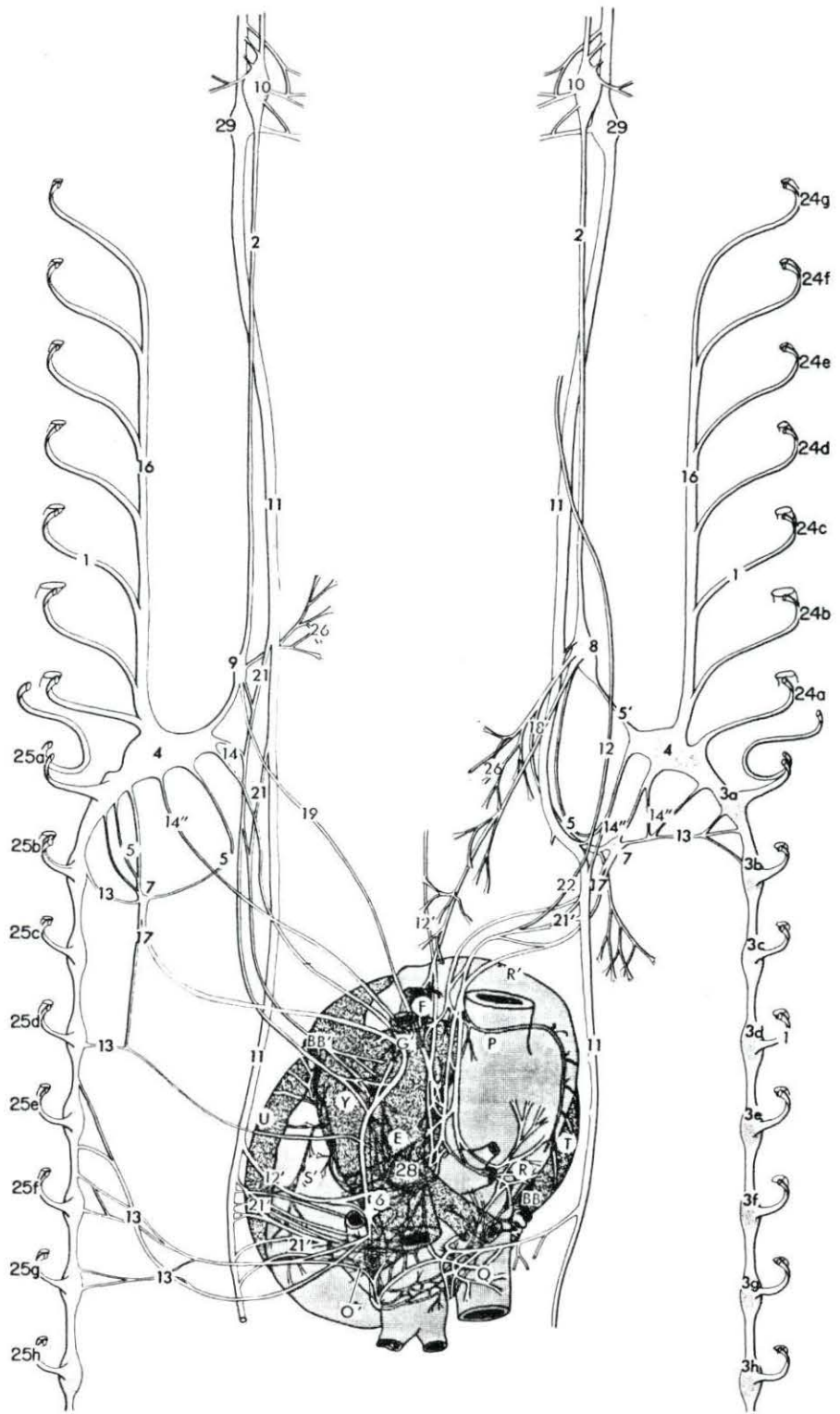


Figure 34. Feline: Dorsal view of the cardiac innervation. The sympathetic trunks and vagi are reflected laterally.

- | | | | |
|------|--|------|---|
| 1 | Ramus communicans | 25d | Fourth thoracic spinal nerve |
| 2 | Sympathetic trunk | 25e | Fifth thoracic spinal nerve |
| 3c | Third thoracic ganglion | 25f | Sixth thoracic spinal nerve |
| 3d | Fourth thoracic ganglion | 25g | Seventh thoracic spinal nerve |
| 3e | Fifth thoracic ganglion | 25h | Eighth thoracic spinal nerve |
| 3f | Sixth thoracic ganglion | 25j | Ninth thoracic spinal nerve |
| 3g | Seventh thoracic ganglion | 28 | Cardiac plexus |
| 3h | Eighth thoracic ganglion | 29 | Inferior ganglion on the vagus nerve |
| 3j | Ninth thoracic ganglion | E | Aorta |
| 4 | Cervicothoracic ganglion | F | Brachiocephalic artery |
| 5 | Ansa subclavia (caudal limb) | G' | Left subclavian artery |
| 5' | Ansa subclavia (cranial limb) | O | Right vena azygos |
| 7 | Intermediate ganglion | P | Cranial vena cava |
| 8 | Vertebral ganglion | Q | Caudal vena cava |
| 10 | Cranial cervical ganglion | R | Right atrium |
| 11 | Vagus nerve | R' | Right auricle |
| 12 | Right recurrent laryngeal nerve | S' | Left auricle |
| 12' | Left recurrent laryngeal nerve | T | Right ventricle |
| 14' | Dorsal caudal cervicothoracic cardiac nerve | U | Left ventricle |
| 14'' | Ventral caudal cervicothoracic cardiac nerve | Y | Pulmonary artery |
| 16 | Vertebral nerve | Y' | Pulmonary vein |
| 18' | Caudal vertebral cardiac nerve | BB | Right coronary |
| 20 | Cranial cervical cardiac nerve | BB' | Descending branch of left coronary artery |
| 21 | Cranial vagal cardiac nerve | BB'' | Circumflex branch of left coronary artery |
| 21' | Caudal vagal cardiac nerve | | |
| 22 | Recurrent cardiac nerve | | |
| 24a | Eighth cervical spinal nerve | | |
| 24b | Seventh cervical spinal nerve | | |
| 24c | Sixth cervical spinal nerve | | |
| 24d | Fifth cervical spinal nerve | | |
| 24e | Fourth cervical spinal nerve | | |
| 24f | Third cervical spinal nerve | | |
| 25a | First thoracic spinal nerve | | |
| 25b | Second thoracic spinal nerve | | |
| 25c | Third thoracic spinal nerve | | |

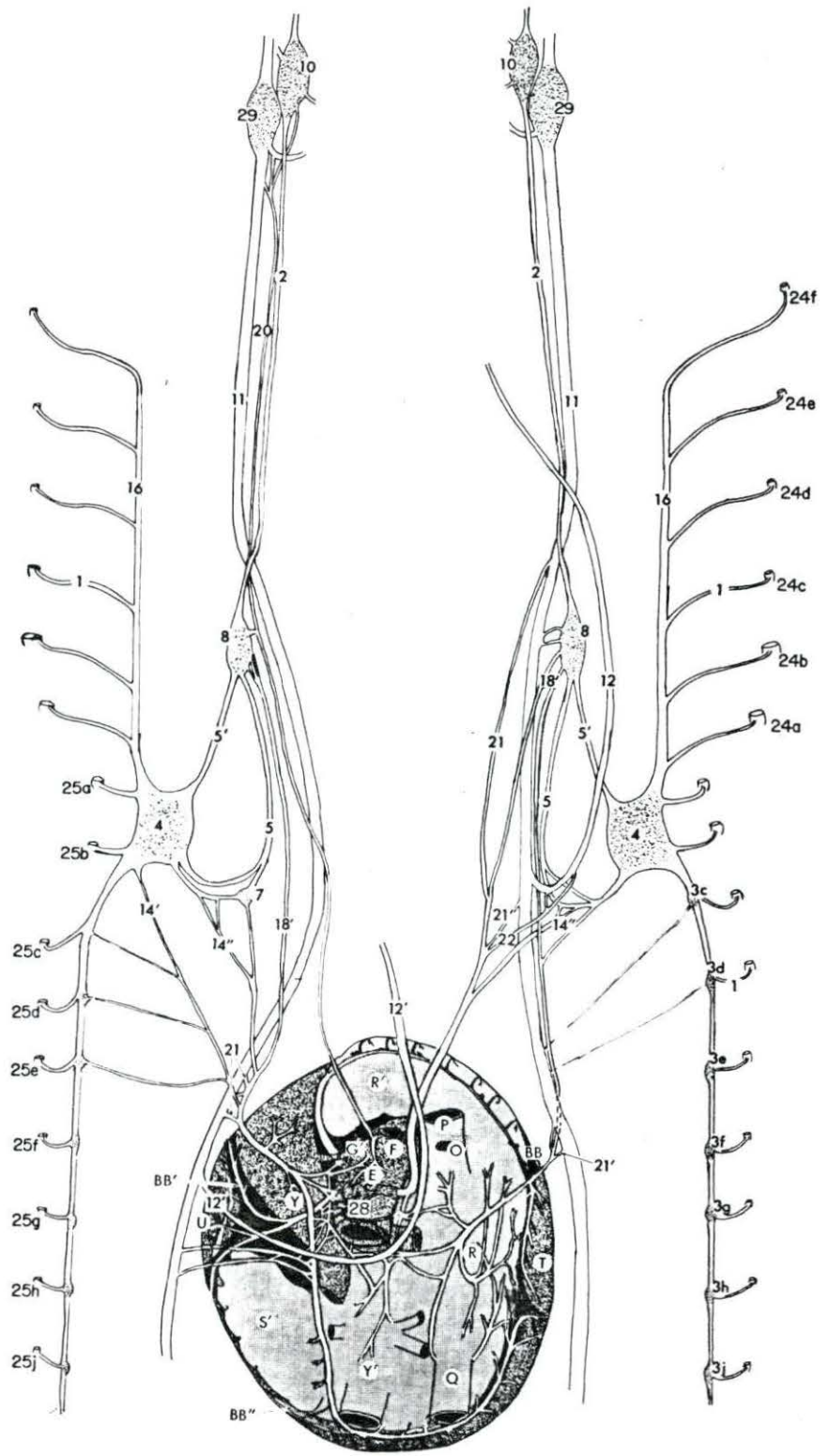


Figure 35. Canine: Dorsal view of the cardiac innervation. The sympathetic trunks and vagi are reflected laterally.

- | | | | |
|--------|--|------|---|
| 1 | Ramus communicans | 24g | Second cervical spinal nerve |
| 2 | Sympathetic trunk | 25a | First thoracic spinal nerve |
| 3d | Fourth thoracic ganglion | 25b | Second thoracic spinal nerve |
| 3e | Fifth thoracic ganglion | 25c | Third thoracic spinal nerve |
| 3f | Sixth thoracic ganglion | 25d | Fourth thoracic spinal nerve |
| 3g | Seventh thoracic ganglion | 25e | Fifth thoracic spinal nerve |
| 3h | Eighth thoracic ganglion | 25f | Sixth thoracic spinal nerve |
| 4 | Cervicothoracic ganglion | 25g | Seventh thoracic spinal nerve |
| 5 | Ansa subclavia (caudal limb) | 25h | Eighth thoracic spinal nerve |
| 5' | Ansa subclavia (cranial limb) | 28 | Cardiac plexus |
| 8 | Vertebral ganglion | 29 | Inferior ganglion of the vagus nerve |
| 10 | Cranial cervical ganglion | E | Aorta |
| 11 | Vagus nerve | F | Brachiocephalic artery |
| 12 | Right recurrent laryngeal nerve | G' | Left subclavian artery |
| 12' | Left recurrent laryngeal nerve | O | Right vena azygos |
| 13 | Thoracic cardiac nerve | P | Cranial vena cava |
| 14 | Cranial cervicothoracic cardiac nerve | Q | Caudal vena cava |
| 14' | Dorsal caudal cervicothoracic cardiac nerve | R | Right atrium |
| 14'' | Ventral caudal cervicothoracic cardiac nerve | R' | Right auricle |
| 16 | Vertebral nerve | S' | Left auricle |
| 18 | Cranial vertebral cardiac nerve | T | Right ventricle |
| 18' | Caudal vertebral cardiac nerve | U | Left ventricle |
| 18'' | Medial caudal vertebral cardiac nerve | Y | Pulmonary artery |
| 18''' | Lateral caudal vertebral cardiac nerve | BB | Right coronary artery |
| 18'''' | Dorsal vertebral cardiac nerve | BB' | Descending branch of left coronary artery |
| 21 | Cranial vagal cardiac nerve | BB'' | Circumflex branch of left coronary artery |
| 21' | Caudal vagal cardiac nerve | | |
| 22 | Recurrent cardiac nerve | | |
| 24a | Eighth cervical spinal nerve | | |
| 24b | Seventh cervical spinal nerve | | |
| 24c | Sixth cervical spinal nerve | | |
| 24d | Fifth cervical spinal nerve | | |
| 24e | Fourth cervical spinal nerve | | |
| 24f | Third cervical spinal nerve | | |

